

Case Report

Low-dose steroid-induced tumor lysis syndrome in a hepatocellular carcinoma patient

Jin Ok Kim, Dae Won Jun, Hye Jin Tae, Kang Nyeong Lee, Hang Lak Lee, Oh Young Lee, Ho Soon Choi, Byung Chul Yoon, and Joon Soo Hahm

Department of Internal Medicine, Hanyang University College of Medicine, Seoul, Korea

Tumor lysis syndrome is rare in hepatocellular carcinoma (HCC), but it has been reported more frequently recently in response to treatments such as transcatheter arterial chemoembolization (TACE), radiofrequency thermal ablation (RFTA), and sorafenib. Tumor lysis syndrome induced by low-dose steroid appears to be very unusual in HCC. We report a patient with hepatitis-C-related liver cirrhosis and HCC in whom tumor lysis syndrome occurred due to low-dose steroid (10 mg of prednisolone). The patient was a 90-year-old male who presented at the emergency room of our hospital with general weakness and poor oral intake. He had started to take prednisolone to treat adrenal insufficiency 2 days previously. Laboratory results revealed hyperuricemia, hyperphosphatemia, and increased creatinine. These abnormalities fulfilled the criteria in the Cairo-Bishop definition of tumor lysis syndrome. Although the patient received adequate hydration, severe metabolic acidosis and acute kidney injury progressed unabated. He finally developed multiple organ failure, and died 3 days after admission. This was a case of tumor lysis syndrome caused by administration of low-dose steroid in a patient with HCC. (*Clin Mol Hepatol* 2015;21:85-88)

Keywords: Tumor lysis syndrome; Hepatocellular carcinoma; Steroid

INTRODUCTION

Tumor lysis syndrome is a potentially lethal oncologic emergency. It can occur in patients with extensive, rapidly growing, and chemosensitive malignancies such as hematologic malignancies.^{1,2} Massive lysis of tumor cells after effective treatment results in the release of intracellular substances into the bloodstream.³⁻⁵ Because large amounts of intracellular substances such as potassium, phosphate, and uric acid, etc. are released, the severe alteration of these metabolic profiles can have clinically toxic effects, including acute kidney injury, cardiac arrhythmias, seizures, and multiorgan failure that can finally result in death.⁶

Although it most often happens in hematologic malignancies such as acute lymphocytic leukemia and Burkitt's lymphoma, tumor lysis syndrome has also been reported in various solid tumors, including lung and breast carcinomas.^{5,7-9} The syndrome is rare in hepatocellular carcinoma (HCC); about 8% of the cases of tumor lysis syndrome in solid tumors occur in HCC.^{5,10} Recently it has been increasingly reported after treatments such as transcatheter arterial chemoembolization (TACE), radiofrequency ablation, and sorafenib, etc.^{5,11-14} In HCC, tumor lysis syndrome induced by low dose steroid appears to be very unusual.

Here, we report a case of tumor lysis syndrome occurring after administration of low dose steroid in a patient with HCC.

Abbreviations:

AST, aspartate transaminase; ALT, alanine transaminase; AFP, α -fetoprotein; eGFR, estimated glomerular filtration rate; HCC, hepatocellular carcinoma; RFTA, radiofrequency thermal ablation; TACE, transcatheter arterial chemoembolization

Corresponding author : Dae Won Jun

Department of Internal Medicine, Hanyang University College of Medicine, 222 Wangsimni-ro, Seongdong-gu, Seoul 133-791, Korea
Tel: 82-2-2290-8338, Fax: 82-2-2298-9183
E-mail: noshin@hanyang.ac.kr

Received : May 13, 2013 / Revised : Jul. 23, 2013 / Accepted : Jul. 25, 2013

CASE REPORT

A 90-year-old male who presented with symptoms of general weakness and poor oral intake visited the emergency department of our hospital. He was diagnosed with hepatitis C-related liver cirrhosis and hepatocellular carcinoma (HCC) in our hospital. Abdominal computed tomography had been performed about one month previously and had revealed multiple viable HCCs in both lobes of the liver. Their largest diameter was 10.7 cm (Fig. 1). The patient's HCC was classified as stage B according to the Barcelona Clinic Cancer staging classification. He had undergone radio frequency thermal ablation (RFTA) once and TACE six times in our hospital. Two days ago he visited our outpatient clinic with symptoms such as general weakness, nausea, and vomiting. Because the symptoms had suggested adrenal insufficiency, he had been empirically administered prednisolone 10mg per day by the oral route for two days. ACTH stimulation test couldn't be performed at our outpatient clinic and the patient refused the test. Else he had been taking furosemide 20 mg, aldactone 50 mg a day. Before taking prednisolone, serum creatinine was 1.12 mg/dL, estimated glomerular filtration rate (eGFR) was 65 mL/min/1.73 m², and his renal function had been well preserved considering his age.

The patient's vital signs were within normal limits at our emergency department. On physical examination, the abdomen was distended, without tenderness or rebound tenderness. A complete blood cell count showed mild leukocytosis with mild anemia: leu-

kocytes, 14.4 X 10³/μL; hemoglobin, 10.8 g/dL; and platelets, 180 X 10³/μL. The following additional laboratory values were found: serum sodium, 145 mEq/L; potassium, 5.4 mEq/L; chloride 110 mEq/L; bicarbonate 24.0 mEq/L; total protein, 7.1 g/dL; albumin, 3.0 g/dL calcium, 8.7 mg/dL; inorganic phosphorus, 5.8 mg/dL. In addition, serum urea nitrogen level was 100.5 mg/dL, creatinine level was 3.00 mg/dL, eGFR was 21 mL/min/1.73 m². AST was 310 U/L, ALT was 171 U/L, total bilirubin was 5.24 mg/dl, prothrombin time was 12.5 sec, α-fetoprotein (AFP) was 647.4 ng/mL. His Child-Turcotte-Pugh score was 9. Chest radiography revealed only an old tuberculosis lesion in the right upper lung zone. His electrocardiogram was normal. Because he had acute kidney damage, and adequate hydration could not correct it, hepatorenal syndrome was suspected. He was treated by intravenous hydration at first, and was also administered terlipressin and albumin.

Though serum uric acid was 8.0 mg/dL about 6 months ago, the following day, serum uric acid increased to 18.3 mg/dL. Serum sodium was 146 mEq/L, potassium was 5.4 mEq/L, inorganic phosphorus was 6.2 mg/dL, calcium was 8.7 mg/dL, serum urea nitrogen level was 104.6 mg/dL, creatinine level was 2.90 mg/dL, and eGFR was 22 mL/min/1.73 m². Though oliguria was not present, his urine output was lower than a day earlier. Hydration and treatment for hepatorenal syndrome were maintained.

In next day, he had severe metabolic acidosis and acute kidney injury. Multiple organ failure progressed steadily, and he expired three days after admission.

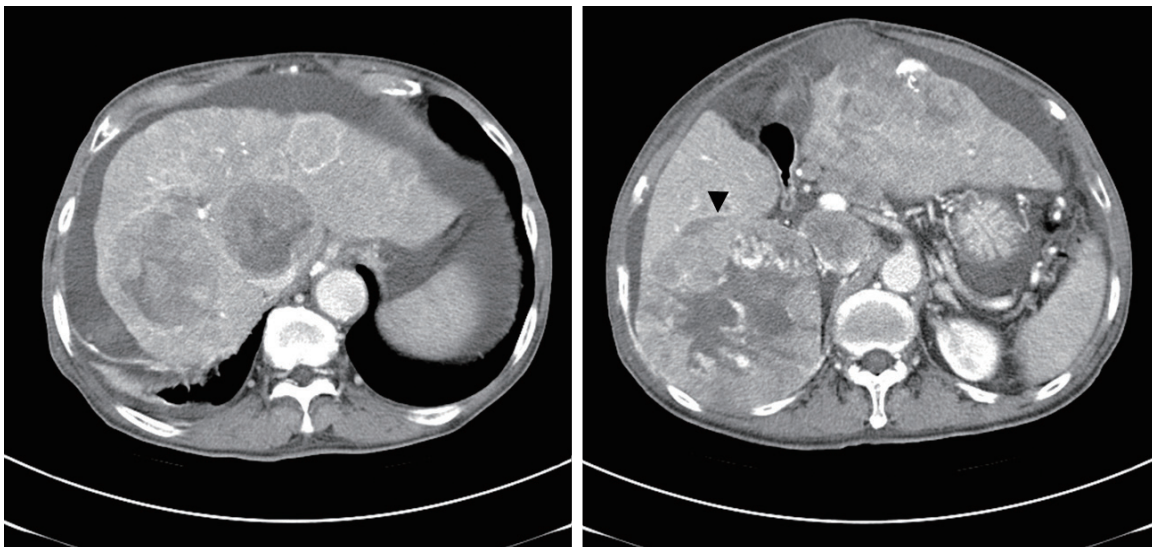


Figure 1. Abdominal computed tomography with enhancement performed about 1 month prior to this admission revealed multiple viable HCCs in both lobes of the liver. The largest of these tumors had a diameter of 10.7 cm (arrow head).

DISCUSSION

Although, tumor lysis syndrome is most commonly observed in chemosensitive malignancy, such as acute lymphocytic leukemia and Burkitt's lymphoma, it is rare in solid tumors.^{5,7} However recently it has been reported in various solid tumors, including lung and breast carcinomas.^{5,8,9} The most important risk factor for tumor lysis syndrome is tumor burden, which can easily result in autonecrosis and the release of intracellular substances. Other important risk factors are dehydration and preexisting renal insufficiency.¹⁵

Tumor lysis syndrome is still very rare in the treatment of HCC, and HCC contributes only about 8% of the cases of tumor lysis syndrome in solid tumors.¹⁰ Recently it has been increasingly reported after treatments such as transcatheter arterial chemoembolization (TACE), radiofrequency ablation and sorafenib, etc.^{5,11-14,16} Since Burney et al first observed the syndrome after TACE in two patients with HCC,¹⁷ occasional cases have been reported after TACE. Because sorafenib is now widely used in the treatment of advanced HCC, three cases of tumor lysis syndrome caused by treatment of HCC with sorafenib were recently reported.¹²⁻¹⁴ Cases have also been reported after treatments of HCC such as radiofrequency ablation, thalidomide, etc.^{11,18} As far as we know, low dose steroid-induced tumor lysis syndrome has not been previously reported.

The Cairo and Bishop definition of tumor lysis syndrome was proposed in 2004.⁴ It can be classified as a clinical and laboratory tumor lysis syndrome (Table 1).⁴ In the present case, the degree of abnormalities in his uric acid and phosphate fulfill the criteria of

tumor lysis syndrome as defined by Cairo-Bishop. The criteria of clinical tumor lysis syndrome were also satisfied by his creatinine level. Because in the present case tumor lysis syndrome was misdiagnosed as hepatorenal syndrome, appropriate treatments such as hemodialysis and allopurinol were not performed, and only intravenous hydration was administered. The patient unfortunately expired three days after admission.

Steroid induced tumor lysis syndrome occurs mainly in hematologic malignancies such as leukemia and lymphoma, and is rare in patients with solid tumors.

Steroids are known to have lympholytic effects and are therefore widely used as components of combination chemotherapy protocols for hematologic malignancies. They act by inducing growth arrest and apoptosis. Although steroids are widely used, there are only a few case reports of tumor lysis syndrome in patients with malignancies treated solely with steroids.^{19,20} Therefore, empirical therapy with steroids should be avoided, especially in patients suspected of having large tumor burdens.¹⁹

The prognosis of tumor lysis syndrome caused in solid tumors is poor, with a high mortality rate. Prevention of the syndrome by treatments such as sufficient hydration, urine alkalization, and correction of metabolic disturbance, can be effective in patients with large solid tumor burdens or renal insufficiency.^{3,4,16} When steroid is administered to patients with large HCC or who are dehydrated, proper hydration before administering steroid is vital to prevent tumor lysis syndrome.

In conclusion, the development of treatments for HCC has increased the likelihood of tumor lysis syndrome. Low dose steroid

Table 1. Cairo-Bishop definition of laboratory and clinical tumor lysis syndrome⁴

Laboratory tumor lysis syndrome	Clinical tumor lysis syndrome
≥2 of the following metabolic abnormalities occurring simultaneously within 3 days prior to and up to 7 days post-treatment initiation	Laboratory-defined TLS accompanied by any of the following
Uric acid ≥ 8.0 mg/dL (476 μmol/L) or 25% increase from baseline	Elevated creatinine level (≥1.5 ULN for patients >12 years of age or age-adjusted)
Phosphorous ≥ 4.5 mEq/L (1.45 mmol/L) (adults) ≥ 6.5 mEq/L (2.1 mmol/L) (children) or 25% increase from baseline	Seizures
Potassium ≥ 6.0 mEq/L (6.0 mmol/L) or 25% increase from baseline	Cardiac dysrhythmia
Calcium ≤ 7.0 mg/dL (1.75 mmol/L) or 25% decrease from baseline	Sudden death

TLS, tumor lysis syndrome; ULN, upper limit of normal.

can also cause the syndrome in patients with HCC. When administering steroid to HCC patients with large tumor burdens, or who are dehydrated, great care should be taken.

Conflicts of Interest

The authors have no conflicts to disclose.

REFERENCES

1. Yarpuzlu AA. A review of clinical and laboratory findings and treatment of tumor lysis syndrome. *Clin Chim Acta* 2003;333:13-18.
2. Darmon M, Roumier M, Azoulay E. Acute tumor lysis syndrome: diagnosis and management. *Yearbook of Intensive Care and Emergency Medicine* 2009;819-827.
3. Davidson MB, Thakkar S, Hix JK, Bhandarkar ND, Wong A, Schreiber MJ. Pathophysiology, clinical consequences, and treatment of tumor lysis syndrome. *AM J Med* 2004;116:546-554.
4. Cairo MS, Bishop M. Tumour lysis syndrome: new therapeutic strategies and classification. *Br J Haematol* 2004;127:3-11.
5. Hsieh PM, Hung KC, Chen YS. Tumor lysis syndrome after transarterial chemoembolization of hepatocellular carcinoma: case reports and literature review. *World J Gastroenterol* 2009;15:4726-4728.
6. Howard SC, Jones DP, Pui CH. The tumor lysis syndrome. *N Engl J Med* 2011;364:1844-1854.
7. Cohen LF, Balow JE, Magrath IT, Poplack DG, Ziegler JL. Acute tumor lysis syndrome: a review of 37 patients with Burkitt's lymphoma. *Am J Med* 1980;68:486-491.
8. Kalemkerian GP, Darwish B, Varterasian ML. Tumor lysis syndrome in small cell carcinoma and other solid tumors. *Am J Med* 1997;103:363-367.
9. Rostom AY, El-Hussainy G, Kandil A, Allam A. Tumor lysis syndrome following hemi-body irradiation for metastatic breast cancer. *Ann Oncol* 2000;11:1349-1351.
10. Firwana BM, Hasan R, Hasan N, Alahdab F, Alnahhas I, Hasan S, et al. Tumor lysis syndrome: a systematic review of case series and case reports. *Postgrad Med* 2002;124:92-101.
11. Lehner SG, Gould JE, Saad WE, Brown DB. Tumor lysis syndrome after radiofrequency ablation of hepatocellular carcinoma. *AJR Am J Roentgenol* 2005;185:1307-1309.
12. Shiozawa K, Watanabe M, Takenaka H, Nagai H, Ishii K, Sakai K, et al. Tumor lysis syndrome after sorafenib for hepatocellular carcinoma: a case report. *Hepatogastroenterology* 2010;57:688-690.
13. Joshita S, Yoshizawa K, Sano K, Kobayashi S, Sekiguchi T, Morita S, et al. A patient with advanced hepatocellular carcinoma treated with sorafenib tosylate showed massive tumor lysis with avoidance of tumor lysis syndrome. *Intern Med* 2010;49:991-994.
14. Huang WS, Yang CH. Sorafenib induced tumor lysis syndrome in an advanced hepatocellular carcinoma patient. *World J Gastroenterol* 2009;15:4464-4466.
15. Saini N, Pyo Lee K, Jha S, Patel S, Bonthu N, Kansagra A, et al. Hyperuricemic Renal Failure in Nonhematologic Solid Tumors: A Case Report and Review of the Literature. *Case Rep Med* 2012;e314056.
16. Huang WS, Yang CH. Sorafenib induced tumor lysis syndrome in an advanced hepatocellular carcinoma patient. *World J Gastroenterol* 2009;15:4464-4466.
17. Burney IA. Acute tumor lysis syndrome after transcatheter chemoembolization of hepatocellular carcinoma. *South Med J* 1998;91:467-470.
18. Lee CC, Wu YH, Chung SH, Chen WJ. Acute tumor lysis syndrome after thalidomide therapy in advanced hepatocellular carcinoma. *Oncologist* 2006;11:87-88.
19. Chanimov M, Koren-Michowitz M, Cohen ML, Pilipodi S, Bahar M. Tumor lysis syndrome induced by dexamethasone. *Anesthesiology* 2006;105:633-634.
20. Lerza R, Botta M, Barsotti B, Schenone E, Mencoboni M, Bogliolo G, et al. Dexamethazone-induced acute tumor lysis syndrome in a T-cell malignant lymphoma. *Leuk Lymphoma* 2002;43:1129-1132.