

The Journal of Laryngology & Otology

<http://journals.cambridge.org/JLO>

Additional services for *The Journal of Laryngology & Otology*:

Email alerts: [Click here](#)

Subscriptions: [Click here](#)

Commercial reprints: [Click here](#)

Terms of use : [Click here](#)



Parotid haemangiomas in childhood: a case for MRI

Philippa Huchzermeyer, M. A. Birchall, B. Kendall and C. M. Bailey

The Journal of Laryngology & Otology / Volume 108 / Issue 10 / October 1994, pp 892 - 895
DOI: 10.1017/S0022215100128439, Published online: 29 June 2007

Link to this article: http://journals.cambridge.org/abstract_S0022215100128439

How to cite this article:

Philippa Huchzermeyer, M. A. Birchall, B. Kendall and C. M. Bailey (1994). Parotid haemangiomas in childhood: a case for MRI. The Journal of Laryngology & Otology, 108, pp 892-895 doi:10.1017/S0022215100128439

Request Permissions : [Click here](#)

Radiology in Focus

Parotid haemangiomas in childhood: a case for MRI

PHILIPPA HUCHZERMEYER, M.A. BIRCHALL, B. KENDALL*, C. M. BAILEY

Abstract

Seven infants with unilateral parotid haemangiomas seen at one centre are presented. Their case notes and special investigations are reviewed. Magnetic resonance imaging (MRI) is revealed as the investigation of choice because of picture quality, definition of soft tissues and lack of exposure to ionizing radiation. MRI allows a definite diagnosis to be made without any invasive procedure being required. A future study following up these infants may be of interest because of controversy regarding the spontaneous resolution of these lesions.

Key words: Parotid neoplasms; Haemangioma; Magnetic resonance imaging

Introduction

Although noninfective parotid swellings are uncommon, parotid haemangiomas account for perhaps 20 per cent of all parotid tumours and 50 per cent of those presenting in the first year of life. We present a series of seven patients with this condition seen at one centre over a two-year period. Diagnosis is made on a combination of clinical and radiological findings and these are discussed. In many cases the lesions undergo spontaneous involution. It is therefore particularly important that they are accurately diagnosed and that no unnecessary or potentially harmful diagnostic or therapeutic procedures are carried out. The aim of this study was to examine how best to establish a diagnosis.

Methods

The case notes of seven patients with parotid haemangiomas presenting to the Otolaryngology Department, The Hospital for Sick Children, Great Ormond Street, in the period April 1991 to April 1993 were reviewed retrospectively. All radiological investigations including ultrasound, computerized tomographical scans (CT) and magnetic resonance imaging (MRI) were critically reassessed and compared. Ultrasound scans (US) were performed on awake patients while CT scans and MRI were performed under sedation as day cases.

Results

The patient data is summarized in Table I.

Patterns of presentation

Six female infants and one male infant presented, at under 15 months of age, with a unilateral, soft swelling over the angle of the jaw that was gradually increasing in size (Figure 1). The swellings were all noticed before the age of six months but none were present at birth. Three of the seven infants had cutaneous

haemangiomas at the other sites (forehead, neck, groin, chin, shoulder). There were no serious illnesses or congenital abnormalities present.

Clinical findings

Clinically the haemangiomas manifest as nontender, unilateral, soft swellings over the angle of the jaw. The swelling fills and becomes tense on crying. Two of the seven patients had a bluish discolouration of the skin overlying the haemangioma. There were no cardiovascular disturbances and no bruits heard over the lesions.

The period of follow-up varied between 0 and two years. The two infants followed up for two years showed a decrease in haemangioma size on sequential clinical assessment by the same surgeon.

Ultrasound investigation

Ultrasound of the parotid swellings revealed a lobulated swelling in the parotid region and in some showed pulsation or a pulsating enlarged feeding vessel. However usually no firm diagnosis could be made at the time of investigation.

CT scan investigation

Three patients were investigated by CT scan. This showed the lesion as a circumscribed mass in the parotid which enhanced with intravenous contrast. A representative view is shown in Figure 2.

MRI investigation

Six patients were investigated by MRI. Analysis of these MRIs showed several common features. All the lesions were dark on T₁-weighted images, with a signal intensity similar to that of grey matter and a lower signal intensity than normal par-

From the Departments of Paediatric Otolaryngology and Radiology*, The Hospital for Sick Children, Great Ormond Street, London WC1N 3JH.

Presented at the 1993 meeting of the British Association of Paediatric Otolaryngology on 11 June, 1994.

Accepted for publication: 15 January 1994.

TABLE I
SUMMARY OF CLINICAL FINDINGS AND INVESTIGATIONS

Case no.	Age at onset	Age at presentation	Sex	Description	Investigation	Follow-up
1	5 weeks	2 months	F	Left parotid swelling and cutaneous haemangioma on chin	CT: circumscribed enhancing mass in left parotid	No change over 14 months
2	3 months	9 months	F	Right parotid swelling about 2 cm in diameter	US: mass supplied by large vessel. MRI: lobulated mass with low signal regions (vessels)	No change in 2 months
3	2 months	5 months	F	Right parotid swelling and cutaneous haemangioma of forehead, neck and groin	US: lobulated mass, diagnosis impossible. MRI: lobulated mass with normal parotid tissue compressed, several regions of signal void (vessels)	Reducing in size over 15 months
4	2 months	3 months	M	Right parotid swelling about 3 × 4 cm in size	US: pulsatile mass. MRI: large parotid haemangioma extending around great vessels and into parapharyngeal region	Reducing in size over 18 months
5	3 weeks	3 months	F	Right parotid swelling ill-defined, extending into neck	US: mass of vascular origin. MRI: large haemangioma of parotid fed by hypertrophied facial artery	Follow-up at local hospital, 'fluctuates in size'
6	2 months	14 months	F	Right parotid swelling, 5 cm in diameter with blue colour on crying and cutaneous haemangioma of left shoulder	US: vascular lesion. MRI: lobulated mass with signal voids	No follow-up data yet
7	5 months	10 months	F	Right parotid swelling with central red-blue discolouration	MRI: lobulated lesion with signal void areas	No follow-up data yet.

otid (Figure 3). On T₂-weighted images the haemangioma appeared bright, with a high signal intensity similar to cerebrospinal fluid (Figure 4). The shape of the haemangioma was lobulated in appearance and within the lesions were regions of low signal consistent with flow voids representing blood vessels. Some views showed septae of high signal on both T₁ and T₂-weighted sequences.

Discussion

Salivary gland tumours are rare in children and the frequency of the various histological types found differs from that of adult patients. Working out incidences from the reported literature

brings with it the problem that infective and other benign lesions are under reported as they do not present to a surgeon or pathologist. Some authors estimate that parotid haemangiomas account for 50 per cent of parotid tumours presenting in the first year of life (Garfinkle and Handler, 1990).

A differential diagnosis has to consider infective lesions, hamartomas and neoplasms. The diagnosis of an infective lesion is usually easily made with typical features being pain and systemic upset. Suspicion of a hamartoma or tumour makes further investigation mandatory. The hamartomas include haemangioma, lymphangioma (cystic hygroma) and neurofibroma.

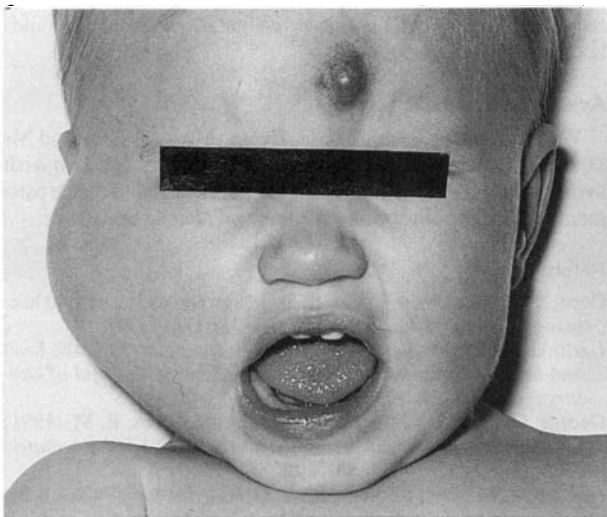


FIG. 1

Right parotid haemangioma and associated cutaneous haemangioma in a 10-month-old infant girl.

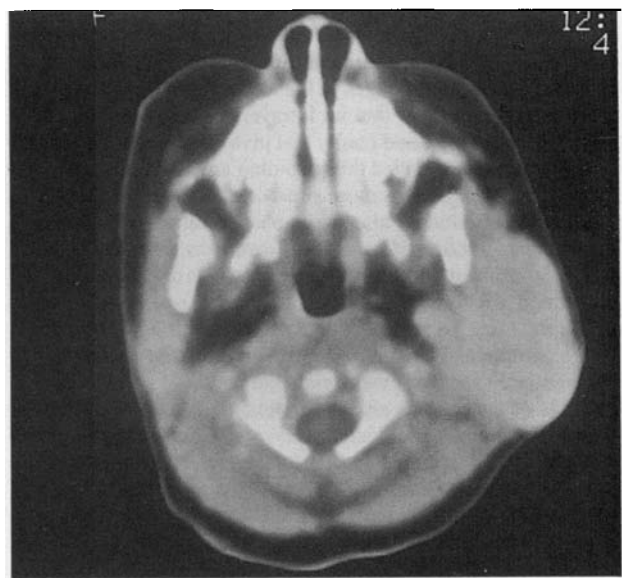


FIG. 2

CT scan showing an enhanced mass in the left parotid representing a haemangioma.

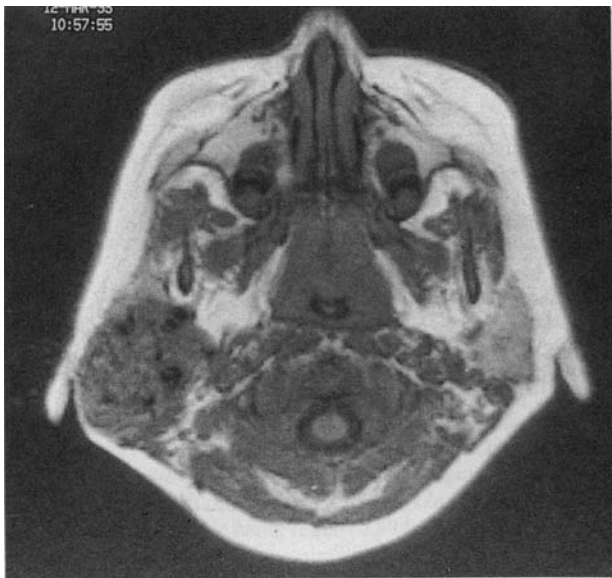

FIG. 3

MRI scan, T₁-weighted image, showing a right parotid haemangioma with an image intensity similar to that of grey matter.

Clinically both haemangioma and lymphangioma may present as unilateral, soft and possibly fluctuant swellings. On investigation with MRI the most important differentiating feature between lymphangiomas and haemangiomas is that signal voids representing blood vessels are absent in lymphangiomas. In addition lymphangiomas of the parotid are rare as they most commonly arise from the posterior triangle of the neck and may secondarily involve the salivary glands (Stenson *et al.*, 1991).

The MRI appearance of childhood parotid haemangiomas is characteristic showing a dark lesion on T₁- and a bright lesion on T₂-weighted images. In addition the lesions appear lobulated with areas of signal void which represent blood vessels. We propose that the investigation of choice for diagnosing parotid haemangiomas in childhood is MRI. In a review of the literature we have been able to find only one reference to MRI in the investigation of infantile parotid haemangiomas. This was by George *et al.* (1991) who reported three cases investigated by MRI and concluded that the MRI appearance was sufficiently characteristic to provide a diagnosis. The advantages of MRI are as follows: firstly, the excellent picture quality and definition of tissue planes; secondly, that exposure to ionizing radiation is avoided; thirdly, that images in the axial and the coronal planes are available; fourthly, that no intravenous contrast medium is required for the MRI and finally that invasive procedures including biopsy can be avoided thus avoiding any risk of injury to the facial nerve which has a more superficial course in infancy.

The patients studied also had a parotid ultrasound scan performed and although this showed the mass as vascular it neither showed the extent of the lesion nor gave a firm diagnosis. We feel that where MRI is available ultrasound is not required. However in an infant first presenting with a parotid swelling ultrasound is a safe, simple and readily available investigative tool that will differentiate vascular, cystic and solid lesions.

Three of the patients also underwent a CT scan. This showed the haemangiomas as enhancing lesions in the parotid. A disadvantage of CT scanning is that it involves ionizing radiation. Some adult and adolescent cavernous parotid haemangiomas contain phleboliths which give a characteristic appearance on X-ray and CT, but these are not found in infantile haemangiomas (Nussbaum *et al.*, 1976).

Since the 1960s it has been recognized that many infantile haemangiomas undergo spontaneous involution and suggested management is therefore careful observation with surgery required only if there is rapid growth, facial palsy, platelet trap-

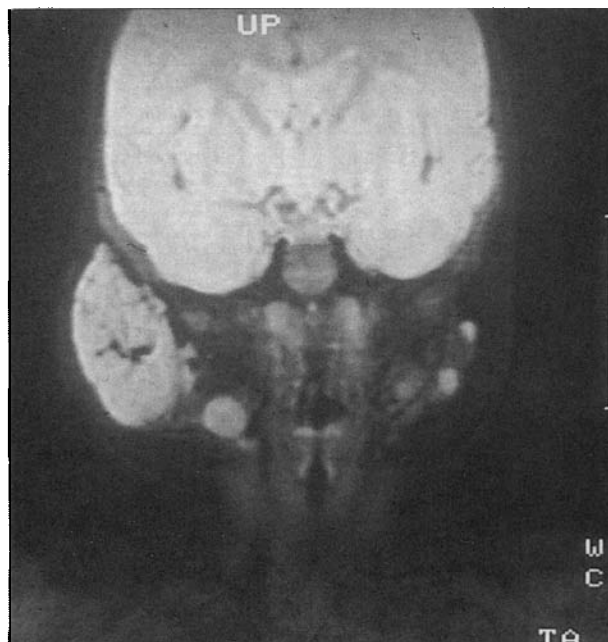


FIG. 4

MRI scan, T₂-weighted image, showing a haemangioma of the right parotid as a bright image similar in intensity to CSF.

ping or haemodynamic disturbance (Cope and Blanchard, 1965; Smith *et al.*, 1985; Weber *et al.*, 1990). In the group of patients studied a firm diagnosis was established by MRI and to date any invasive procedures have been avoided, except for a Tru-cut biopsy performed on one patient prior to referral.

Data regarding the natural history of parotid haemangiomas is scarce. We therefore propose to follow the progress of this cohort to elucidate this further.

Conclusions

Parotid haemangiomas are considered to be congenital tumours arising from an abnormality in the development of the intralobular vascular system of the parotid. They account for 50 per cent of parotid tumours presenting in the first year of life. They have a tendency to undergo spontaneous resolution in most cases by the age of five years and management is thus expectant. An accurate diagnosis can be made by MRI with the least risk of adverse side-effects as it is nonionizing and noninvasive. We therefore propose MRI as the investigation of choice in childhood parotid haemangiomas.

Acknowledgements

We wish to thank Mr J. N. G. Evans, Mr R. F. Gray and Mr D. M. Albert for permission to report their cases. We also wish to thank the staff of the Radiology Department and of the Department of Medical Illustration for their invaluable assistance.

References

- Cope, D. A., Blanchard, C. L. (1965) Benign congenital parotid haemangiomas in infants. *Laryngoscope* **75**: 1741–1748.
- Garfinkle, T. J., Handler, S. D. (1990) Haemangiomas of the head and neck in children – a guide to management. *Journal of Otolaryngology* **9** (5): 439–450.
- George, C. D., Ng, Y. Y., Hall-Craggs, M. A., Jones, B. M. (1991) Parotid haemangioma in infants: MR imaging at 1.5 T. *Paediatric Radiology* **21** (7): 483–485.
- Nussbaum, M., Tan, S., Som, M. L. (1976) Haemangiomas of the salivary glands. *Laryngoscope* **86**: 1015–1019.
- Smith, R. J. H., Wright, G. H., Katz, C. D., Atkins, J. H. (1985) Benign parotid diseases of childhood. *Laryngoscope* **95**: 915–920.
- Stenson, K. M., Mishell, J., Toriumi, D. M. (1991) Imaging case

study of the month. Cystic hygroma of the parotid gland. *Annals of Otolaryngology and Laryngology* **100**: 518-520.
Weber, T. R., Connors, R. H., Tracy, T. F., Bailey, P. V. (1990) Complex haemangiomas of infants and children. *Archives of Surgery* **125** (8): 1017-1020.

Address for correspondence:
Miss P. M. Huchzermeyer,
5 Cheriton Avenue,
Twyford,
Berkshire RG10 9DB.