



Endobronchial dental prosthesis retrieval by a snare technique using a flexible bronchoscope and fluoroscopy: Two case reports and technical tips

著者	Ichimura Hideo, Maeda Michihiro, Kikuchi Shinji, Ozawa Yuichiro, Kanemoto Koji, Kurishima Koichi, Iijima Hiroaki, Ishikawa Hiroichi, Sato Yukio
journal or publication title	Respiratory Medicine Case Reports
volume	19
page range	187-189
year	2016
権利	(C) 2016 The Authors. Published by Elsevier Ltd. This is an open access article under the CC BY-NC-ND license (http://creativecommons.org/licenses/by-nc-nd/4.0/).
URL	http://hdl.handle.net/2241/00146290

doi: 10.1016/j.rmcr.2016.10.013





Endobronchial dental prosthesis retrieval by a snare technique using a flexible bronchoscope and fluoroscopy: Two case reports and technical tips



Hideo Ichimura ^{a, b, *}, Michihiro Maeda ^c, Shinji Kikuchi ^{a, c}, Yuichiro Ozawa ^c, Koji Kanemoto ^d, Koichi Kurishima ^d, Hiroaki Iijima ^d, Hiroichi Ishikawa ^d, Yukio Sato ^a

^a Department of Thoracic Surgery, Faculty of Medicine, University of Tsukuba, Tsukuba, Japan

^b Department of Thoracic Surgery, Hitachi General Hospital, Hitachi, Japan

^c Department of Thoracic Surgery, Tsukuba Medical Center Hospital, Tsukuba, Japan

^d Department of Respiratory Medicine, Tsukuba Medical Center Hospital, Tsukuba, Japan

ARTICLE INFO

Article history:

Received 10 September 2016

Received in revised form

13 October 2016

Accepted 17 October 2016

Keywords:

Dental prosthesis

Endobronchial foreign body

Flexible bronchoscope

Fluoroscopy

Snare technique

ABSTRACT

We describe two cases in each of which a dental prosthesis, presenting as an endobronchial foreign body (FB), was successfully retrieved using a snare technique employing a flexible bronchoscope and fluoroscopy that enabled us to avoid the need for rigid bronchoscope and thoracotomy. In one case, the FB was peripherally lodged and bronchoscopically invisible. In the other case, the FB was observed in the right intermediate bronchus, but the grasping basket and forceps were unable to retrieve it. The combination of a flexible bronchoscope and fluoroscopy extended the application of the snare technique to bronchoscopically invisible FBs and facilitated placement of an encircling loop around the FB. Since dental prostheses are rigid and irregular in shape, the snare loop technique can be used. For patients in a stable condition with a dental prosthesis FB, using the snare technique with a flexible bronchoscope and fluoroscopy is a good option. We provide technical tips based on our experiences.

© 2016 The Authors. Published by Elsevier Ltd. This is an open access article under the CC BY-NC-ND license (<http://creativecommons.org/licenses/by-nc-nd/4.0/>).

1. Introduction

An endobronchial foreign body (FB) is rare among adults in a clinical setting, and the treatment options available comprise a flexible/rigid bronchoscope and thoracotomy. Although flexible bronchoscope has the advantage of avoiding general anesthesia, there is a paucity of patients with FB, which prevents a bronchoscopist from accumulating adequate experience with therapeutic maneuvers [1–3]. Additionally, since many types of bronchoscopic devices are available for FB retrieval, a bronchoscopist encountering such a case will face uncertainty about the choice of device. We describe two cases in which endobronchial dental prostheses presented as FBs, and were retrieved with the snare technique using a flexible bronchoscope under fluoroscopic guidance.

2. Case presentation

2.1. Case 1

A 73-year-old woman was referred to our hospital for an endobronchial FB. She had undergone dental treatment 3 weeks previously. Thereafter, she had complained of a cough and visited a physician. A chest radiograph showed a small radiopaque object (Fig. 1A). We diagnosed her as having an FB based on the clinical history and radiologic findings. Since her general condition was stable, we attempted to retrieve it by using a flexible bronchoscope under local anesthesia. Since the right basal bronchus demonstrated mucosal redness, edema, and granuloma formation (Fig. 1B) and the FB was lodged in the periphery of B9, the object could not be visualized through a bronchoscope. We attempted to retrieve it using alligator jaw grasping forceps, grasping baskets, and a grasping snare loop under fluoroscopic guidance. However, only the snare loop was able to grasp it, but it was unable to dislodge it from the bronchus. She was hospitalized and administered prednisolone (30 mg/day) for 4 days to improve the mucosal

* Corresponding author. Department of Thoracic Surgery, Faculty of Medicine, University of Tsukuba, Hitachi Medical Education and Research Center, 2-1-1 Jyounan, Hitachi, Ibaraki 317-0077, Japan.

E-mail address: ichimura@md.tsukuba.ac.jp (H. Ichimura).

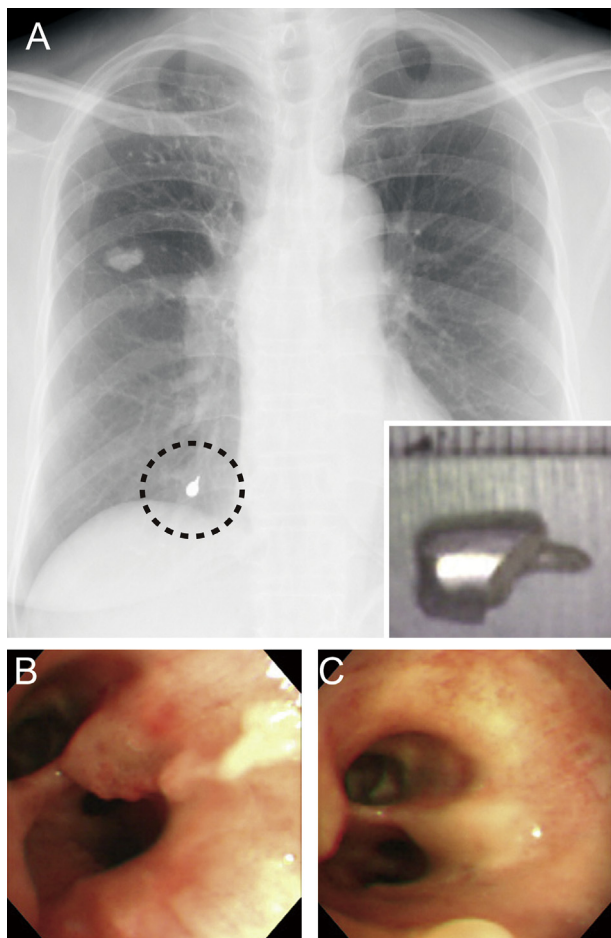


Fig. 1. a) Chest radiograph showing a radiopaque object in the right lower lung field (dotted circle). The inset image shows the retrieved dental prosthesis, 10 mm × 5 mm, with a scale bar. b) The bronchoscopic image shows mucosal redness, edema, and granuloma formation in the right basal bronchus. c) A bronchoscopic image taken after 4 days of prednisolone administration shows improvement of the mucosal inflammation.

inflammation. By the second bronchoscopy, swelling of the bronchial mucosa was improved (Fig. 1C), but the FB was still not visible. Since we were concerned about the possibility of fatal bleeding induced by dislodging and/or retrieving this periphery-lodged FB, we inserted an endotracheal tube to ensure access to the airway, and another bronchoscopist with another bronchoscope was standing by to wedge the bronchoscope into a bleeding bronchus as soon as possible in case of accidental bleeding. We again used a snare loop under fluoroscopic guidance. After grasping the FB, we repeatedly pushed and pulled the snare sheath to dislodge the object. In this way, we retrieved a dental prosthesis, 10 mm × 5 mm in size, without bleeding (Fig. 1A). The duration of the procedure was 20 minutes. Two days after the procedure, she was discharged without any adverse event.

2.2. Case 2

A 52-year-old woman was referred to our hospital for accidental aspiration of a dental prosthesis during dental treatment on the same day, and she complained of a cough. A chest radiograph showed a radiopaque object in the right pulmonary hilum (Fig. 2). Since her condition was stable, we retrieved the FB under local anesthesia using a flexible bronchoscope in an endoscopic room

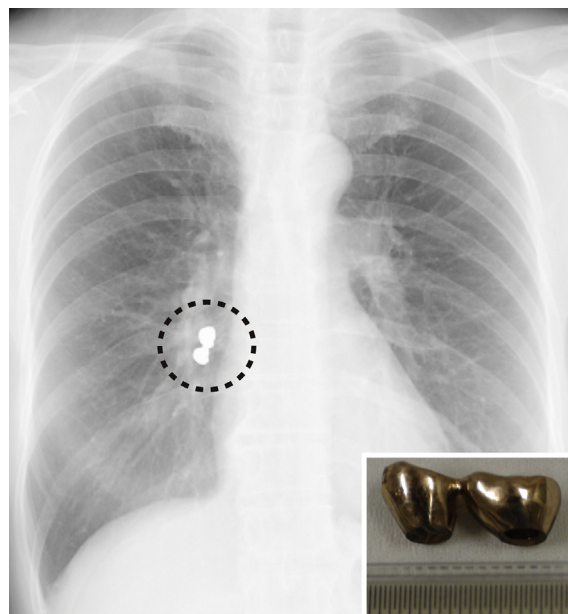


Fig. 2. Chest radiograph showing a radiopaque object in the right lung hilum (dotted circle). The inset image shows the retrieved dental prosthesis, 20 mm × 10 mm, with a scale.

equipped with a fluoroscope. The FB was found in the right intermediate bronchus and was not lodged; however, it could not be retrieved using a grasping basket and grasping forceps. Therefore, we used a snare loop under fluoroscopic guidance. The snare technique of FB retrieval through a bronchoscope and fluoroscopy is demonstrated in the Supplemental Digital Content 1. To encircle the FB with the loop under fluoroscopic observation, we bend the neck of the bronchoscope toward the opposite side of the inserted loop and tighten the loop slowly (Fig. 3). Although the FB is out of the view field during this neck-bending maneuver, the success of the looping can be confirmed through fluoroscopy. If the FB is looped, we can observe the FB being drawn toward the tip of the bronchoscope. After grasping the FB with the snare, the snare sheath is pushed out to keep the entire FB in the field of view. Particularly, when the FB passes through the vocal cords, the

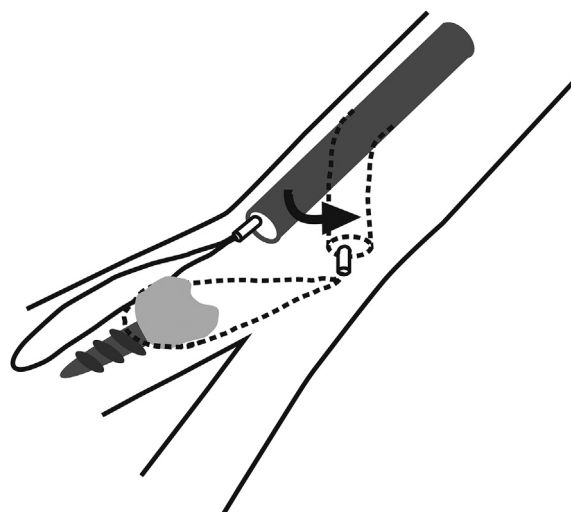


Fig. 3. Schema illustrating technical tips for encircling the snare loop around the foreign body, showing bending of the bronchoscope (arrow).

bronchoscope should be handled slowly, and the direction of the FB should be adjusted to minimize resistance from the vocal cords. We successfully retrieved a dental prosthesis, 20 mm × 10 mm (Fig. 2), without dropping it in the oral cavity, and without any other adverse event. The duration of the procedure was 10 minutes. A chest radiograph after the procedure was unremarkable, and the patient's general condition was stable; she went home with a follow-up chest radiography appointment scheduled at the outpatient clinic.

Supplementary video related to this article can be found at <http://dx.doi.org/10.1016/j.rmcr.2016.10.013>.

3. Discussion

We described two patients in whom an FB was successfully retrieved by flexible bronchoscope using the snare technique with a fluoroscope that enabled us to avoid thoracotomy in case 1 and rigid bronchoscopy and general anesthesia in case 2. An endobronchial FB is a rare clinical condition that accounts for 0.25–0.33% of the total number of bronchoscopic cases [1–3]. In a systematic review, the proportion of flexible bronchoscopies (6 studies, 354/159,074 procedures) performed for the indication of FBs among the total flexible bronchoscopies performed in adults is 0.24% (95% confidence interval 0.18–0.31) [3]. At our institution, we encountered 12 cases requiring bronchoscopic FB retrieval between 2004 and 2013, constituting 0.6% of the total number of patients who underwent bronchoscopy (n = 1990). We performed FB retrieval using a snare loop in five cases, including the two cases presented herein. All of these involved dental prostheses with some features in common, namely, the dental prostheses were rigid and had irregular surfaces or protruding portions, which made them suitable for the snare technique. However, FBs without features such as a smooth surface or organic material require another technique [4].

FB retrieval through a snare loop and flexible bronchoscope, with or without a fluoroscope, has been reported [5–7]. The application of the snare technique under fluoroscopic guidance without a bronchoscope has been reported in one case [8]. In our opinion, the snare technique has three advantages compared to other grasping devices. First, it is applicable to FBs of a wide range, given that it can be adjusted to a wide range of loop sizes. Second, it is less traumatic, even when used at the peripheral bronchus, compared to other grasping forceps such as alligator jaw grasping forceps. Third, it produces a reliable grasping force that helps to dislodge the FB by pushing and pulling the snare sheath, and it prevents bronchoscopists from dropping the FB in the oral cavity, which may result in accidental ingestion. These advantages of the snare loop technique are enhanced and strengthened when combined with fluoroscopy. Fluoroscopy enables use of the snare technique for a peripherally lodged FB that cannot be visualized by using a flexible bronchoscope, as in case 1. Even in cases where the FB is visible, as presented in case 2, fluoroscopy helps bronchoscopists encircle the FB with the snare by allowing visualization of

the loop (Supplemental Digital Content 1).

Although the snare technique with fluoroscopy has been previously reported, no technical tips for this procedure have been described to date [7,8]. On the basis of our experience, we described some tips in detail that should be considered during this procedure in this case presentation. The snare loops currently available only spread out along the direction of the snare sheath, and they require some technical skill to encircle the FB with the loop. Nalaboff et al. [8] used an endovascular snare device that has a 90°-angled loop. With this device, the loop spreads out coaxially to the bronchial lumen, which may make FB grasping easier. We hope that angled snare devices for flexible bronchoscopes will become available in the near future.

4. Conclusions

For patients in a stable condition presenting with an endobronchial FB, such as a dental prosthesis, a flexible bronchoscope should be the first choice. During the procedure, the bronchoscopist may choose their preferred device first. If the procedure using this first device fails, a snare technique under fluoroscopic guidance is an option.

Funding

This research did not receive any specific grant from funding agencies in the public, commercial, or not-for-profit sectors.

Conflicts of interest

None.

References

- [1] K. Mise, A. Jurcev Savicevic, N. Pavlov, S. Jankovic, Removal of tracheobronchial foreign bodies in adults using flexible bronchoscopy: experience 1995–2006, *Surg. Endosc.* 23 (2009) 1360–1364.
- [2] M.B. Ramos, A. Fernández-Villar, J.E. Rivo, V. Leiro, E. García-Fontán, M.I. Botana, M.L. Torres, M.A. Cañizares, Extraction of airway foreign bodies in adults: experience from 1987–2008, *Interact. Cardiovasc. Thorac. Surg.* 9 (2009) 402–405.
- [3] I.S. Sehgal, S. Dhoooria, B. Ram, N. Singh, A.N. Aggarwal, D. Gupta, D. Behera, R. Agarwal, Foreign body inhalation in the adult population: experience of 25,998 bronchoscopies and systematic review of the literature, *Respir. Care* 60 (2015) 1438–1448.
- [4] I.S. Sehgal, S. Dhoooria, D. Behera, R. Agarwal, Use of cryoprobe for removal of a large tracheobronchial foreign body during flexible bronchoscopy, *Lung India* 33 (2016) 543–545.
- [5] C.Y. Tu, H.J. Chen, W. Chen, Y.H. Liu, C.H. Chen, A feasible approach for extraction of dental prostheses from the airway by flexible bronchoscopy in concert with wire loop snares, *Laryngoscope* 117 (2007) 1280–1282.
- [6] N. Jamshed, K. Madan, M. Ekka, R. Guleria, Successful flexible bronchoscopic management of a large-sized aspirated partial denture, *BMJ Case Rep.* 2014 (2014), <http://dx.doi.org/10.1136/bcr-2013-202371> pii: bcr2013202371.
- [7] N. Umopathy, J. Panesar, B.F. Whitehead, J.F. Taylor, Removal of a foreign body from the bronchial tree—a new method, *J. Laryngol. Otol.* 113 (1999) 851–853.
- [8] K.M. Nalaboff, J.L. Solis, D. Simon, Endobronchial foreign body extraction: a new interventional approach, *Chest* 120 (2001) 1402–1405.