

AMCoR

Asahikawa Medical University Repository <http://amcor.asahikawa-med.ac.jp/>

感染症学雑誌 (1993.03) 67巻3号:231～235.

Successful Antifungal Treatment of Disseminated Candidiasis Associated
with ARDS
(ARDSを伴った播種性カンジダ症の1例)

秋葉裕二、長内 忍、中野 均、松本博之、小野寺壮吉

臨 床

Successful Antifungal Treatment of Disseminated Candidiasis Associated with ARDS

Yuji AKIBA, Shinobu OSANAI, Hitoshi NAKANO, Hiroyuki MATSUMOTO
and Sokichi ONODERA

First Department of Internal Medicine, Asahikawa Medical

(Received: September 24, 1992)

(Accepted: December 7, 1992)

Key words: disseminated candidiasis, adult respiratory distress syndrome,
opportunistic infection

Introduction

In recent years, fungi have played an increasingly important role as pathogens in opportunistic infections. Disseminated candidiasis is a significant cause of morbidity and mortality in immunocompromised patients¹⁾. Empirical antifungal therapy still seems to be mandatory in the treatment of such severe life-threatening infections as disseminated candidiasis. A combination of antifungal agents such as fluconazole plus flucytosine is thought to be effective and well tolerated for the systemic therapy of these infections.

Case Report

The patient was a 51-year-old female who had a 3-year history of malaise, intermittent fever and dry cough. She lost 15 kg over the previous year. She was admitted to a local hospital for left hypochondralgia and fever (39°C), and antibiotic treatment was started with a diagnosis of pyelonephritis. An indwelling intravenous hyperalimentation catheter and urinary catheter were inserted because of her severe general malaise and malnutrition. Although combination chemotherapy with flomoxef (2 g/day i.v.) and amikacin (400 mg/day i.m.) was tried for seven days, high fever continued, and a severe dry cough and shortness of breath occurred. Since chest radiographs showed bilateral infiltrative shadows, and respiratory failure progressed rapidly, the patient was transferred to our hospital. Examination on admission showed an obviously ill, febrile emaciated female. The patient was slightly anemic and displayed central cyanosis. She was dyspneic (respiratory rate 48 a min.) and exhibited sinus tachycardia, and crackles were audible at the base of both lungs. Systemic arterial blood pressure was within the normal range. Neurological examination at this time showed no abnormal findings. Laboratory data on admission showed: hemoglobin 9.6 g/dl, white cells 19,000/mm³ (93% neutrophils), C-reactive protein 141.5 µg/ml, and erythrocyte sedimentation rate 127 mm/hour. The biochemistry studies yielded a serum albumin of 2.2 g/dl and serum lactate dehydrogenase of 523 IU/L (slightly elevated). Although her blood urea nitrogen and serum creatinine were within normal limits, her 24-hours creatinine clearance was reduced to 32.1 ml/min. Fasting blood sugar was 334 mg/dl and hemoglobin A1C was 13.7%, and she obviously has severe diabetes mellitus. Glycosuria, proteinuria and pyuria were also detected on urinalysis. Arterial blood gas analysis

別刷請求先：(〒078) 旭川市西神楽 4 線 5 号 3 番地

—11—

旭川医科大学第 1 内科 秋葉 裕二

平成 5 年 3 月 20 日

Fig. 1 Chest radiograph on admission (left picture) showing alveolar shadow with air-bronchogram (similar to butterfly shadow). Right image (35 days after admission) shows a decreased infiltrative shadow.

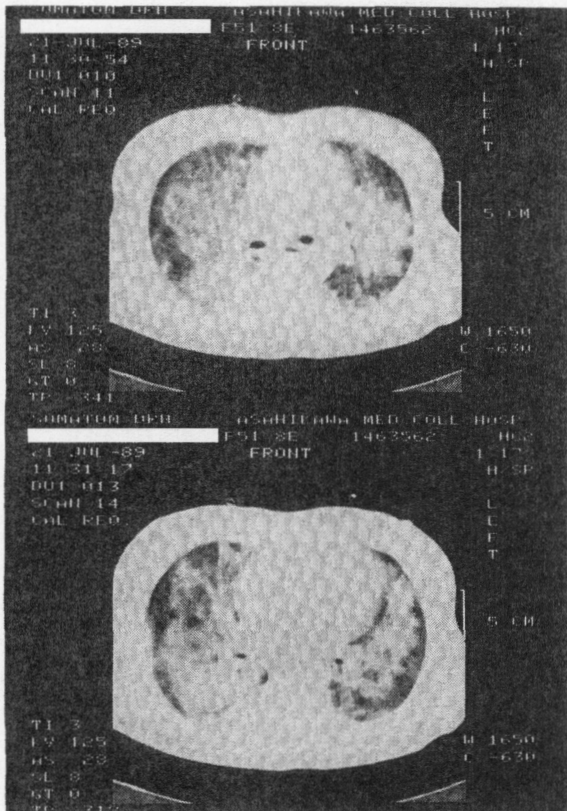
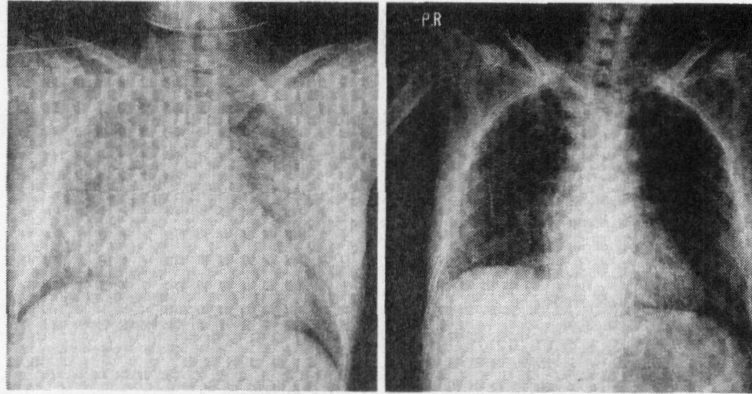
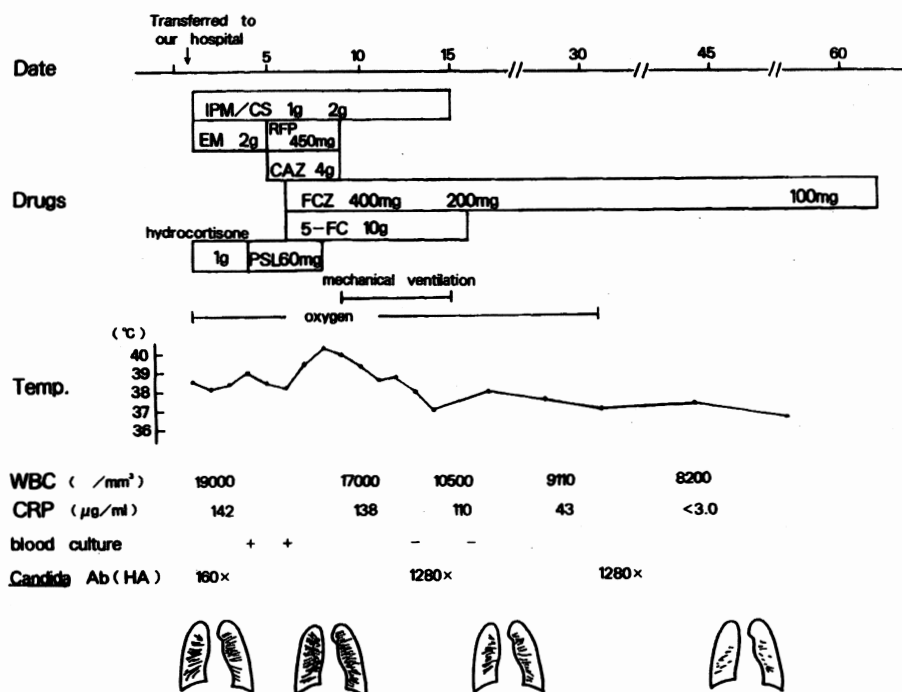


Fig. 2 Chest CT scans show bilateral infiltrative shadows distributed non-segmentally and accompanied by a subpleural marginal low-density area.

during room air breathing showed hypoxemia (PaO_2 40.6 Torr) and hypocapnia (PaCO_2 30.6 Torr). A chest radiograph on admission (Fig. 1) showed alveolar shadows with an air-bronchogram from the hilus to the middle of the lung fields (similar to a butterfly shadow). Bilateral infiltrative shadows on the chest CT scan (Fig. 2) were distributed non-segmentally and were accompanied by a sub-pleural marginal low-density area. An electrocardiogram on admission revealed sinus tachycardia and abnormally tall P waves in the inferior leads, but an echocardiogram failed to show any morphological or functional abnormalities of the

Fig. 3 Clinical course.



left heart. From this clinical picture the chest radiographic findings were thought to be the result of ARDS. Thus, we considered this case to represent opportunistic infection of an immunocompromized host, including the airway and urinary tract. Although we started antibiotic therapy (imipenem/cilastatin 2 g/day i.v., erythromycin 2 g/day i.v., ceftazidime 4 g/day i.v., rifampicin 450 mg/day orally) and tried corticosteroid hormones (hydrocortisone 1 g for three days followed by prednisolone 60 mg/day) after admission (Fig. 3), the various clinical findings became aggravated. On the 5th day after admission the patient manifested consciousness disturbances such as somnolence, aphasia and paresis of the right upper extremity. A brain CT scan revealed no evident focal lesion, but diffuse narrowing of brain sulci was observed, suggesting brain edema, and lumbar puncture showed an increase in mononuclear cells in the spinal fluid. These findings were highly suggestive of encephal meningitis, possibly caused by a fungus or virus. We decided to start using antifungal agents (fluconazole 400 mg/day i.v., plus flucytosine 1 g/day orally). On the 8th day after admission respiratory failure was still progressing and this was complicated by disseminated intravascular coagulation (DIC). Thus, the patient was forced to adjust to mechanical ventilation, and anticoagulant therapy was started. At this time *Candida albicans* was isolated repeatedly from her arterial blood culture, the tip of the intravenous hyperalimentation catheter, the urine culture, and the aspirated sputum culture (all cultured before using antifungal agents), although we could not distinguish *C. albicans* foci by transbronchial lung biopsy. Clinically silent endophthalmitis was also observed in this patient. Accordingly, we diagnosed this case as disseminated candidiasis, stopped prescribing corticosteroid hormones and continued to use the antifungal agents. Since then, the patient's respiratory failure, neurological abnormalities and other clinical signs have gradually improved (Fig. 1, Fig. 3).

Discussion

We have reported a case of disseminated candidiasis, which is usually a significant cause of morbidity and mortality in immunocompromised patients¹⁾. Total parenteral nutrition lines are prone to colonization by *C. albicans*^{2,3)}. Most cases of candidemia associated with total parenteral nutrition have been asymptomatic, but clinically silent endophthalmitis is common²⁾, and some cases of fatal *Candida* septicemia have been reported⁴⁾. The patient reported here were debilitated and immunosuppressed. She was also found to have diabetes mellitus which had never been treated. In addition, she had an indwelling intravenous hyperalimentation (IVH) catheter and urinary catheter, and was being given broad spectrum antibiotics and corticosteroids. Thus, the patient had a background of both opportunistic infection and nosocomial infection.

In this case *C. albicans* was isolated from arterial blood, the tip of the IVH catheter and the urinary catheter. Based on this clinical picture, we believed the source of this infection to be the IVH catheter or the urinary catheter, and that the *Candida* species may have generalized hematogenously. Although *C. albicans* was also isolated from aspirated sputum, the fact that *Candida* species were identified in sputum and even in bronchoalveolar lavage do not necessarily mean pulmonary candidiasis. Furthermore, although we performed transbronchial lung biopsy, we could not distinguish *C. albicans* foci. Because of these findings, we did not think that the patient had bronchopulmonary candidiasis (as a "primary" pulmonary candidiasis)⁵⁾, but ARDS secondary to candidemia. Thus, the chest radiographic findings and the pathogenesis of acute respiratory failure in this case could be explained as pulmonary edema due to an increase in pulmonary microvascular permeability following sepsis⁶⁾.

Fluconazole and flucytosine appear to have been effective in this patient. The therapy of invasive fungal infection (as in this patient) is difficult, and until recently there were very few antifungal agents commercially available for systemic therapy. Among these agents, such polyenes as amphotericin B have been considered the gold standard for most invasive fungal infections. However this agent is often poorly tolerated and leads to numerous side effects such as fever, hypotension, hypertension, hypokalemia, and renal failure as major toxicity. Moreover, isolation of polyene-resistant yeasts from clinical specimens has been reported⁷⁾. Fluconazole is a new antifungal agent with a bistriazole structure. It diffuses freely into tissues and body fluids, and unlike itraconazole, it easily crosses the blood-brain barrier. A high penetration into tissues and body fluids has been reported⁸⁾. Fluconazole can be administered either orally or intravenously, and plasma protein binding is less than 12% (ketoconazole and miconazole are about 99%)⁹⁾. Fluconazole had fewer side effects than amphotericin B, and is thought to be effective and well tolerated in the treatment of severe life-threatening infections, as in this patient. In this case, flucytosine was used in combination with fluconazole. Based on the pharmacokinetic and antifungal efficacy of fluconazole, a high synergistic effect was expected¹⁰⁾.

We used the antifungal agent empirically before the isolation of *C. albicans* from the patient. Early methods of diagnosis would probably result from the development of better serological tests, e.g., by antigen or metabolite detection. However, empirical antifungal therapy still seems mandatory at this time because of the poor diagnostic tools for detecting invasive fungal infections early in their evolution.

References

- 1) Meunier-Carpentier, F., Kiehn, T.E. & Armstrong, D.: Fungemia in the immunocompromised host. Changing patterns, antigenemia, high mortality. *Am. J. Med.* 71: 363-370, 1981.
- 2) Henderson, D.K., Edwards, J.E. & Montgomerie, J.Z.: Haematogenous candida endophthalmitis in patients receiving parenteral hyperalimentation fluids. *J. Infect. Dis.* 143: 655-661, 1981.
- 3) Sydam, D.R., Murray, S.A., Kornfield, S.J., Kornfield, S.J., Majka, J.A. & Ellis, C.A.: Total parenteral nutrition

- related infections. Prospective epidemiological study using semiquantitative methods. *Am. J. med.* 73: 695—699, 1982.
- 4) Wolfe, B.M., Ryder, M.A. & Nishikawa, R.A.: Complications of parenteral nutrition. *Am. J. Surg.* 152: 93—99, 1986.
 - 5) Chakaravarty, S.C.: Bronchopulmonary candidiasis —Clinical aspect. *Dis. Chest.* 51: 608—613, 1967.
 - 6) Shale, D.J.: The adult respiratory distress syndrome —10 years on. *Thorax.* 42: 641—645, 1987.
 - 7) James, D.D., Bruce, R.R., William, G.M., Robert, K.S., Groven, M.H. and Rein, S.: Fatal disseminated candidiasis due to amphotericin-B-resistant *Candida guilliermondii*. *Ann. Intern. Med.* 102: 67—68, 1985.
 - 8) Perfect, J.R., Savani, D.V. and Durak, D.T.: Comparison of itraconazole and fluconazole in treatment of cryptococcal meningitis and candida pyelonephritis in rabbits. *Antimicrob. Agents. Chemother.* 29: 579—583, 1986.
 - 9) Kujath, P. and Lerch, K.: Secondary mycosis in surgery: Treatment with fluconazole. *Infection.* 17: 111—117, 1989.
 - 10) Polak, A.: Combination therapy for systemic mycosis. *Infection.* 17: 203—208, 1989.

ARDSを伴った播種性カンジダ症の1例

旭川医科大学内科学第一講座

秋葉 裕二 長内 忍 中野 均
松本 博之 小野寺壮吉

(平成4年9月24日受付)

(平成4年12月7日受理)

要 旨

カンジダ血症は、日和見感染症の一つとして近年増加傾向にあり、注目されている。カンジダ血症のうち播種型ものは致死率の高い、きわめて重篤な経過を呈することが多い。今回我々は、51歳の女性にARDSを伴った播種性カンジダ症の1例を経験した。動脈血培養、中心静脈カテーテル先端およびカテーテル尿培養から *Candida albicans* が検出され、尿路ないしは中心静脈カテーテルを感染源に、血行性に播種したものと考えられた。入院時、著明な低酸素血症と胸部X線写真

上両側び漫性に肺泡性陰影を認めた。急性期のTBLBからは血管内でのカンジダ増殖などの病理学的所見は得られなかったが、播種性カンジダ症の部分症状として続発性に発症したと考えられた。発症誘因として、コントロール不良な糖尿病を背景に、広域抗生物質などの使用が助長因子として働いたと考えられた。治療としては、組織移行性、副作用、一次耐性などの観点から有利なfluconazoleを選択し、flucytocineとの併用が奏功した。