

AMCoR

Asahikawa Medical College Repository <http://amcor.asahikawa-med.ac.jp/>

Surgery (September 2009) 146(3):515–518.

Portal annular pancreas, a notable pancreatic malformation: Frequency, morphology, and implications for pancreatic surgery

Karasaki, Hidenori ; Mizukami, Yusuke ; Ishizaki, Akira ;
Goto, Jyunichi ; Yoshikawa, Daitaro ; Kino, Shuichi ;
Tokusashi, Yoshihiko ; Miyokawa, Naoyuki ; Yamada,
Tomonori ; Kono, Toru ; Kasai, Shinichi

**Portal annular pancreas, a notable pancreatic malformation: Frequency,
morphology, and implications for pancreatic surgery**

Hidenori Karasaki, MD, PhD¹, Yusuke Mizukami, MD, PhD², Akira Ishizaki, MD, PhD¹,
Jyunichi Goto, MD, PhD¹, Daitaro Yoshikawa, MD¹, Shuichi Kino, MD, PhD³,
Yoshihiko Tokusashi, MD, PhD⁴, Naoyuki Miyokawa, MD, PhD⁴,
Tomonori Yamada, MD⁵, Toru Kono, MD, PhD¹, and Shinichi Kasai, MD, PhD¹

¹ Division of Gastroenterological and General Surgery, Department of Surgery,

² Division of Gastroenterology and Hematology/Oncology, Department of Medicine,

³ Department of Clinical Laboratory and Blood Center,

⁴ Department of Surgical Pathology,

⁵ Department of Radiology, Asahikawa Medical College, Hokkaido, Japan

Correspondence to: Hidenori Karasaki, MD, PhD

Division of Gastroenterologic and General Surgery, Department of Surgery, Asahikawa Medical
College. 2-1 Midorigaoka Higashi, Asahikawa, Hokkaido 078-8510, Japan

Phone: 81-166-68-2503; Fax; 81-166-68-2193; E-mail: karasaki@asahikawa-med.ac.jp

Running title: Portal Annular Pancreas

Key Words: portal annular pancreas, malformation, anomaly, uncinata process

Abbreviations: PAP, portal annular pancreas; MDCT, multidetector computed tomography

Introduction

Portal annular pancreas (PAP) is a pancreatic anomaly in which the uncinate process of the pancreas extends and fuses to the dorsal surface of the body of the pancreas by surrounding the portal vein. To the best of our knowledge, there have only been three reports of a PAP in the literature.¹⁻³ During pancreatic resection, the presence of a PAP significantly affects the procedure, including the pancreaticointestinal reconstruction. Thus, it is important to recognize a PAP preoperatively; however, the frequency and characteristics of the anomaly have yet to be precisely determined. Our experience of technical difficulty during a pancreaticoduodenectomy in a patient with a PAP and distal bile duct adenocarcinoma led us to determine the frequency of PAP and its morphological features. To this end, we reviewed abdominal contrast-enhanced multidetector computed tomographies (MDCTs) to determine the incidence of PAP.

Materials and Methods

Abdominal contrast-enhanced MDCT scans (4-row Aquilion Toshiba, Tokyo) were performed at Asahikawa Medical College Hospital from February 1, 2006 to October 30, 2006. The 700 images of patients (363 men and 337 women; mean age \pm standard deviation [SD] 61.2 \pm 14.9 years) whose last name began with A, E, I, K, O, or U were selected and examined by 3 independent radiologists and gastroenterologists. The images were specifically evaluated for PAP, by identifying fusion of the pancreatic body and uncinate process. A PAP was defined in

cases with a clearly visualized 'continuity' in at least in two serial slices. To eliminate false-positives, cases with a fat layer between the body of the pancreas and the uncinate process were excluded. Furthermore, each PAP was categorized based on the anatomical relationship between the fusion and the splenoportal confluence. In the supra-splenic vein type, the fusion occurs cranial to the confluence; in the infra-splenic vein type, it occurs caudal to the confluence; and in the mixed type, it occurs on both sides of the confluence. The horizontal length of the fused area was also measured. The χ^2 test was used to analyze differences between the sexes, with the level of significance set at $p < 0.05$.

Results

A PAP was identified in 8 of the 700 patients (1.14%). Seven of 8 cases were women, indicating that PAP was significantly more common in women than men ($p=0.03$). The patients' diseases were hepatoma, adrenal adenoma, uterine carcinoma, pancreatic cyst, adenoma of the colon; however the anomaly was not associated with any specific diseases. Six patients had supra-splenic vein type PAPs, 1 had an infra-splenic vein type, and 1 had a mixed type (Figure 1, 2). The horizontal length of the fusion ranged from 4.7 to 14.7 mm (mean \pm SD: 9.4 ± 3.3 mm).

Case Report

A 73-year-old woman with a distal bile duct carcinoma had an infra-splenic vein type PAP that was clearly visible on her preoperative abdominal contrast-enhanced MDCT. A pylorus-preserving pancreaticoduodenectomy was performed. When the pancreatic head and body were separated at the level of the portal vein, the uncinete process was found to extend back to the body and surround the superior mesenteric vein. Unusually, the lingual projection and the body of the pancreas were fused. To perform a pancreaticoduodenectomy, it was therefore necessary to cut through the fused region. This resulted in two individual planes of division, one including the main pancreatic duct and the second across the region of fusion (Figure 3). A pancreaticogastrostomy was performed as a reconstruction procedure. Postoperatively, a pancreatic fistula occurred at the site of the pancreaticogastrostomy but improved with conservative management.

Discussion

A PAP is a pancreatic malformation in which the uncinete process wraps annularly around the portal vein and fuses to the body of the pancreas. The first case of a PAP was described by Sugiura *et al.* in 1987, and two subsequent reports were published in 2001 and 2004.¹⁻³ However, to the best of our knowledge, no subsequent reports on the malformation appeared and little attention was devoted to its frequency or how it could potentially affect pancreatic surgery.

We reviewed 700 abdominal contrast-enhanced MDCT scans irrespective of the patient's underlying disease and sex. Because the objective was to determine the frequency of PAP, the index case was not included in the study period. Since there have been only three previously reported PAP cases, we expected the anomaly to be extremely rare. However, to our surprise, 8 of the 700 patients (1.14%) had evidence of it. In contrast, no patients with an annular pancreas or malrotation were found, indicating a higher prevalence of PAP. The frequency of annular pancreas detected by endoscopic retrograde pancreatography (ERP) has been reported as 0.1 %, ⁴ but we identified PAP by MDCT much more frequently. The male-to-female ratio for annular pancreas has also been reported as 3:2. ⁵ However, we found PAP more frequently observed in women, with a male-to-female ratio of 1:7.

In the present study, the mean length of the fusion between the lingual projection and the body of the pancreas was 9.4 mm and, in 2 of the 8 patients with a PAP, less than 5 mm. A PAP may be overlooked during surgical intervention because of a very narrow and/or weak fusion between the uncinate process and body. In contrast to an annular pancreas, a PAP usually cannot be demonstrated easily by ERP. Furthermore, clinical issues related PAP emerges only when surgical intervention is required, and the malformation is not related to any specific underlying disease. Thus, even though PAP is not an extremely rare anomaly, it often remains unrecognized by surgeons. However, recent advances in CT make it possible to visualize and identify if one looks for it.

During pancreaticoduodenectomy in patients with PAP, the pancreatic parenchyma needs to be dissected to separate the lingual projection from the dorsal surface of the body of the pancreas, making a 'second' divided plane (Figure 3). In our index patient, the dorsal dissection may have caused a pancreatic fistula. In addition, the adenocarcinoma in the intra pancreatic bile duct extended very close to the 'second' divided plane via the lingual projection by perineural infiltration. Therefore, to overcome these issues in PAP patients, the pancreas should be resected at a site distal to the fusion. However, this needs to be carefully considered based on residual pancreatic function.

In this study, each PAP was classified as the supra-splenic vein type (6/8), infra-splenic vein type (1/8), and mixed type (1/8). With the supra-splenic vein type, the lingual projection may involve the celiac artery, common hepatic artery, and splenic artery, potentially making resection more difficult than in the infra-splenic vein type. In the mixed type, the fusion potentially makes resection even more difficult because of the wide fusion plane.

In summary, the PAP is a malformation observed in higher frequency than the annular pancreas, particularly in women. MDCT is a useful modality for preoperatively diagnosing a PAP. We recommend that surgeons carefully review MDCTs to identify this anomaly and plan procedures accordingly.

Figure legends

Figure 1

Schematic illustrations of normal pancreas and 3 types of PAP. (A) Normal pancreas. (B) Supra-splenic vein type PAP. The lingual projection from the uncinate process fused to the body of the pancreas by surrounding the portal vein cranial of the splenoportal confluence. (C) Infra-splenic vein type PAP, in which the fusion occurs caudal to the confluence. (D) Mixed type PAP. The fused pancreas covers both portal trunk and superior mesenteric vein. Arrow head indicates the fusion between the lingual projection and the body of the pancreas.

Figure 2

Representative MDCT images of the supra-splenic vein type of portal annular pancreas. Images are shown between the portal trunk level (A, B) and splenoportal confluence level (C). Note that the portal vein is surrounded by pancreatic parenchyma; the stretched pancreatic uncinate process fuses to the body of the pancreas (arrow heads).

Figure 3

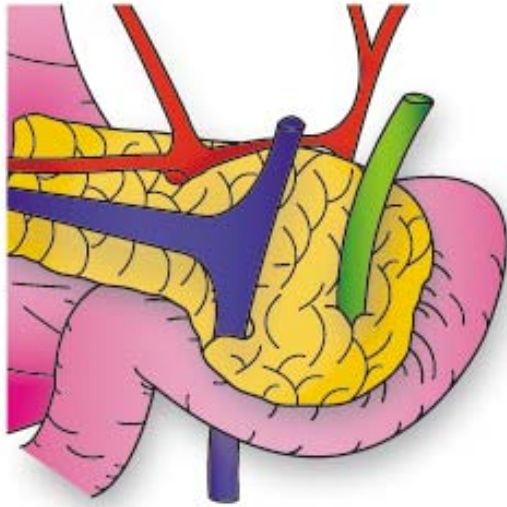
Schematic diagrams of the two pancreatic resection lines. The left illustration shows the division of the body of the pancreas including the main pancreatic duct (solid line) and a 'second cut' between the lingual projection and the unusual, fused part (dotted line). The image on the right shows the two planes of incision of the remaining pancreas.

References

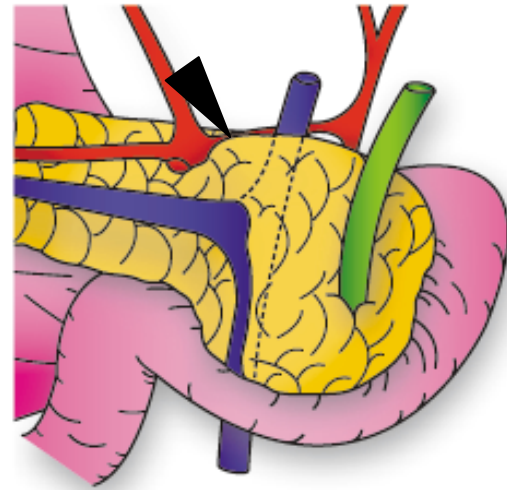
1. Sugiura Y, Shima S, Yonekawa H, Yoshizumi Y, Ohtsuka H, Ogata T. The Hypertrophic Uncinate Process of the Pancreas Wrapping the Superior Mesenteric Vein and Artery. *Japanese Journal of Surgery*. 1987;17:182-5.
2. Mizuma M, Suzuki M, Unno M, Katayose Y, Rikiyama T, Takeuti H, et al. A case of “Portal Annular Pancreas” in that the ventral pancreas joins with the pancreatic body encircling the portal vein. *Tan to sui*. 2001;22:963-6.
3. Savastano S, Alessi S, Fantozzi O, Corra S, Zonta L. MRI diagnosis of a periportal annular pancreas. *European Journal of Radiology Extra*. 2004;50:93-5.
4. Chevillotte G, Sahel J, Raillat A, Sarles H. Annular pancreas. Report of one case associated with acute pancreatitis and diagnosed by endoscopic retrograde pancreatography. *Dig Dis Sci*. 1984;29:75-7.
5. Kiernan PD, ReMine SG, Kiernan PC, ReMine WH. Annular pancreas: May Clinic experience from 1957 to 1976 with review of the literature. *Arch Surg*. 1980;115:46-50.

Figure 1

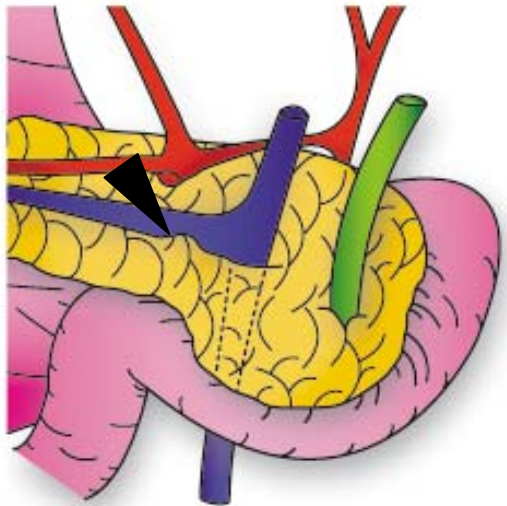
A



B



C



D

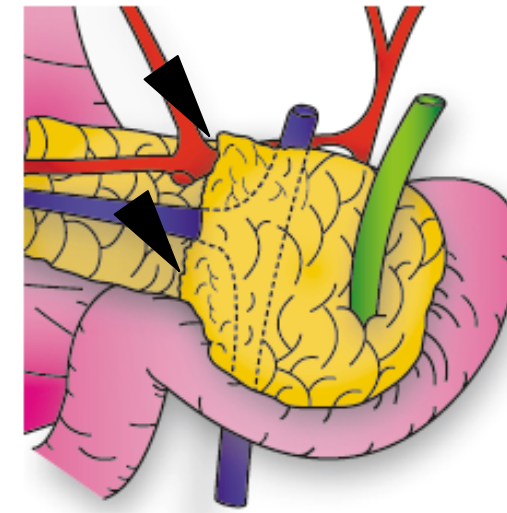


Figure 2

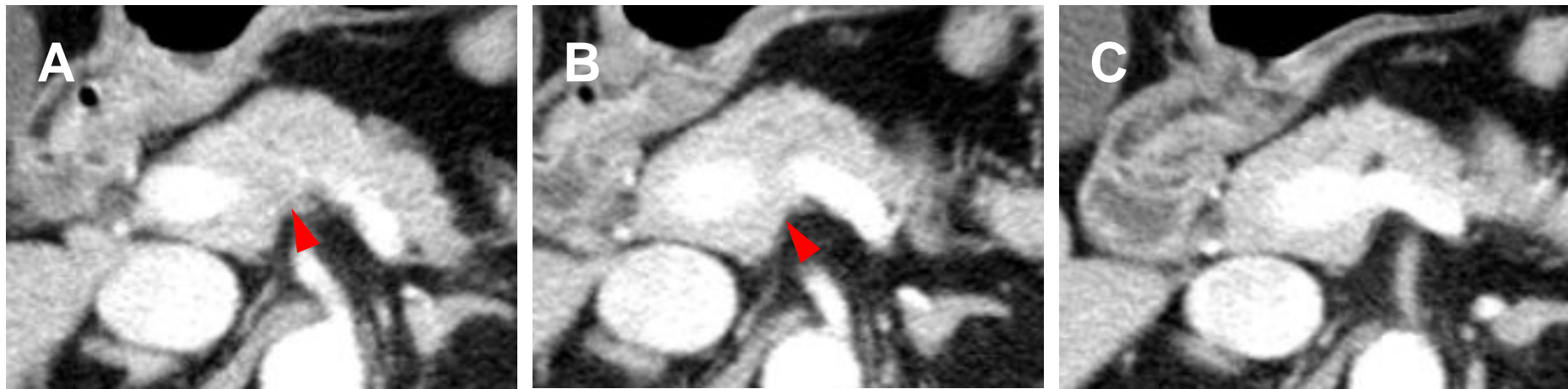


Figure 3

