



|                  |   |
|------------------|---|
| Title            | Freezing preparation for macroscopic forensic investigation in putrefied brain  |
| Author(s)        | Matoba, Kotaro; Hyodoh, Hideki; Murakami, Manabu; Matoba, Tomoko; Saito, Atsuko; Feng, Fei; Jin, Shigeki                                |
| Citation         | Legal medicine, 26, 6-10<br><a href="https://doi.org/10.1016/j.legalmed.2017.01.005">https://doi.org/10.1016/j.legalmed.2017.01.005</a> |
| Issue Date       | 2017-05   |
| Doc URL          | <a href="http://hdl.handle.net/2115/66990">http://hdl.handle.net/2115/66990</a>   |
| Rights(URL)      | <a href="http://creativecommons.org/licenses/by-nc-nd/4.0/">http://creativecommons.org/licenses/by-nc-nd/4.0/</a>                       |
| Type             | article   |
| File Information | 1-s2.0-S1344622317300287-main.pdf   |



[Instructions for use](#)



## Short Communication

## Freezing preparation for macroscopic forensic investigation in putrefied brain



Kotaro Matoba <sup>a,b</sup>, Hideki Hyodoh <sup>b,\*</sup>, Manabu Murakami <sup>c</sup>, Tomoko Matoba <sup>a</sup>, Atsuko Saito <sup>a</sup>, Fei Feng <sup>a</sup>, Shigeki Jin <sup>d</sup>

<sup>a</sup> Dep. Forensic Medicine, Graduate School of Medicine, Hokkaido University, Japan

<sup>b</sup> Center for Cause of Death Investigation, Graduate School of Medicine, Hokkaido University, Japan

<sup>c</sup> International Relations Office, Graduate School of Medicine, Hokkaido University, Japan

<sup>d</sup> Faculty of Health Science, Core Research Lab., Hokkaido University, Japan

## ARTICLE INFO

## Article history:

Received 9 November 2016

Received in revised form 13 January 2017

Accepted 14 January 2017

Available online 17 January 2017

## Keywords:

Postmortem CT: freeze

Putrefaction

Brain

Forensic pathology

## ABSTRACT

**Purpose:** To evaluate the usefulness of the applied freezing technique in putrefied brain for macroscopic investigation.

**Materials and methods:** From October 2015 to September 2016, first the brains of 10 cadavers (control group: male 6, female 4, age 20–80 (mean 61.5), postmortem intervals (PMI) 14–75 (mean 29.7) days) were inspected following the standard practice (without freezing preparation), and then with 10 cadavers (freezing group: male 7, female 3, age 41–88 (mean 60.4), PMI 7–75 (mean 29.2) days) the freezing technique was used before the autopsy. The cut brain was investigated, and the gray-white matter difference was evaluated macroscopically.

**Results:** In the control group, the brain parenchyma leaked out like sludge in 5, and there was difficulty maintaining its structure in 7. The gray-white matter difference was well visible in 3, but hard to distinguish in 3, and the total scores ranged from 0 to 9 (mean 4.4) points. In the freezing group, the entire putrefied brain was extracted as a solid organ, the gray-white matter differences were well visible, and the total scores were 6.7–9 (8.3) points. The gray-white matter difference was preserved in the freezing group ( $p < 0.05$ ).

**Conclusion:** The freezing procedures to evaluate the putrefied brain have been successfully applied, and it could be statistically more useful in putrefied brain investigation than the ordinary procedure. Postmortem CT can be useful to evaluate not only the degree of brain putrefaction, but also the degree of brain parenchyma freezing.

© 2017 The Author(s). Published by Elsevier Ireland Ltd. This is an open access article under the CC BY-NC-ND license (<http://creativecommons.org/licenses/by-nc-nd/4.0/>).

## 1. Background

One of the recent topics of interest in forensic medicine is postmortem CT [1,2], and it has been used for investigation of causes of death in many situations [3–6]. Some causes of death could be evaluated mainly by postmortem CT, and its usefulness has been recognized in supporting autopsy investigation [7,8]. On the other hand, postmortem CT has inherent limitations in the cases of specific causes of death [9]. Therefore it has been requested to compare its findings with those from toxicology and histopathological investigation [10,11]. In specific instances, such as putrefaction (long postmortem term), the cadaver affords a limited sample for

toxicological investigation and the histopathological examination also suffers limitations because of the organ deterioration. In putrefaction of the brain, the organ was destructed after extraction from the cranium, so that it had severe limitations, not only in macroscopic but also in histopathological investigation [12].

In our recent report about an animal experiment, using freezing procedure prior to opening the cranium, the putrefied brain could be extracted and undergo cut surface investigation macroscopically [13]. Therefore, it is anticipated to be of use in cadaver autopsies.

In this report, we applied the freezing technique in autopsy scene for macroscopic investigation, and we also evaluated its usefulness comparing with the standard practice.

\* Corresponding author at: Kita 15 Nishi 7 Kita-ku Sapporo, Hokkaido 060-8638, Japan.

E-mail address: [hyodoh@med.hokudai.ac.jp](mailto:hyodoh@med.hokudai.ac.jp) (H. Hyodoh).

## 2. Materials and method

This study was approved by our institutional ethics committee (No. 16-015). From October 2015 to September 2016, 20 putrefied cadavers (male 13, female 7, 20–88 (mean 61.0) y.o., 7–75 (mean 29.5) day postmortem interval (PMI)) were enrolled in this study. First the brains of 10 cadavers (designated as the control group) were inspected using standard practice (without freezing preparation), and the next 10 cadavers (designated as the freezing group) were used freezing technique before the autopsy. Two putrefied cadavers were excluded in this study, because of severe head trauma ( $n = 1$ ), and severe encroaching ( $n = 1$ ).

Before the autopsy examination, all cases were examined by CT using a 16-slice multi-detector CT scanner (Supria, Hitachi Corp., Tokyo). The scan parameters were as follows: 120 kV, 215 mA, 0.75 s/rotation, beam pitch 1.3125, collimation  $1.25 \times 16$ , slice thickness 5.0 mm. The intra-cranial air density volume, intra-cranial volume (estimated as maximum brain volume), and percentage air density volume (% air) were evaluated using an image workstation (VINCENT, FujiFilm Tokyo). The equation for % air was:

% air =  $100 \times (\text{intra-cranial air density volume}) / (\text{intra-cranial volume})$ . The degree of putrefaction was also estimated as softened or liquefied [14], equivalent as stage II or stage III in Watanabe's staging [12], according to the CT image appearance.

### 2.1. Freezing procedure

In the freezing group, at least 14 h prior to the scheduled autopsy, dry-ice blocks (1 kg each) were placed at both sides and the dorsal part of the cadaver's head. Before the autopsy, post-mortem CT imaging was repeated to confirm the brain freezing based on decreasing brain parenchymal CT density [15,16].

### 2.2. Sawing cranium and brain extraction

The standard skull opening procedure was used in the control group: having dissected the scalp, the skull was opened with an oscillating saw. If the brain parenchyma spilled out from the cranium, the sludge brain parenchyma was collected using a vat to measure its weight and to investigate it macroscopically.

In the freezing group, the sawing level was placed relatively close to orbit to make a wide operating space to extract the brain parenchyma. If the skin had become leathery due to a long post-mortem interval, or the skin was hard to remove from the skull, the dissection of the skin was performed after sawing the skull. An additional saw was considered in particular situations, such as the brain tissue was attached to the inner surface of the cranium, or the brain tissue was intentionally dissected at the level of the tentorium cerebelli to extract the cerebellum separately from the cerebrum.

### 2.3. Macroscopic investigation and fixation

Extracted brains were investigated macroscopically. If the putrefied brain was destructed before formaldehyde fixation, a cut macroscopic inspection was employed. After the brain surface macroscopic investigation, the whole brain parenchyma was placed in a 7.4% diluted buffered formaldehyde fixative solution for 2 weeks at room temperature (20 degree Celsius). Because the softened or liquefied brain cannot be fixed only using 7.4% diluted buffered formaldehyde fixation, 24 h prior to the cut inspection, the whole brain was placed in a minus 5 Celsius freezer with the diluted formaldehyde fixative. Using this additional freezing technique, the putrefied brain can be handled like a solid organ, and at the same time the formaldehyde kept its liquid state because pure

formaldehyde freezing point was minus 92 degree Celsius. After confirming the freezing of the brain parenchyma, the ideal cut could be employed for macroscopic investigation.

### 2.4. Statistical analysis

The male-to-female ratio, age, postmortem interval, brain volume, and % air were compared between two groups, statistically. To evaluate the cross gray-white matter appearance, a 4-point scale was employed: 3 points as clear, 2 as moderate, 1 as ambiguous, or 0 as poor. The data was scored by 3 observers (HH, KM, AS) independently, and the total score was used for statistical investigation. Variables were compared using the Chi-squared test, and a Mann-Whitney *U* Test using JMP (SAS Institute Inc., North California, USA, version 11.0.0) software. A *P* value of less than 0.05 was considered to indicate a statistically significant difference.

## 3. Results

The backgrounds of the groups were shown in the Table 1. In the control group, the causes of death were as follows; drowning ( $n = 4$ ), cardiac infarction ( $n = 2$ ), hemo-pericardium ( $n = 1$ ), and unknown ( $n = 3$ ). In the freezing group, the causes of death were as follows: drowning ( $n = 2$ ), brain hemorrhage ( $n = 2$ ), multiple organ failure ( $n = 1$ ), drug poisoning ( $n = 1$ ), hypo-nutrition ( $n = 1$ ), cardiac infarction ( $n = 1$ ), and unknown ( $n = 2$ ). In statistical evaluation, there were no significant differences between two groups in male-to-female ratio, age, and PMI.

### 3.1. Postmortem CT

In the control group, intra-cranial air presented in all cases, and its volume range was 55.2–485.4 (mean 255.2) ml. The % air compared with intra-cranial volume ranged from 3.8 to 39.5 (mean 19.0)%. The brain parenchyma decreased in volume and those were estimated as softened, 7, and liquefied, 3. In the freezing group, all cases presented intra-cranial air, and the volume range was 153.1–681.6 (mean 423.3) ml, and the % air was 11.0–47.3 (mean 29.4)% (Fig. 1a). The softened type was 3, and liquefied type was 7. Brain parenchymal density was 32.2–51.4 (mean 43.4) HU, and  $-6.6$  to  $23.1$  (mean 3.6) HU after freezing preparation (Fig. 1b). In statistical evaluation, there were no significant differences between two groups in the brain volume and % air.

### 3.2. Autopsy

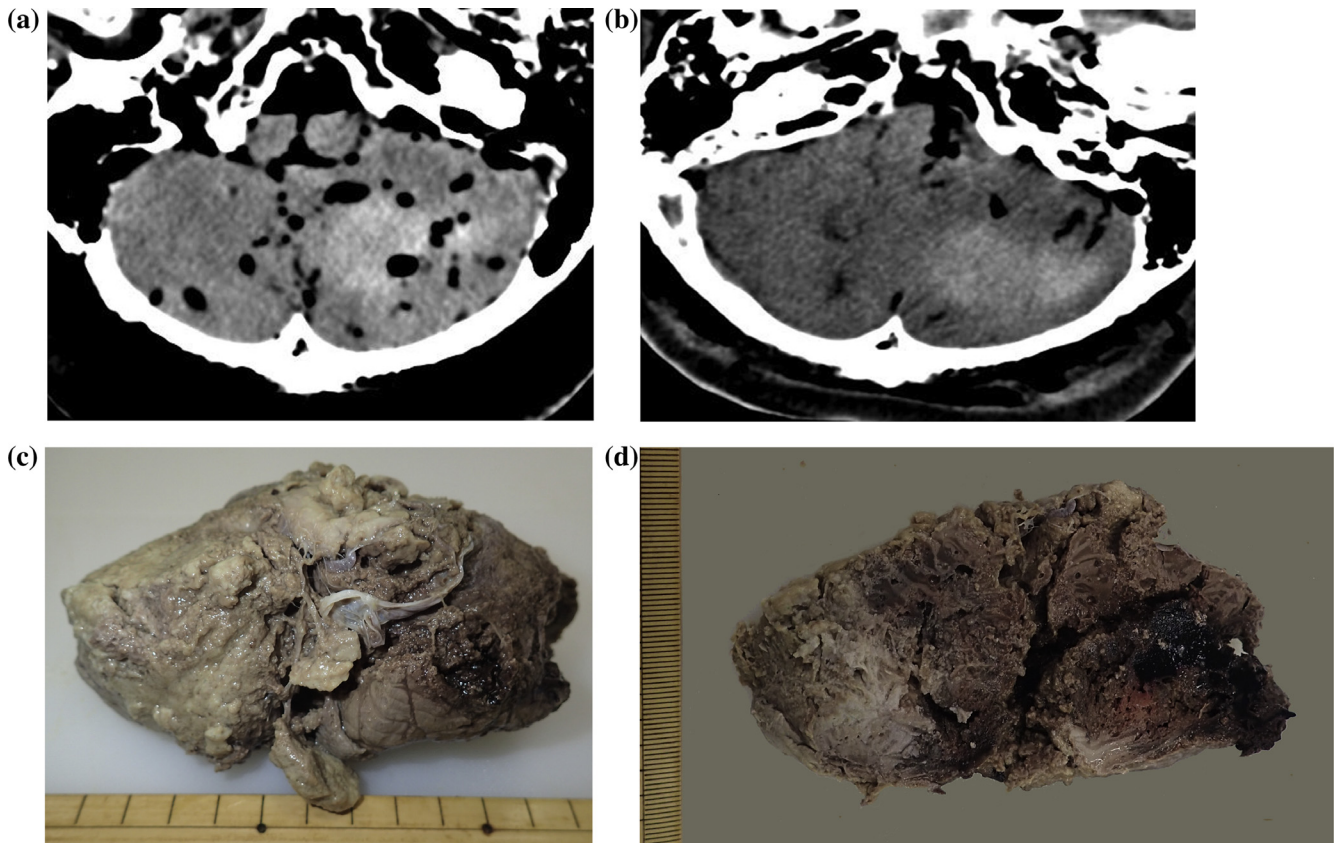
In the control group, all brain parenchyma were separated from the inner-surface of the cranium. After opening the cranium, the brain parenchyma leaked out like sludge in 5, and there was difficulty maintaining its structure in 7. After cutting the parenchyma,

**Table 1**  
Summary of data.

|  | Control group<br>( $n = 10$ ) | Freezing group<br>( $n = 10$ ) | <i>P</i><br>value |
|--|-------------------------------|--------------------------------|-------------------|
| Male-to-female ratio                             | 6: 4                          | 7: 3                           | 0.6388            |
| Age (year)                                       | 20–80 (61.5)                  | 41–88 (60.4)                   | 0.3843            |
| PMI (day)  | 14–75 (29.7)                  | 7–75 (29.2)                    | 0.6728            |
| Brain volume (ml)                                | 1049–1620<br>(1294)           | 1200–1630<br>(1433)            | 0.1038            |
| % air (%)  | 3.8–39.5<br>(19.0)            | 11.0–47.3<br>(29.4)            | 0.0588            |
| Gray-white matter difference<br>inspection score | 0.0–9.0 (4.4)                 | 6.7–9.0 (8.3)                  | 0.0424            |

PMI: postmortem interval.

% air =  $100 \times (\text{intra-cranial air density volume}) / (\text{intra-cranial volume})$ .



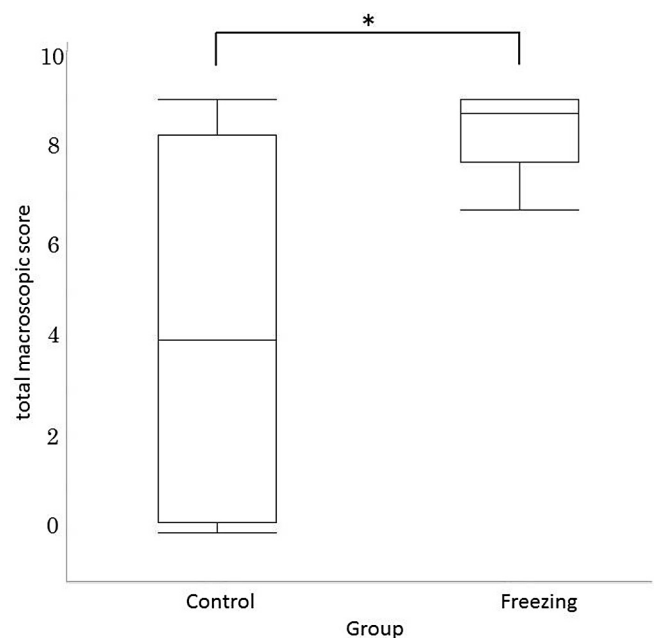
**Fig. 1.** (a) 56 year-old male, cerebellar bleeding, 7 days postmortem interval. (a) postmortem CT, (b) after freezing preparation CT, (c) cerebellum extraction macroscopic inspection (from front), and (d) cerebellum cut inspection (from bottom). (a) Brain parenchyma presents air density and decreased its volume, and putrefaction is thought likely due to the postmortem interval. High density presented at the left cerebellar hemisphere and it is estimated as cerebellar bleeding/hematoma. (b) After freezing preparation, the brain parenchymal and also hematoma are decreasing their density, but the difference is detectable. (c) The cerebellum was extracted separating it from the cerebrum, because the freezing brain parenchyma is difficult to extract as a continuous organ. (d) The hematoma is presented at the left cerebellar hemisphere. The adjacent cerebellar parenchyma presents hemoglobin staining. The gray-white matter is well visible, and the total macroscopic investigation score is 7 points.

the gray-white matter difference was well visible in 3, hard to distinguish in 3, and the total score was 0–9 (mean 4.4) points.

In the freezing group, all putrefied brains were extracted as a solid organ. Because of its limitation of flexibility, the cerebellum was extracted separately from the cerebrum (Fig. 1c). Two cases presented intra-cranial bleeding, and the distribution of bleeding (hematoma) was well visible in cut inspection (Fig. 1d). The gray-white matter differences were well visible and the total score was 6.7–9 (8.3) points. In statistical evaluation, the gray-white matter difference was preserved in the freezing group ( $p < 0.05$ ) (Fig. 2). Kappa coefficients were from 0.745 to 0.414 (average 0.527), so that the strength of agreement was moderate.

#### 4. Discussion

It is commonly accepted that putrefied tissue is hard to inspect, especially in brain parenchyma [17,18]. There are a number of stages in the putrefaction of the brain: normal (discolored), softened, or pulpified (liquefied) [12,19,20]. Unfortunately, autopsy investigation was at a large disadvantage with a putrefied brain, because it seemed difficult to preserve a large portion of the brain anatomy coherency after it was extracted from the cranium [19]. According to the prior experimental evaluation, the putrefied brain could be frozen and it could be extracted from the head in bulk [13]. Sugimoto et al. [15] reported that the cadaver's brain was frozen using dry ice placed beside the cadaver's head, and the cerebellum could be removed from the putrefied body. They speculated that using an adequate freezing technique, the putrefied brain



**Fig. 2.** Gray-white matter difference macroscopic investigation total score (Mann-Whitney  $U$  Test). The freezing group presents better preservation for gray-white matter cut inspection compared to the conventional method in putrefied brain. \* $p < 0.05$ .

might be extracted for autopsy inspection [15]. In this study, four steps method for macroscopic inspection of putrefied brain was used: the method of freezing the putrefied brain, the method of extracting the frozen brain, the method of buffered formaldehyde fixation of freezing brain, and the method of re-freezing, for cut macroscopic inspection. Using these techniques, putrefied brain can be inspected not only at the surface but also after adequate slice cut inspection, macroscopically. This is the first report of a procedure to freeze a cadaver's putrefied brain prior to the autopsy investigation, intentionally.

In this study, dry ice could be used to make the putrefied brain freeze. Because using dry ice could produce a temperature of minus 79 degree Celsius, and the temperature was similar to the experimental study [13]. Furthermore, our methods needed no specific equipment to induce freezing in the putrefied brain; it was simply required to place dry ice surrounding the head at least 14 h prior to the autopsy. Therefore, this method is very useful in practical investigation. Using this procedure, not only the putrefied brain but also loss of brain coherency, such as a brain bruise, could be evaluated macroscopically. Further study will be needed to confirm the usefulness of freezing preparation in autopsy investigation in many practical situations.

In the freezing group, depending on the putrefied brain or freezing effect, it is hard to extract the cerebellum in tandem with the cerebrum extraction. In that situation, an additional dissection should be considered within the cadaver cranium, such as separation at the level of cerebellar tentorium, and extraction of the cerebrum and cerebellum separately. Because the most interesting histopathological investigation specimen needs to be obtained as much as does the intact parenchyma, pre-autopsy planning is most important to achieve an ideal cause of death investigation. Thus, using postmortem CT prior the autopsy has an advantage for current cause of death investigation.

An intra-cranial lesion could be evaluated by imaging modalities, such as CT and MRI, even if the cadaver was in severe putrefaction. A general problem in PMCT and PMMRI of putrefied corpses seems to be the validation of possible relevant image findings at autopsy. This is due to loss of structural integrity after opening the skull, and the softened/liquefied brain tissue severely restrains any validation or confirmation by pathology [19]. But using this freezing method, the brain structural integrity remains, so that the surface macroscopic investigation is not difficult any more. In addition, the freezing brain parenchyma could be cut for macroscopic inspection in an ideal plane, so that the validation of possible relevant image findings can be evaluated without any difficulty macroscopically.

In this study, postmortem CT imaging was used to estimate degree of putrefaction and effectiveness of freezing technique. The intracranial free air was one of the key findings in putrefied brain, and the brain parenchymal structure could be used for either softened or liquefied brain parenchyma. The decreasing brain parenchymal density was used to assess the extent of freezing [11,15]. The postmortem CT was the basis examination before the autopsy to select the freezing technique.

There were some limitations. First, the postmortem image was necessary to detect the intra-cranial putrefied brain condition. But if the brain was expected to be in a putrefied condition, and the brain macroscopic investigation is mandatory, the freezing preparation poses no risk of loss of anatomical information. Therefore it could be used prior to the autopsy investigation. Second, we didn't evaluate the ideal duration time for freezing brain parenchyma. According to the animal experiment, at least 14 h prior the autopsy was required for freezing preparation [13]. If the preparation time for freezing the brain could be shortened, it would be of greater benefit and more convenient. If another material, such as liquid nitrogen [21] were used, it might help to decrease the freezing

preparation time. Third, there is no comparative evaluation for histopathological and/or immune-pathological effects in the case of putrefaction. The effects of postmortem period, degree of putrefaction, and freezing effect in histopathological and/or immune-pathological examination will need further investigations.

In conclusion, freezing procedures to evaluate the putrefied brain for macroscopic investigation have been reported, which could be statistically more useful in putrefied brain investigation than the ordinary procedure. Using freezing preparation techniques, a brain lesion could be evaluated and the adjunct tissue change could be demonstrated. Postmortem CT can be useful to evaluate not only the degree of brain putrefaction, but also the degree of freezing in brain parenchyma. The freezing technique may introduce an objective investigation of putrefied brain in autopsy investigation.

## Acknowledgements

We thank Hokkaido Prefectural Police, and especially Mr. Yasuhiko Sakaki, for their assistance with practical investigation. We thank Prof. Dr. Myles O'Brien (Mie Prefectural College of Nursing, Tsu, Mie, Japan) for assistance with English Language.

This study was supported by JSPS KAKENHI Grant-in-Aid for Scientific Research (C), Japan (Grant No. 16K10290).

## References

- [1] M.J. Thali, K. Yen, W. Schweitzer, P. Vock, C. Boesch, C. Ozdoba, et al., Virtopsy, a new imaging horizon in forensic pathology: virtual autopsy by postmortem multislice computed tomography (MSCT) and magnetic resonance imaging (MRI)—a feasibility study, *J. Forensic Sci.* 48 (2003) 386–403.
- [2] S. Shiotani, M. Kohno, N. Ohashi, K. Yamazaki, Y. Itai, Postmortem intravascular high-density fluid level (hypostasis): CT findings, *J. Comput. Assist. Tomogr.* 26 (2002) 892–893.
- [3] H. Hyodoh, S. Watanabe, R. Katada, K. Hyodoh, H. Matsumoto, Postmortem computed tomography lung findings in fatal of hypothermia, *Forensic Sci. Int.* 231 (2013) 190–194.
- [4] S.A. Bolliger, M.J. Thali, S. Ross, U. Buck, S. Naether, P. Vock, Virtual autopsy using imaging: bridging radiologic and forensic sciences. A review of the Virtopsy and similar projects, *Eur. Radiol.* 18 (2008) 273–282.
- [5] E. Aghayev, A. Christe, M. Sonnenschein, K. Yen, C. Jackowski, M.J. Thali, et al., Postmortem imaging of blunt chest trauma using CT and MRI: comparison with autopsy, *J. Thorac. Imaging* 23 (2008) 20–27.
- [6] K. Yen, P. Vock, B. Tiefenthaler, G. Ranner, E. Scheurer, M.J. Thali, et al., Virtopsy: forensic traumatology of the subcutaneous fatty tissue; multislice computed tomography (MSCT) and magnetic resonance imaging (MRI) as diagnostic tools, *J. Forensic Sci.* 49 (2004) 799–806.
- [7] T. Michiue, T. Ishikawa, S. Oritani, Y. Kamikodai, K. Tsuda, S. Okazaki, et al., Forensic pathological evaluation of postmortem pulmonary CT high-density areas in serial autopsy cases of sudden cardiac death, *Forensic Sci. Int.* 232 (2013) 199–205.
- [8] G. Inokuchi, D. Yajima, M. Hayakawa, A. Motomura, F. Chiba, S. Torimitsu, et al., The utility of postmortem computed tomography selective coronary angiography in parallel with autopsy, *Forensic Sci. Med. Pathol.* 9 (2013) 506–514.
- [9] B.V. Krentz, L. Alamo, J. Grimm, F. Dedouit, C. Bruguier, C. Chevallier, et al., Performance of post-mortem CT compared to autopsy in children, *Int. J. Legal Med.* 130 (2016) 1089–1099.
- [10] S.N. Staeheli, D. Gascho, J. Fornaro, P. Laberke, L.C. Ebert, R.M. Martinez, et al., Development of CT-guided biopsy sampling for time-dependent postmortem redistribution investigations in blood and alternative matrices—proof of concept and application on two cases, *Anal. Bioanal. Chem.* 408 (2016) 1249–1258.
- [11] H. Hyodoh, J. Shimizu, K. Mizuo, S. Okazaki, S. Watanabe, H. Inoue, CT-guided percutaneous needle placement in forensic medicine, *Leg. Med. (Tokyo)* 17 (2015) 79–81.
- [12] K. Watanabe, Y. Takahashi, R. Sano, T. Nakajima, Y. Kominato, S. Kobayashi, et al., Brain fragility can be estimated by its putrefactive signs on postmortem computed tomography, *Leg. Med. (Tokyo)* 17 (2015) 98–101.
- [13] H. Hyodoh, K. Matoba, M. Murakami, T. Matoba, A. Saito, F. Feng, et al., Experimental evaluation of freezing preparation for the macroscopic inspection in putrefied brain, *Leg. Med. (Tokyo)* 24 (2017) 19–23.
- [14] A.D. Levy, H.T. Harcke, C.T. Mallak, Postmortem imaging: MDCT features of postmortem change and decomposition, *Am. J. Forensic Med. Pathol.* 31 (2010) 12–17.
- [15] M. Sugimoto, H. Hyodoh, M. Rokukawa, A. Kanazawa, R. Murakami, J. Shimizu, et al., Freezing effect on brain density in postmortem CT, *Leg. Med. (Tokyo)* 18 (2016) 62–65.

- [16] H. Hyodoh, K. Ogura, M. Sugimoto, Y. Suzuki, A. Kanazawa, R. Murakami, et al., Frozen (iced) effect on postmortem CT – Experimental evaluation, *J. Forensic Radiol. Imaging* 3 (2015) 210–213.
- [17] J.M. MacKenzie, Examining the decomposed brain, *Am. J. Forensic Med. Pathol.* 35 (2014) 265–270.
- [18] Y. Takahashi, R. Sano, Y. Kominato, H. Takei, S. Kobayashi, T. Shimada, et al., Usefulness of postmortem computed tomography for demonstrating cerebral hemorrhage in a brain too fragile for macroscopic examination, *J. Forensic Radiol. Imaging* 1 (2013) 212–214.
- [19] J. Tschui, C. Jackowski, N. Schwendener, C. Schyma, W.D. Zech, Post-mortem CT and MR brain imaging of putrefied corpses, *Int. J. Leg. Med.* 130 (2016) 1061–1068.
- [20] F. Moriya, Y. Hashimoto, Postmortem production of ethanol and n-propanol in the brain of drowned persons, *Am. J. Forensic Med. Pathol.* 25 (2004) 131–133.
- [21] N. Tabata, M. Funayama, T. Ikeda, J. Azumi, M. Morita, On an accident by liquid nitrogen—histological changes of skin in cold, *Forensic Sci. Int.* 76 (1995) 61–67.