

Structural Loop Between the Cerebellum and the Superior Temporal Sulcus: Evidence from Diffusion Tensor Imaging

Arseny A. Sokolov^{1,2}, Michael Erb³, Wolfgang Grodd⁴ and Marina A. Pavlova^{1,5}

¹Developmental Cognitive and Social Neuroscience Unit, Department of Pediatric Neurology and Child Development, Children's Hospital, University of Tübingen Medical School, DE72076 Tübingen, Germany, ²Service de Neurologie and Laboratoire de Recherche en Neuroimagerie (LREN), Département des Neurosciences Cliniques, Centre Hospitalier Universitaire Vaudois (CHUV), CH1011 Lausanne, Switzerland, ³Department of Biomedical Magnetic Resonance, Department of Radiology, University of Tübingen Medical School, DE72076 Tübingen, Germany, ⁴Department of Psychiatry, Psychotherapy and Psychosomatics, University Hospital Aachen, DE52074 Aachen, Germany and ⁵Institute of Medical Psychology and Behavioral Neurobiology, MEG Center, University of Tübingen Medical School, DE72076 Tübingen, Germany

Address correspondence to Arseny A. Sokolov, University of Tübingen Medical School, Hoppe-Seyler-Strasse 3, DE72076 Tübingen, Germany. Email: arseny.sokolov@med.uni-tuebingen.de

The cerebellum is believed to play an essential role in a variety of motor and cognitive functions through reciprocal interaction with the cerebral cortex. Recent findings suggest that cerebellar involvement in the network specialized for visual body motion processing may be mediated through interaction with the right superior temporal sulcus (STS). Yet, the underlying pattern of structural connectivity between the STS and the cerebellum remains unidentified. In the present work, diffusion tensor imaging analysis on seeds derived from functional magnetic resonance imaging during a task on point-light biological motion perception uncovers a structural pathway between the right posterior STS and the left cerebellar lobule Crus I. The findings suggest existence of a structural loop underpinning bidirectional communication between the STS and cerebellum. This connection might also be of potential value for other visual social abilities.

Keywords: cerebellum, connectivity, diffusion tensor imaging, point-light biological motion, superior temporal sulcus

Introduction

Recent neuroimaging and lesion studies indicate cerebellar involvement not only in motor but also in a variety of cognitive functions (see [Strick et al. 2009](#) for review). Cerebellar engagement in cognitive processing has been shown to be mediated through bidirectional neuroanatomical connections with the frontal and parietal cortices ([Dum and Strick 2003](#)). Corresponding structural pathways are revealed by diffusion tensor imaging (DTI; [Salmi et al. 2010](#)). Cerebellar contribution has also been implicated in memory, auditory, and language functions, visual body motion and face perception, emotional processing, and social cognition (e.g., [Petersen et al. 1989](#); [Grossman et al. 2000](#); [Vaina et al. 2001](#); [Kilts et al. 2003](#); [Ohnishi et al. 2004](#); [Riecker et al. 2005](#); [Gobbini et al. 2007](#); [Stoodley and Schmahmann 2009](#); [Sokolov et al. 2010](#)). These cognitive functions are considered to be primarily hosted in the temporal lobe (e.g., [Scoville and Milner 1957](#); [Perrett et al. 1985](#); [Howard et al. 1996](#); [Gloor 1997](#); [Allison et al. 2000](#); [Grossman et al. 2000](#); [Vaina et al. 2001](#); [Beauchamp et al. 2004](#); [Ohnishi et al. 2004](#); [Pavlova et al. 2004](#); [Pelphrey et al. 2005](#); [Gobbini et al. 2007](#); [Saygin 2007](#); [Hein and Knight 2008](#); [Da Costa et al. 2011](#); [Herrington et al. 2011](#); [Krakowski et al. 2011](#)), and, in particular, the superior temporal sulcus (STS). Yet, possible connectivity paths between the cerebellum and temporal cortex remain largely unknown.

Resting-state functional connectivity magnetic resonance imaging (fcMRI) suggests that the cerebellum is connected to the superior temporal cortex ([O'Reilly et al. 2010](#); [Habas et al. 2011](#); [Dobromyslin et al. 2012](#)) and to the inferior and anterior temporal cortices ([Krienen and Buckner 2009](#); [Buckner et al. 2011](#)). By using dynamic causal modeling (DCM) in language and auditory domains ([Booth et al. 2007](#); [Pastor et al. 2008](#)) and psychophysiological interactions (PPI) analysis during imitation of finger movements ([Jack et al. 2011](#)), effective connectivity has been revealed between the cerebellum and several functional areas within the superior temporal cortex. The STS, predominantly in the right hemisphere, is considered a major hub within the cortical network underpinning visual social cognition and biological motion processing (e.g., [Bonda et al. 1996](#); [Allison et al. 2000](#); [Beauchamp et al. 2002](#); [Grossman and Blake 2002](#); [Pelphrey et al. 2003](#); [Puce and Perrett 2003](#); [Saygin et al. 2004](#); [Pavlova 2012](#)). In accord with neuroanatomical knowledge on contralateral connections between the cerebral cortices and cerebellar hemispheres (e.g., [Middleton and Strick 1994](#)), patients with lesions to the left lateral cerebellum exhibit deficient visual perception of body motion ([Sokolov et al. 2010](#)). As indicated by DCM, 2-way effective connectivity between the left cerebellar lobule Crus I and the right STS may subservise visual processing of point-light human locomotion ([Sokolov et al. 2012](#)). Resting-state and task-dependent fcMRI represent correlation analyses on time courses of activity in different brain regions that are aimed at identifying specific functional networks ([Kleinschmidt et al. 1994](#); [Biswal et al. 1995](#); [Raichle et al. 2001](#); [Fox and Raichle 2007](#)). However, resulting correlations may also reflect similar, but not necessarily interconnected activity. Effective connectivity methods, such as PPI and DCM, analyze experimentally induced changes in coupling between regions in task-related imaging data ([Friston et al. 1997, 2003](#)). In particular, DCM reveals intrinsic connectivity between brain areas, direction of communication, and task-specific modulation within a network ([Friston et al. 2003](#)). Yet, it cannot be excluded that remote brain regions may mediate communication revealed through effective or functional connectivity analyses. The existence of structural pathways between brain areas exhibiting functional or effective connectivity therefore substantially reinforces concepts of direct interaction. Possible structural connections underlying

communication between the STS and cerebellum have not yet been identified.

Neuroanatomical findings in nonhuman primates suggest the existence of projections from the STS to the pons (Brodal 1978; Glickstein et al. 1985, 1994; Schmammann and Pandya 1991) and from the pons to the cerebellum (Brodal 1979; Glickstein et al. 1994). DTI, based on detection of more homogeneous diffusion of water molecules along structures such as white matter tracts (e.g., Basser et al. 1994; Mori et al. 2002), is currently the only technique for *in vivo* studying structural connectivity in humans. Despite DTI data on existence of parieto- and fronto-cerebellar structural loops (Salimi et al. 2010), there has been no experimental evidence in regard to possible reciprocal pathways between the temporal cortex and cerebellum. By using high-resolution DTI in combination with functional magnetic resonance imaging (fMRI) during performance of a task on visual perception of point-light biological motion, the present work intends to clarify whether a structural pathway underpins effective and functional connectivity between the left cerebellum and the right STS.

Materials and Methods

Participants

Sixteen healthy, right-handed, male volunteers (mean age 26.8 ± 3.5 years) with normal or corrected-to-normal vision, without history of neurological or psychiatric disorders, head injuries, or medication for anxiety or depression participated. Part of the group was involved in a previous study (Sokolov et al. 2012). Informed written consent was obtained in accordance with the requirements of the local ethical committee of the University of Tübingen Medical School.

MRI Acquisition and Stimuli

A 3-T scanner (TimTrio, Siemens Medical Solutions, Erlangen, Germany; 12-channel head coil) was used for MRI recording. As anatomical reference, a 3-dimensional (3-D) T_1 -weighted magnetization-prepared rapid gradient-echo imaging (MPRAGE) data set (176 sagittal slices, repetition time [TR]=2300, echo time [TE]=2.92, inversion time [TI]=1100 ms, voxel size = $1 \times 1 \times 1$ mm³) was obtained at the beginning of the scanning session. For later correction of magnetic field inhomogeneity, a field map was recorded. During task performance, we acquired echo-planar imaging (EPI) sequences (210 volumes, 36 axial slices, TR=2500 ms, TE=35 ms, in-plane resolution 3×3 mm², slice thickness=3 mm, with 1 mm gap). Participants performed a one-back repetition task with a total of 100 biological motion animations (equal number of either a point-light walker or its spatially scrambled version) that were computer generated by using Cutting's algorithm (Cutting 1978). Immediate repetitions of each type of stimulus were indicated by pressing a button with the right index finger during the rest period between stimulus presentations. The canonical biological motion stimulus consisted of 11 bright point-lights positioned on the main joints and head of an otherwise unseen human figure walking without net translation and facing right. With frame duration of 20 ms and a gait cycle completed within 62 frames, walking speed was about 48 cycles per minute. The scrambled stimulus was created by modification of spatial dot positions, while the motion of each dot remained the same. Stimuli were presented for 1000 ms each and displayed by using the software Presentation (Neurobehavioral Systems, Inc., Albany, CA, USA). The design was event related, with total session duration of 525 s, including 5 blocks with a duration of 75 s each and 6 baseline epochs (25 s each). Each block comprised 20 stimuli (10 canonical and 10 scrambled) in a pseudorandomized order. The periods between stimuli onset were jittered in steps of 500 ms between 2500 and 5000 ms. Stimuli, task,

and experimental design are described in more detail elsewhere (Sokolov et al. 2012).

An optimized diffusion-sensitized spin EPI with isotropic resolution (54 axial slices, TR=7800 ms, TE=108 ms, slice thickness=2.5 mm, matrix size=88×88, field of view=216 mm) was used for acquisition of diffusion-weighted images. A diffusion-weighted imaging session contained one volume without diffusion sensitization (b -value=0 s/mm²) and 64 volumes with different diffusion gradient directions (b -value=2600 s/mm²). Per participant, 2 diffusion-imaging sessions were run resulting in 130 individual images; this improves both consistency and sensitivity of diffusion parameter estimation.

fMRI Data Processing

Statistical Parametric Mapping (SPM8, Wellcome Institute of Cognitive Neuroscience, London, UK, <http://www.fil.ion.ucl.ac.uk/spm>) in Matlab R2008b (MathWorks, Inc., Sherborn, MA, USA) was used for processing of fMRI data to identify seeds for probabilistic tractography. Details on fMRI data preprocessing are described elsewhere (Sokolov et al. 2012). In summary, standard SPM slice timing and realignment corrections, as well as segmentation were conducted prior to normalization of the images to MNI space. Statistical analysis based on a general linear model was run on the resulting individual fMRI data. The individual whole-brain images for the contrast canonical versus scrambled biological motion were included in a second-level random effects whole-brain analysis. Individual activation clusters (threshold $P < 0.001$, uncorrected) located closest to the corresponding group maxima in the left cerebellar Crus I and the right posterior STS were extracted and served as seeds for subsequent probabilistic tractography. Both regions of interest could be identified in each data set. Anatomical sites of the individual clusters were confirmed by using automated anatomical labeling (Tzourio-Mazoyer et al. 2002) that included a 3-D MRI human cerebellar parcellation (Schmahmann et al. 1999). MNI coordinates were converted into Talairach space by use of the icbm2tal transform (Lancaster et al. 2007).

DTI Data Processing

The processing of DTI data was conducted by using the FMRIB Software Library (FSL4, Oxford Centre for Functional MRI of the Brain, UK, <http://www.fmrib.ox.ac.uk/fsl>). Initially, to remove voxels located outside the brain, the Brain Extraction Tool (Smith 2002) was applied to the T_1 -weighted anatomical reference image and a volume without diffusion sensitization. Motion and eddy current correction, coregistration of diffusion-weighted images with the anatomical reference image, and alignment of the diffusion-weighted and anatomical images to the MNI space were performed using the FMRIB Linear Image Registration Tool (FLIRT; Jenkinson et al. 2002). Gradient directions were adjusted accordingly following each FLIRT step. Running Bayesian Estimation of Diffusion Parameters Obtained using Sampling Techniques with modelling of Crossing Fibres (BEDPOSTX; Behrens et al. 2007) on each individual normalized data set provided the diffusion parameters for each voxel.

Probabilistic tractography (step length=0.5 mm, number of steps=2000, number of pathways=5000, curvature threshold=0.2) with modified Euler integration providing for higher tracking accuracy was performed on the individual BEDPOSTX outputs. Only streamlines passing through both the Crus I and STS seeds were retained. Individual tractography outputs were thresholded at 5% of the robust intensity range (corresponding to a 95% confidence interval). Two participants did not exhibit significant connectivity maps and were excluded from group analysis. To assess overlaps in tract topography and interindividual variability, the individual maps were converted to binary maps (voxel value=1 for streamlines passing through this voxel) and, subsequently, mathematically averaged to create a group variability map (Ciccarelli et al. 2003).

Results

We conducted probabilistic DTI tractography between 2 seeds, one in the right STS (Talairach coordinates of the group

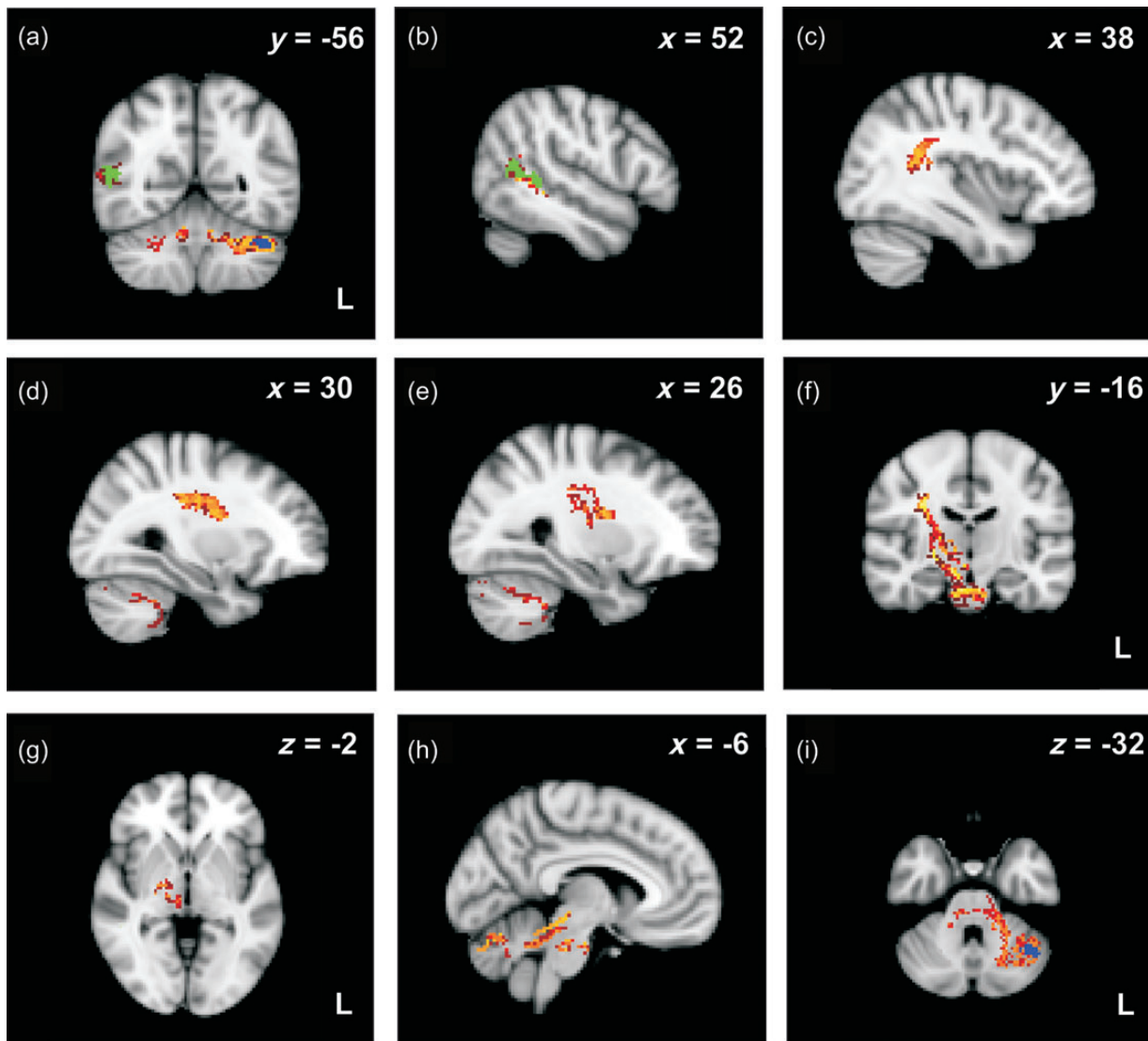


Figure 1. Group variability map of probabilistic tractography on individual seeds in (a) the right superior temporal sulcus (STS; green cluster) and the left lateral cerebellar lobule Crus I (blue cluster); for both seeds, group clusters are displayed. Some fibers connect the right STS with the ipsilateral cerebellum. The fiber tracts leave (b) the right STS cluster (green) along (c) the superior longitudinal fascicles II and IV. (d) They turn caudally and (e) split into an anterior and a posterior portion that further caudally form (f) a more lateral and a more medial pathway. (g) The anterior, caudally more lateral fibers join the corticopontine tract in the posterior crus of the internal capsule, whereas the posterior, caudally more medial pathway passes through the thalamus and, thus, can be attributed to the dentato-rubro-thalamo-cortical tract. (h) The fiber tract passing through the left superior cerebellar peduncle form the cerebello-temporal pathway. (i) Fibers crossing to the left in the pons, passing through the left medial cerebellar peduncle and reaching the left cerebellar lobule Crus I (blue) belong to the temporo-cerebellar pathway. Image orientation according to radiological convention. Slice position indicated in upper right corner. Fiber tracts and seed regions overlaid on the brain-extracted MNI standard space template provided within FSL.

cluster: $x = 52, y = -54, z = 8$) and another in the left lateral cerebellar lobule Crus I ($x = -39, y = -56, z = -30$), that were identified in a whole-brain analysis of fMRI data obtained during biological motion processing (Fig. 1). Regions in the right STS and the left cerebellar lobule Crus I have been previously reported to be active and to effectively communicate with each other during visual processing of point-light biological motion (Sokolov et al. 2012). Individual probabilistic tractography data (at a 95% confidence interval) and the group variability map indicate 2 pathways forming a structural loop between the right STS and the left Crus I (Fig. 1). A representative individual 3D reconstruction is shown in Figure 2.

The 2 fiber tracts pass distinct landmarks between the right STS and left cerebellum, such as the thalamus, pons, and medial or superior cerebellar peduncles. One fiber tract

passes more anteriorly through the posterior limb of the right internal capsule and through the pons where the fibers cross to the left medial cerebellar peduncle. The other pathway passes through the left dentate nucleus, the left superior cerebellar peduncle and, having crossed into the right cerebral peduncle, through the right thalamus, and then through a more posterior portion of the posterior limb of the internal capsule. Both fiber tracts merge further cephaladly and turn to the right posterior superior temporal cortex. In agreement with earlier data (Makris et al. 2005), these white matter tracts correspond to the right superior longitudinal fascicles II and IV. Some fibers also connect the right STS with ipsilateral cerebellum. The group variability map (based on binary individual structural connectivity maps thresholded at 5% of the robust intensity range that corresponds to a 95% confidence

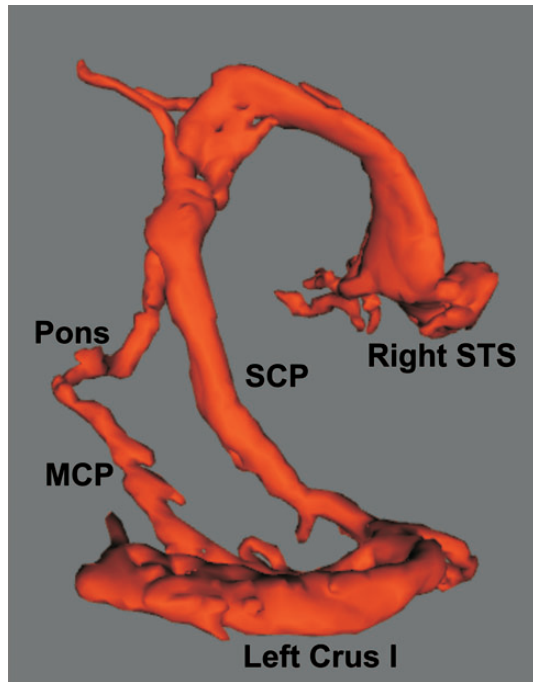


Figure 2. 3-D reconstruction of the structural loop between the right superior temporal sulcus (STS) and the left lateral cerebellar lobule Crus I in a representative individual. SCP: superior cerebellar peduncle; MCP: medial cerebellar peduncle.

interval) indicates a high degree of overlap in interindividual tract topography (Fig. 1).

Discussion

By combining DTI with fMRI analysis, the present work reveals structural connections between the STS and cerebellum, offering novel insights into understanding of cerebro-cerebellar connectivity. Originating in the STS and Crus I seeds, the pathways pass along midbrain and diencephalic landmarks for cerebro-cerebellar connections known from previous neuroanatomical and DTI studies (e.g., Brodal 1978, 1979; Glickstein et al. 1985, 1994; Schmahmann and Pandya 1991; Dum and Strick 2003; Evrard and Craig 2008; Salmi et al. 2010). This suggests anatomical plausibility of the DTI findings and, in conjunction with previous neuroanatomical knowledge on connectivity patterns between the cerebellum and cerebral cortex (e.g. Brodal 1975; Nieuwenhuys et al. 1991; Strick et al. 2009), allows for repartition of the structural connection into a cortico-cerebellar pathway (those fibers passing the pons and medial cerebellar peduncle) and a cerebello-cortical tract (those fibers passing the superior cerebellar peduncle and thalamus). Although previous work points to a high degree of correspondence between DTI and neuroanatomical data (Johansen-Berg et al. 2005), future neuroanatomical studies are required to confirm this outcome.

The cerebral cortex and the cerebellum are thought to communicate through closed loops: An area in the cerebral cortex projecting to a cerebellar region receives input from this same region (Kelly and Strick 2003; Salmi et al. 2010). The present findings extend previous data inasmuch as they suggest the existence of 2-way structural connections between the

temporal cortex and cerebellum. Previous DTI analysis within the cerebral peduncle primarily aimed at exploring prefrontal inputs to the cerebellum yielded disproportional connections from the temporal lobe (Ramnani et al. 2006). However, because of presumably high tract curvature and various intersections, cerebello-temporal connections may be more difficult to detect than other cerebro-cerebellar pathways. High-resolution DTI sequences and optimized processing methods used in the present study allow for enhanced analysis on intersections and direction changes within and between voxels. Acquisition of 2 data sets per participant further contributes to improving both sensitivity and consistency of diffusion parameter estimation.

Resting-state functional connectivity has been reported between the temporal cortex and cerebellum (Krienen and Buckner 2009; O'Reilly et al. 2010; Buckner et al. 2011; Habas et al. 2011; Dobromylin et al. 2012). However, due to narrow neuroanatomical evidence in regard to possible underlying structural connectivity and intrinsic limitations of functional connectivity analyses, this communication has been considered to be mediated by the posterior parietal cortex and inferior parietal lobule (Gazzola and Keysers 2009; Krienen and Buckner 2009). The present DTI findings suggest existence of a direct structural pathway that may subserve communication between the STS and cerebellum.

The right temporal cortex, and, in particular, the right STS is engaged in visual body motion processing (e.g., Perrett et al. 1985; Bonda et al. 1996; Beauchamp et al. 2002; Grossman and Blake 2002; Pelphrey et al. 2003; Puce and Perrett 2003; Saygin et al. 2004). The present DTI findings based on task-specific seeds derived from analysis of fMRI data during observation of human locomotion may not only provide a possible structural correlate for interaction between the left cerebellum and the right STS during biological motion processing (Sokolov et al. 2012), but also for functional crosstalk between the cerebellum and STS in audiovisual integration (Baumann and Greenlee 2007; Baumann and Mattingley 2010; Petrini et al. 2011), imitation of body motion (Jack et al. 2011), observation of goal-directed hand movements (Gazzola and Keysers 2009; Turella et al. 2012), and visual social cognition (Ohnishi et al. 2004; Gobbini et al. 2007). Both biological motion and Heider-and-Simmel animations, consisting of moving geometric shapes that convey the impression of social interaction, elicit overlapping activations in the STS and lateral cerebellum (Gobbini et al. 2007). Another fMRI study also showed activation in the right STS and the left lateral cerebellum related to Heider-and-Simmel animations (Ohnishi et al. 2004). A similar contralateral structural connectivity pattern with a loop between the right cerebellum and the left temporal cortex could underpin cerebellar engagement in language processing (Petersen et al. 1989; Raichle et al. 1994; Riecker et al. 2005, 2006; Ackermann et al. 2007). Effective connectivity has already been reported between the right medial cerebellum and left middle and superior temporal cortices during a rhyming judgment task (Booth et al. 2007).

Social impairment and alterations in biological motion perception are intertwined in patients with autistic spectrum disorders and schizophrenia (Blake et al. 2003; Kim et al. 2005; Klin et al. 2009; Koldewyn et al. 2010, 2011; Nackaerts et al. 2012; Pavlova 2012). Moreover, in these conditions, abnormal structural connectivity parameters have been reported in the cerebellar tracts (Kanaan et al. 2009; Sivaswamy et al. 2010)

and the temporal white matter (Barnea-Goraly et al. 2004; Lee et al. 2007; Schlösser et al. 2007). The only significant interaction in a correlation analysis between diffusion anisotropy (as a parameter for fiber pathway integrity) and social impairment in children with Asperger syndrome was found for the left superior cerebellar peduncle (Catani et al. 2008), which is the main conduit for information flow from the left cerebellum to the right cerebral cortex. As suggested by the present data, the left superior cerebellar peduncle might also contain fibers reaching the right STS. This study thereby promotes further investigation of associations between disintegration of cerebro-cerebellar networks and social cognition. Taken together, the evidence for a structural loop between the left cerebellum and the right STS may stimulate future research on the role of temporo-cerebello-temporal interactions for higher cognitive processing in typical and atypical development.

Funding

This work was supported by research grants from the Else Kröner Fresenius Foundation (P63/2008 and P2010_92), the Werner Reichardt Centre for Integrative Neuroscience (CIN project 2009_24) and the Reinhold Beitlich Foundation to M.A.P.

Notes

We thank Vinod Kumar and Sarah Mang for advice on data acquisition and preprocessing. We are grateful to Bernd Kardatzki for technical support and to Franziska Hösl, Albertine Stiens, and Cornelia Veil for assistance with MRI scanning. *Conflict of Interest:* None declared.

References

Ackermann H, Mathiak K, Riecker A. 2007. The contribution of the cerebellum to speech production and speech perception: clinical and functional imaging data. *Cerebellum*. 6:202–213.

Allison T, Puce A, McCarthy G. 2000. Social perception from visual cues: role of the STS region. *Trends Cogn Sci*. 4:267–278.

Barnea-Goraly N, Kwon H, Menon V, Eliez S, Lotspeich L, Reiss AL. 2004. White matter structure in autism: preliminary evidence from diffusion tensor imaging. *Biol Psychiatry*. 55:323–326.

Basser PJ, Mattiello J, LeBihan D. 1994. MR diffusion tensor spectroscopy and imaging. *Biophys J*. 66:259–267.

Baumann O, Greenlee MW. 2007. Neural correlates of coherent audio-visual motion perception. *Cereb Cortex*. 17:1433–1443.

Baumann O, Mattingley JB. 2010. Scaling of neural responses to visual and auditory motion in the human cerebellum. *J Neurosci*. 30:4489–4495.

Beauchamp MS, Argall BD, Bodurka J, Duyn JH, Martin A. 2004. Unraveling multisensory integration: patchy organization within human STS multisensory cortex. *Nat Neurosci*. 7:1190–1192.

Beauchamp MS, Lee KE, Haxby JV, Martin A. 2002. Parallel visual motion processing streams for manipulable objects and human movements. *Neuron*. 34:149–159.

Behrens TE, Berg HJ, Jbabdi S, Rushworth MF, Woolrich MW. 2007. Probabilistic diffusion tractography with multiple fibre orientations: what can we gain? *Neuroimage*. 34:144–155.

Biswal B, Yetkin FZ, Haughton VM, Hyde JS. 1995. Functional connectivity in the motor cortex of resting human brain using echo-planar MRI. *Magn Reson Med*. 34:537–541.

Blake R, Turner LM, Smoski MJ, Pozdol SL, Stone WL. 2003. Visual recognition of biological motion is impaired in children with autism. *Psychol Sci*. 14:151–157.

Bonda E, Petrides M, Ostry D, Evans A. 1996. Specific involvement of human parietal systems and the amygdala in the perception of biological motion. *J Neurosci*. 16:3737–3744.

Booth JR, Wood L, Lu D, Houk JC, Bitan T. 2007. The role of the basal ganglia and cerebellum in language processing. *Brain Res*. 1133:136–144.

Brodal A. 1975. Proceedings: what does the anatomical organization of the cerebrocerebellar connections tell us about their function and clinical importance. *Acta Neurochir (Wien)*. 31:265.

Brodal P. 1978. The corticopontine projection in the rhesus monkey. Origin and principles of organization. *Brain*. 101:251–283.

Brodal P. 1979. The pontocerebellar projection in the rhesus monkey: an experimental study with retrograde axonal transport of horseradish peroxidase. *Neuroscience*. 4:193–208.

Buckner RL, Krienen FM, Castellanos A, Diaz JC, Yeo BT. 2011. The organization of the human cerebellum estimated by intrinsic functional connectivity. *J Neurophysiol*. 106:2322–2345.

Catani M, Jones DK, Daly E, Embiricos N, Deeley Q, Pugliese L, Curran S, Robertson D, Murphy DG. 2008. Altered cerebellar feedback projections in Asperger syndrome. *Neuroimage*. 41:1184–1191.

Ciccarelli O, Parker GJ, Toosy AT, Wheeler-Kingshott CA, Barker GJ, Boulby PA, Miller DH, Thompson AJ. 2003. From diffusion tractography to quantitative white matter tract measures: a reproducibility study. *Neuroimage*. 18:348–359.

Cutting JE. 1978. Generation of synthetic male and female walkers through manipulation of a biomechanical invariant. *Perception*. 7:393–405.

Da Costa S, van der Zwaag W, Marques JP, Frackowiak RS, Clarke S, Saenz M. 2011. Human primary auditory cortex follows the shape of Heschl's gyrus. *J Neurosci*. 31:14067–14075.

Dobromylin VI, Salat DH, Fortier CB, Leritz EC, Beckmann CF, Milberg WP, McGlinchey RE. 2012. Distinct functional networks within the cerebellum and their relation to cortical systems assessed with independent component analysis. *Neuroimage*. 60:2073–2085.

Dum RP, Strick PL. 2003. An unfolded map of the cerebellar dentate nucleus and its projections to the cerebral cortex. *J Neurophysiol*. 89:634–639.

Evrard HC, Craig AD. 2008. Retrograde analysis of the cerebellar projections to the posteroventral part of the ventral lateral thalamic nucleus in the macaque monkey. *J Comp Neurol*. 508:286–314.

Fox MD, Raichle ME. 2007. Spontaneous fluctuations in brain activity observed with functional magnetic resonance imaging. *Nat Rev Neurosci*. 8:700–711.

Friston KJ, Buechel C, Fink GR, Morris J, Rolls E, Dolan RJ. 1997. Psychophysiological and modulatory interactions in neuroimaging. *Neuroimage*. 6:218–229.

Friston KJ, Harrison L, Penny W. 2003. Dynamic causal modelling. *Neuroimage*. 19:1273–1302.

Gazzola V, Keysers C. 2009. The observation and execution of actions share motor and somatosensory voxels in all tested subjects: single-subject analyses of unsmoothed fMRI data. *Cereb Cortex*. 19:1239–1255.

Glickstein M, Gerrits N, Kralj-Hans I, Mercier B, Stein J, Voogd J. 1994. Visual pontocerebellar projections in the macaque. *J Comp Neurol*. 349:51–72.

Glickstein M, May JG 3rd, Mercier BE. 1985. Corticopontine projection in the macaque: the distribution of labelled cortical cells after large injections of horseradish peroxidase in the pontine nuclei. *J Comp Neurol*. 235:343–359.

Gloor P. 1997. The temporal lobe and limbic system. New York (NY): Oxford University Press.

Gobbini MI, Koralek AC, Bryan RE, Montgomery KJ, Haxby JV. 2007. Two takes on the social brain: a comparison of theory of mind tasks. *J Cogn Neurosci*. 19:1803–1814.

Grossman E, Donnelly M, Price R, Pickens D, Morgan V, Neighbor G, Blake R. 2000. Brain areas involved in perception of biological motion. *J Cogn Neurosci*. 12:711–720.

Grossman ED, Blake R. 2002. Brain areas active during visual perception of biological motion. *Neuron*. 35:1167–1175.

- Habas C, Guillevin R, Abanou A. 2011. Functional connectivity of the superior human temporal sulcus in the brain resting state at 3T. *Neuroradiology*. 53:129–140.
- Hein G, Knight RT. 2008. Superior temporal sulcus—it's my area: or is it? *J Cogn Neurosci*. 20:2125–2136.
- Herrington JD, Nymberg C, Schultz RT. 2011. Biological motion task performance predicts superior temporal sulcus activity. *Brain Cogn*. 77:372–381.
- Howard RJ, Brammer M, Wright I, Woodruff PW, Bullmore ET, Zeki S. 1996. A direct demonstration of functional specialization within motion-related visual and auditory cortex of the human brain. *Curr Biol*. 6:1015–1019.
- Jack A, Englander ZA, Morris JP. 2011. Subcortical contributions to effective connectivity in brain networks supporting imitation. *Neuropsychologia*. 49:3689–3698.
- Jenkinson M, Bannister P, Brady M, Smith S. 2002. Improved optimization for the robust and accurate linear registration and motion correction of brain images. *Neuroimage*. 17:825–841.
- Johansen-Berg H, Behrens TE, Sillery E, Ciccarelli O, Thompson AJ, Smith SM, Matthews PM. 2005. Functional-anatomical validation and individual variation of diffusion tractography-based segmentation of the human thalamus. *Cereb Cortex*. 15:31–39.
- Kanaan RA, Borgwardt S, McGuire PK, Craig MC, Murphy DG, Picchioni M, Shergill SS, Jones DK, Catani M. 2009. Microstructural organization of cerebellar tracts in schizophrenia. *Biol Psychiatry*. 66:1067–1069.
- Kelly RM, Strick PL. 2003. Cerebellar loops with motor cortex and prefrontal cortex of a nonhuman primate. *J Neurosci*. 23:8432–8444.
- Kilts CD, Egan G, Gideon DA, Ely TD, Hoffman JM. 2003. Dissociable neural pathways are involved in the recognition of emotion in static and dynamic facial expressions. *Neuroimage*. 18:156–168.
- Kim J, Doop ML, Blake R, Park S. 2005. Impaired visual recognition of biological motion in schizophrenia. *Schizophr Res*. 77:299–307.
- Kleinschmidt A, Merboldt KD, Hancic W, Steinmetz H, Frahm J. 1994. Correlational imaging of thalamocortical coupling in the primary visual pathway of the human brain. *J Cereb Blood Flow Metab*. 14:952–957.
- Klin A, Lin DJ, Gorrindo P, Ramsay G, Jones W. 2009. Two-year-olds with autism orient to non-social contingencies rather than biological motion. *Nature*. 459:257–261.
- Koldewyn K, Whitney D, Rivera SM. 2011. Neural correlates of coherent and biological motion perception in autism. *Dev Sci*. 14:1075–1088.
- Koldewyn K, Whitney D, Rivera SM. 2010. The psychophysics of visual motion and global form processing in autism. *Brain*. 133:599–610.
- Krakowski AI, Ross LA, Snyder AC, Sehatpour P, Kelly SP, Foxe JJ. 2011. The neurophysiology of human biological motion processing: a high-density electrical mapping study. *Neuroimage*. 56:373–383.
- Krienen FM, Buckner RL. 2009. Segregated fronto-cerebellar circuits revealed by intrinsic functional connectivity. *Cereb Cortex*. 19:2485–2497.
- Lancaster JL, Tordesillas-Gutierrez D, Martinez M, Salinas F, Evans A, Zilles K, Mazziotta JC, Fox PT. 2007. Bias between MNI and Talairach coordinates analyzed using the ICBM-152 brain template. *Hum Brain Mapp*. 28:1194–1205.
- Lee JE, Bigler ED, Alexander AL, Lazar M, DuBray MB, Chung MK, Johnson M, Morgan J, Miller JN, McMahon WM et al. 2007. Diffusion tensor imaging of white matter in the superior temporal gyrus and temporal stem in autism. *Neurosci Lett*. 424:127–132.
- Makris N, Kennedy DN, McInerney S, Sorensen AG, Wang R, Caviness VS Jr, Pandya DN. 2005. Segmentation of subcomponents within the superior longitudinal fascicle in humans: a quantitative, in vivo, DT-MRI study. *Cereb Cortex*. 15:854–869.
- Middleton FA, Strick PL. 1994. Anatomical evidence for cerebellar and basal ganglia involvement in higher cognitive function. *Science*. 266:458–461.
- Mori S, Kaufmann WE, Davatzikos C, Stieltjes B, Amodei L, Fredericksen K, Pearlson GD, Melhem ER, Solaiyappan M, Raymond GV et al. 2002. Imaging cortical association tracts in the human brain using diffusion-tensor-based axonal tracking. *Magn Reson Med*. 47:215–223.
- Nackaerts E, Wagemans J, Helsen W, Swinnen SP, Wenderoth N, Alaerts K. 2012. Recognizing biological motion and emotions from point-light displays in autism spectrum disorders. *PLoS One*. 7:e44473.
- Nieuwenhuys R, Voogd J, van Huijzen C. 1991. *Das Zentralnervensystem des Menschen*. Berlin: Springer.
- Ohnishi T, Moriguchi Y, Matsuda H, Mori T, Hirakata M, Imabayashi E, Hirao K, Nemoto K, Kaga M, Inagaki M et al. 2004. The neural network for the mirror system and mentalizing in normally developed children: an fMRI study. *Neuroreport*. 15:1483–1487.
- O'Reilly JX, Beckmann CF, Tomassini V, Ramnani N, Johansen-Berg H. 2010. Distinct and overlapping functional zones in the cerebellum defined by resting state functional connectivity. *Cereb Cortex*. 20:953–965.
- Pastor MA, Vidaurre C, Fernandez-Seara MA, Villanueva A, Friston KJ. 2008. Frequency-specific coupling in the cortico-cerebellar auditory system. *J Neurophysiol*. 100:1699–1705.
- Pavlova M, Lutzenberger W, Sokolov A, Birbaumer N. 2004. Dissociable cortical processing of recognizable and non-recognizable biological movement: analysing gamma MEG activity. *Cereb Cortex*. 14:181–188.
- Pavlova MA. 2012. Biological motion processing as a hallmark of social cognition. *Cereb Cortex*. 22:981–995.
- Pelphrey KA, Mitchell TV, McKeown MJ, Goldstein J, Allison T, McCarthy G. 2003. Brain activity evoked by the perception of human walking: controlling for meaningful coherent motion. *J Neurosci*. 23:6819–6825.
- Pelphrey KA, Morris JP, Michelich CR, Allison T, McCarthy G. 2005. Functional anatomy of biological motion perception in posterior temporal cortex: an FMRI study of eye, mouth and hand movements. *Cereb Cortex*. 15:1866–1876.
- Perrett DI, Smith PA, Mistlin AJ, Chitty AJ, Head AS, Potter DD, Broennimann R, Milner AD, Jeeves MA. 1985. Visual analysis of body movements by neurones in the temporal cortex of the macaque monkey: a preliminary report. *Behav Brain Res*. 16:153–170.
- Petersen SE, Fox PT, Posner MI, Mintun M, Raichle ME. 1989. Positron emission tomographic studies of the processing of single words. *J Cogn Neurosci*. 1:153–170.
- Petrini K, Pollick FE, Dahl S, McAleer P, McKay L, Rocchesso D, Wadelland CH, Love S, Avanzini F, Puce A. 2011. Action expertise reduces brain activity for audiovisual matching actions: an fMRI study with expert drummers. *Neuroimage*. 56:1480–1492.
- Puce A, Perrett D. 2003. Electrophysiology and brain imaging of biological motion. *Phil Trans R Soc B*. 358:435–445.
- Raichle ME, Fiez JA, Videen TO, MacLeod AM, Pardo JV, Fox PT, Petersen SE. 1994. Practice-related changes in human brain functional anatomy during nonmotor learning. *Cereb Cortex*. 4:8–26.
- Raichle ME, MacLeod AM, Snyder AZ, Powers WJ, Gusnard DA, Shulman GL. 2001. A default mode of brain function. *Proc Natl Acad Sci USA*. 98:676–682.
- Ramnani N, Behrens TE, Johansen-Berg H, Richter MC, Pinski MA, Andersson JL, Rudebeck P, Ciccarelli O, Richter W, Thompson AJ et al. 2006. The evolution of prefrontal inputs to the cortico-pontine system: diffusion imaging evidence from Macaque monkeys and humans. *Cereb Cortex*. 16:811–818.
- Riecker A, Kassubek J, Groschel K, Grodd W, Ackermann H. 2006. The cerebral control of speech tempo: opposite relationship between speaking rate and BOLD signal changes at striatal and cerebellar structures. *Neuroimage*. 29:46–53.
- Riecker A, Mathiak K, Wildgruber D, Erb M, Hertrich I, Grodd W, Ackermann H. 2005. fMRI reveals two distinct cerebral networks subserving speech motor control. *Neurology*. 64:700–706.
- Salmi J, Pallesen KJ, Neuvonen T, Brattico E, Korvenoja A, Salonen O, Carlson S. 2010. Cognitive and motor loops of the human cerebro-cerebellar system. *J Cogn Neurosci*. 22:2663–2676.
- Saygin AP. 2007. Superior temporal and premotor brain areas necessary for biological motion perception. *Brain*. 130:2452–2461.

- Saygin AP, Wilson SM, Hagler DJ Jr, Bates E, Sereno MI. 2004. Point-light biological motion perception activates human premotor cortex. *J Neurosci*. 24:6181–6188.
- Schlösser RG, Nenadic I, Wagner G, Gullmar D, von Consbruch K, Kohler S, Schultz CC, Koch K, Fitzek C, Matthews PM et al. 2007. White matter abnormalities and brain activation in schizophrenia: a combined DTI and fMRI study. *Schizophr Res*. 89:1–11.
- Schmahmann JD, Doyon J, McDonald D, Holmes C, Lavoie K, Hurwitz AS, Kabani N, Toga A, Evans A, Petrides M. 1999. Three-dimensional MRI atlas of the human cerebellum in proportional stereotaxic space. *Neuroimage*. 10:233–260.
- Schmahmann JD, Pandya DN. 1991. Projections to the basis pontis from the superior temporal sulcus and superior temporal region in the rhesus monkey. *J Comp Neurol*. 308:224–248.
- Scoville WB, Milner B. 1957. Loss of recent memory after bilateral hippocampal lesions. *J Neurol Neurosurg Psychiatry*. 20:11–21.
- Sivaswamy L, Kumar A, Rajan D, Behen M, Muzik O, Chugani D, Chugani H. 2010. A diffusion tensor imaging study of the cerebellar pathways in children with autism spectrum disorder. *J Child Neurol*. 25:1223–1231.
- Smith SM. 2002. Fast robust automated brain extraction. *Hum Brain Mapp*. 17:143–155.
- Sokolov AA, Erb M, Gharabaghi A, Grodd W, Tatagiba MS, Pavlova MA. 2012. Biological motion processing: the left cerebellum communicates with the right superior temporal sulcus. *Neuroimage*. 59:2824–2830.
- Sokolov AA, Gharabaghi A, Tatagiba MS, Pavlova M. 2010. Cerebellar engagement in an action observation network. *Cereb Cortex*. 20:486–491.
- Stoodley CJ, Schmahmann JD. 2009. Functional topography in the human cerebellum: a meta-analysis of neuroimaging studies. *Neuroimage*. 44:489–501.
- Strick PL, Dum RP, Fiez JA. 2009. Cerebellum and nonmotor function. *Annu Rev Neurosci*. 32:413–434.
- Turella L, Tubaldi F, Erb M, Grodd W, Castiello U. 2012. Object presence modulates activity within the somatosensory component of the action observation network. *Cereb Cortex*. 22:668–679.
- Tzourio-Mazoyer N, Landeau B, Papathanassiou D, Crivello F, Etard O, Delcroix N, Mazoyer B, Joliot M. 2002. Automated anatomical labeling of activations in SPM using a macroscopic anatomical parcellation of the MNI MRI single-subject brain. *Neuroimage*. 15:273–289.
- Vaina LM, Solomon J, Chowdhury S, Sinha P, Belliveau JW. 2001. Functional neuroanatomy of biological motion perception in humans. *Proc Natl Acad Sci USA*. 98:11656–11661.