

## RHABDOMYOLYSIS INDUCED BY ANAESTHESIA WITH INTRAOPERATIVE CARDIAC ARREST

H. SCHAER, B. STEINMANN, S. JERUSALEM AND C. MAIER

### SUMMARY

A 9-year-old boy undergoing anaesthesia including suxamethonium and halothane suffered cardiac arrest on two occasions. Clinical and laboratory examination subsequently showed that the patient had suffered from acute rhabdomyolysis. The eventual recovery was satisfactory.

Acute paroxysmal rhabdomyolysis with myoglobinuria is a rare syndrome which is attributed to a variety of causes. In many cases the syndrome is precipitated by a "trigger" event, such as severe physical exercise, infection, fever or the administration of certain drugs. Death may occur at the height of the attack because of hyperkalaemia, paralysis of respiratory muscles, or renal failure (Haase and Engel, 1960; Rowland and Penn, 1972). This report is of acute rhabdomyolysis without hyperpyrexia, associated with intraoperative cardiac arrest precipitated by an anaesthetic involving suxamethonium and halothane.

### CASE REPORT

A 9-year-old boy, weighing 37 kg and with no history of muscle weakness at the first consultation, underwent surgery for correction of strabismus. After premedication with atropine 0.4 mg and pethidine 40 mg i.m., anaesthesia was induced with nitrous oxide in oxygen and halothane. Suxamethonium 1 mg/kg was injected i.v. to facilitate tracheal intubation which, however, was difficult because of incomplete relaxation of the jaw muscles. At this moment the patient was suspected of having malignant hyperpyrexia and the temperature was monitored. Spontaneous respiration resumed within 5 min after administration of the suxamethonium and anaesthesia was continued with 50% nitrous oxide in oxygen with 1% halothane in a rebreathing circuit. Arterial pressure was 80/60 mm Hg and heart rate 100 beat/min. The cardiovascular measurements remained stable for the next 20 min until, suddenly, the pulse became impalpable and the surgeon observed an enlargement of the pupil. The e.c.g. showed cardiac arrest in asystole. After 30 s of external cardiac massage, spontaneous

cardiac activity started again and the e.c.g. showed enlarged ventricular complexes at a rate of about 100/min. Arterial pressure was 120/80 mm Hg. The operation was terminated quickly. About 15 min later the heart rate slowed again and a further cardiac arrest in asystole occurred. The second resuscitation was difficult. Only after more than 15 min of external cardiac massage, repeated i.v. administrations of increasing doses of adrenaline up to 0.5 mg, calcium gluconate 1.0 g, infusion of sodium bicarbonate 84 mmol/litre, frusemide 200 mg and 100 ml of 20% human albumin solution did ventricular fibrillation appear which was converted to a sinus rhythm accompanied by frequent extrasystoles; these could be suppressed by an infusion of lignocaine. The pupils remained small throughout resuscitation and the temperature did not exceed 36.5 °C. At this time the patient showed signs of regaining consciousness and was sedated with diazepam 5 mg and paralysed with pancuronium 2 mg. After 1 h of controlled ventilation, spontaneous respiration recommenced and the tracheal tube was removed. At this time the following blood measurements were obtained: sodium 131 mmol/litre, potassium 5.8 mmol/litre, chloride 92 mmol/litre, calcium 1.37 mmol/litre, phosphate 3.7 mmol/litre, protein 82 g/litre, s.g.o.t. 865 i.u., s.g.p.t. 241 i.u., c.p.k. 16 860 i.u. The abnormal values of calcium and phosphate had returned to normal by the next morning. After urethral catheterization 750 ml of red-coloured urine was obtained. The presence of myoglobin was confirmed by the Blondheim reaction, by gel filtration and by electrophoresis (Adams and Rozman, 1970). During the period that followed, urine concentrations of myoglobin, creatine and amino acids were measured daily together with c.p.k. in serum (table I). On the 4th day a biopsy of the quadriceps muscle was obtained for histology, histochemistry and electron microscopy (Jerusalem and Bischoff, 1975) (figs 1 and 2). The e.m.g. (by courtesy of E. Meyer, Zürich) showed low voltage and brief

H. SCHAER, M.D., Department of Anaesthesia; C. MAIER, M.D., Department of Medicine; Kreisspital, CH-8708 Männedorf-Zürich, Switzerland. B. STEINMANN, M.D., Department of Paediatrics; S. JERUSALEM, M.D., Department of Neurology; University of Zürich.

TABLE I. Course of c.p.k. values in serum and urinary excretion of myoglobin, creatine, carnosine,  $\beta$ -alanine and taurine (expressed as mg/g of creatinine excreted). (Note: parallel normalization of the urinary metabolites)

	Time after op.	Blood		Urine			
		c.p.k. (i.v.)	Myoglobin	Creatine	Carnosine	$\beta$ -Alanine	Taurine
Day	0	16 860	1020	2310	104	14	189
	1	77 390	6550	6620	64	12	1848
			2630	1560	0	0	105
	2	49 320	330	770			
	3	21 740	180	20			
	4	8500	trace	50			
	5	2420	0	20			
6	1170	0	20				
7	680	0	40				
Month	2	178					
	6	272					
	12	260					

duration action potentials in the quadriceps, tibialis anterior, triceps brachii and biceps brachii muscles. The subsequent clinical course was uneventful and the patient left the hospital on the 10th day without any residual symptoms.

After this event inquiry revealed that the patient had complained about muscle pains up to the age of 6 yr and that family walks had had to be stopped because of these complaints. Physical examination revealed a normally grown boy without any myopathic signs (except strabismus). After ischaemic forearm exercise and exercise on an ergometer for 3 min, a normal rate of increase in serum lactic acid concentration occurred, indicating normal glycolysis and glycogenolysis. A normal carnitine concentration in serum and muscle and a normal carnitine palmityl-transferase activity in muscle were determined (by courtesy of A. G. Engel, Mayo Clinic, Rochester, U.S.A.). The e.m.g. at 6 and 12 months after the cardiac arrest was normal.

The younger sister of the patient had never complained about muscle pain and had not suffered strabismus. A series of c.p.k. estimations was: 140, 425, 108 i.u. The e.m.g. and the increase in lactic acid were normal. The parents of the patient had normal c.p.k. values.

#### DISCUSSION

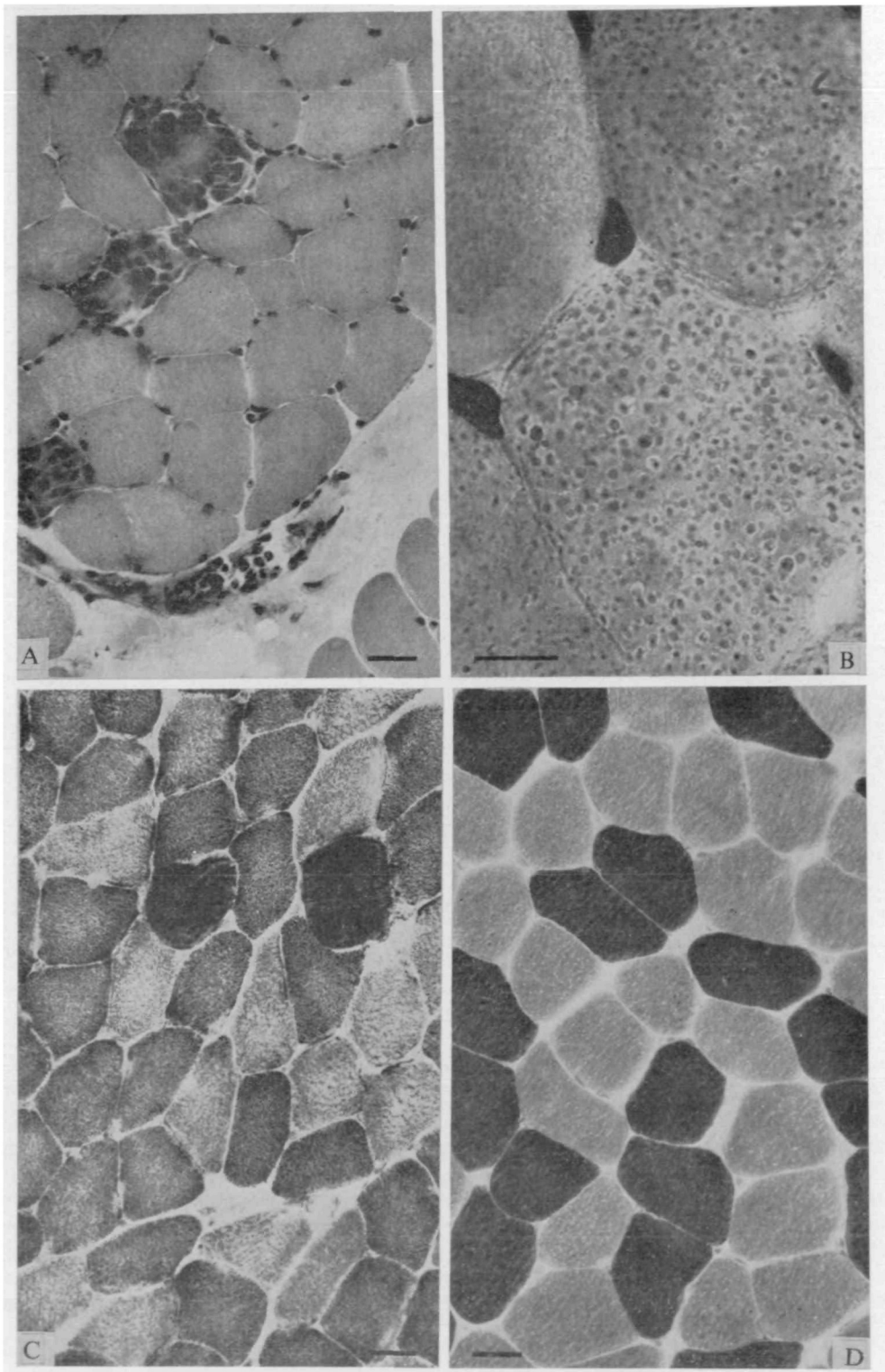
The clinical course and the biochemical and histological findings in this patient confirm the diagnosis of paroxysmal myoglobinuria as a result of a clinically inapparent myopathy. The biochemical examinations, however, gave no clue to the nature of the muscle

disease. In particular, no indication of a disorder of lipid metabolism, glycogenolysis and glycolysis could be found (Rowland and Penn, 1972; Engel and Angelini, 1973; Bank et al., 1975).

The normal c.p.k. values in the parents, but the increased values in both children are indicative of an autosomal recessive mode of inheritance. The occurrence of cardiac arrest could be explained by rapid electrolyte changes across the cell membrane, especially of calcium during destruction of muscle. Such low calcium and high phosphate values are typical of the early phase of acute rhabdomyolysis (Grossman et al., 1974; Cifuentes et al., 1976).

The interest in complications resulting from the action of suxamethonium and potent anaesthetic agents on myopathic muscle has been focused mainly on the syndrome of malignant hyperpyrexia. It is recognized less that the same agents can produce acute rhabdomyolysis with myoglobinuria in patients with certain types of muscle disease. In 1964, Bennike and Jarnum reported a 20-year-old male who developed idiopathic myoglobinuria with subsequent renal failure after an anaesthetic involving suxamethonium and halothane. The main finding was a marked increase in the serum concentrations of creatine phosphokinase, the transaminases and lactate dehydrogenase. A further patient was reported by McLaren (1968) after a similar anaesthetic procedure. Jensen and colleagues (1968) have described a case of myoglobinuria after an overdose of suxamethonium.

Recently another patient with massive myoglobinuria precipitated by halothane and suxamethonium



**FIG. 1.** Fresh frozen cross-sections of muscle tissue stained with (A) haematoxylin and eosin and (B) Oil-red-o and reacted for the demonstration of (C) reduced diphosphopyridine nucleotide dehydrogenase (DPNH) and (D) myofibrillar ATPase at pH 9.3. (A) Three muscle fibres show degenerative changes with invasion of phagocytes. (B) The presence of neutral fat is demonstrated by the Oil-red-o staining. (C) and (D) The normal distribution of different fibre types is preserved. Horizontal bars represent 20  $\mu\text{m}$  (A, C, D) and 10  $\mu\text{m}$  (B).




FIG. 2. Electron micrograph of a longitudinally oriented muscle fibre. The abnormal spaces (arrows) are positioned between the myofibrils, most of them probably represent lipid droplets. Horizontal bar represents 2  $\mu\text{m}$ .

but without cardiovascular and renal complications, was reported (Moore, Watson and Summary, 1976).

The normal effect of suxamethonium on the release of myoglobin is well established. In adult patients the appearance of myoglobin in serum is rare, whereas in a group of children aged 0–10 yr, myoglobin (5–15  $\mu\text{g}/\text{ml}$  serum) could be detected in 40% of the patients after a single i.v. dose of suxamethonium 1 mg/kg (Airaksinen and Tammisto, 1965; Jensen et al., 1968; Ryan, Kagen and Hyman, 1971). Furthermore, congenital factors predisposing to the development of rhabdomyolysis are found in certain types of patients with strabismus more often than in other children (Tammisto et al., 1970). In

addition, halothane appears to play a role in the production of the muscle injury since myoglobinuria and increased concentrations of c.p.k. did not occur during nitrous oxide and oxygen anaesthesia (Tammisto and Airaksinen, 1966). It appears from all these studies that the release of minute amounts of myoglobin and a slight increase of c.p.k. after the injection of suxamethonium may be a frequent response to this agent in certain groups of patients.

However, these insignificant side-effects of suxamethonium are very different from the excessive muscle necrosis observed in our patient, who even one year after the accident still showed increased c.p.k. values. Therefore we must consider this

incident as a further case of acute rhabdomyolysis or paroxysmal myoglobinuria, precipitated by anaesthesia with suxamethonium and halothane. Only a few examples of this complication have been reported. However, it must be considered that, in contrast to the syndrome of malignant hyperpyrexia, there appears to be no clinical symptom which points to this complication at the height of the attack. The only clinical sign, an inappropriate muscle relaxation after suxamethonium, is considered an indication of malignant hyperpyrexia.

In cases of an unexplained fatal intraoperative cardiac arrest, preservation of plasma, urine and fresh frozen muscle tissue is imperative for further diagnosis. This is particularly important for the medico-legal clarification of such cases.

## REFERENCES

- Adams, E. C., and Rozman, M. J. (1970). Differentiation of hemoglobinuria and myoglobinuria in renal diseases; in *Laboratory Diagnosis of Kidney Disease* (eds F. W. Sunderman and F. W. Sunderman jr). St Louis, U.S.A.: Green and Warren.
- Airaksinen, M. M., and Tammisto, T. (1965). Myoglobinuria after intermittent administration of succinylcholine during halothane anesthesia. *Clin. Pharmacol. Ther.*, **7**, 583.
- Bank, W. J., DiMauro, S., Bonilla, E., Capuzzi, D. M., and Rowland, L. P. (1975). A disorder of muscle lipid metabolism and myoglobinuria. Absence of carnitine palmityl transferase. *N. Engl. J. Med.*, **252**, 443.
- Bennike, K.-A., and Jarnum S. (1964). Myoglobinuria with acute renal failure possibly induced by suxamethonium. *Br. J. Anaesth.*, **36**, 730.
- Cifuentes, E., Norman, M. E., Schwartz, M. W., Maley, B., and Bason, W. (1976). Myoglobinuria with acute renal failure in children. The importance of intensive care and peritoneal dialysis. *Clin. Pediatr.*, **15**, 63.
- Engel, A. G., and Angelini, C. (1973). Carnitine deficiency of human skeletal muscle with associated lipid storage myopathy: A new syndrome. *Science*, **179**, 899.
- Grossman, R. A., Hamilton, R. W., Morse, B. M., Penn, A. S., and Goldberg, M. (1974). Non-traumatic rhabdomyolysis and acute renal failure. *N. Engl. J. Med.*, **291**, 807.
- Haase, G. R., and Engel, A. G. (1960). Paroxysmal recurrent rhabdomyolysis. *Arch. Neurol.*, **2**, 410.
- Jensen, K., Bennike, K.-A., Hanel, H. K., and Olesen, H. (1968). Myoglobinuria following anaesthesia including suxamethonium. *Br. J. Anaesth.*, **40**, 329.
- Jerusalem, F., and Bischhausen, R. (1975). Zur Technik der Muskelbiopsie. *Nervenarzt*, **46**, 42.
- McLaren, C. A. B. (1968). Myoglobinuria following the use of suxamethonium chloride. A case report. *Br. J. Anaesth.*, **40**, 901.
- Moore, W. E., Watson, R. L., and Summary, J. J. (1976). Massive myoglobinuria precipitated by halothane and succinylcholine in a member of a family with elevation of serum creatine phosphokinase. *Anesth. Analg. (Cleve.)*, **55**, 680.
- Rowland, L. P., and Penn, A. S. (1972). Myoglobinuria. *Med. Clin. N. Am.*, **56**, 1233.
- Ryan, J. F., Kagen, L. J., and Hyman, A. I. (1971). Myoglobinemia after a single dose of succinylcholine. *N. Engl. J. Med.*, **285**, 824.
- Tammisto, T., and Airaksinen, M. (1966). Increase of creatine kinase activity in serum as sign of muscular injury caused by intermittently administered suxamethonium during halothane anaesthesia. *Br. J. Anaesth.*, **38**, 510.
- Brander, P., Airaksinen, M. M., Tommila, V., and Listola, J. (1970). Strabismus as possible sign of latent muscular disease predisposing to suxamethonium-induced muscular injury. *Ann. Clin. Res.*, **2**, 126.

### RHABDOMYOLYSE PROVOQUEE PAR L'ANESTHESIE AVEC ARRET CARDIAQUE INTRAOPERATOIRE

## RESUME

Un garçon de 9 ans subissant une anesthésie à base de suxaméthonium et d'halothane a souffert d'un arrêt cardiaque à deux reprises. Les examens cliniques et ceux effectués par la suite en laboratoire ont montré que le malade avait souffert d'une rhabdomyolyse aiguë. La guérison ultérieure a été satisfaisante.

### DURCH ANÄSTHESIE EINGELEITETE RHABDOMYOLYSE MIT HERZSTILLSTAND WÄHREND DER OPERATION

## ZUSAMMENFASSUNG

Ein 9-jähriger Junge in einer Suxamethonium- und Halothannarkose erlitt bei zwei Gelegenheiten Herzstillstand. Klinische und laboratoriumsmässige Untersuchungen im Anschluss daran zeigten, dass der Patient an akuter Rhabdomyolyse gelitten hatte. Die schliessliche Erholung war zufriedenstellend.

### RABDOMIOLISIS INDUCIDA MEDIANTE ANESTESIA CON PARO CARDIACO INTRAOPERATIVO

## SUMARIO

Un muchacho de 9 años sometido a anestesia incluyendo suxametonio y halotano padeció de paro cardiaco en dos ocasiones. El examen clínico y de laboratorio efectuado subsiguientemente reveló que el paciente había sufrido una rabdomiolisis aguda. La recuperación eventual fue satisfactoria.

