

# Viral Escape in the Central Nervous System with Multidrug-Resistant Human Immunodeficiency Virus-1

C. Béguelin,<sup>1</sup> M. Vázquez,<sup>1</sup> M. Bertschi,<sup>2</sup> S. Yerly,<sup>3</sup> D. de Jong,<sup>2</sup> K. Gutbrod,<sup>2</sup> A. Rauch,<sup>1</sup> and A. Cusini<sup>1,4</sup>

<sup>1</sup>Department of Infectious Diseases, Inselspital, Bern University Hospital, University of Bern; <sup>2</sup>Department of Neurology, Bern University Hospital and University of Bern; <sup>3</sup>Laboratory of Virology, Geneva University Hospital, and <sup>4</sup>Infectious Diseases Unit, Cantonal Hospital, Chur, Switzerland

In this study, we report the case of a patient infected with human immunodeficiency virus (HIV)-1 who developed ataxia and neurocognitive impairment due to viral escape within the central nervous system (CNS) with a multidrug-resistant HIV-1 despite long-term viral suppression in plasma. Antiretroviral therapy optimization with drugs with high CNS penetration led to viral suppression in the CSF, regression of ataxia, and improvement of neurocognitive symptoms.

**Keywords.** central nervous system; HIV; K65R; viral escape; multidrug-resistant.

## CASE PRESENTATION

We describe the case of a 50-year-old patient who was diagnosed with human immunodeficiency virus (HIV)-1 in 1995. The patient started antiretroviral therapy (ART) in 1998 with a CD4 cell count of 71 cells/ $\mu$ L and an HIV viremia of 46 000 copies/mL. Sustained viral suppression was achieved after starting an ART with zidovudine (AZT), lamivudine (3TC), and efavirenz (EFV) (Figure 1). The patient elected to interrupt ART in 2002, at which point his HIV viremia was undetectable. After 2 years, the patient's CD4 dropped to 43 cells/ $\mu$ L and HIV viremia was raised to 73 700 copies/mL. At that time (October 2004), the drug resistance for HIV-1 in plasma showed no resistance mutations. Antiretroviral therapy with tenofovir (TDF), emtricitabine (FTC), and ritonavir-boosted atazanavir (ATV/r) was reintroduced. This regimen suppressed HIV-1 in plasma for the next 9 years, and CD4 cells stabilized at approximately 600 cells/ $\mu$ L.

Received 2 October 2015; accepted 19 December 2015.

Correspondence: C. Béguelin, Department of Infectious Diseases, Inselspital, Bern University Hospital, University of Bern, 3006 Bern, Switzerland (charles.beguelin@insel.ch).

### Open Forum Infectious Diseases®

© The Author 2015. Published by Oxford University Press on behalf of the Infectious Diseases Society of America. This is an Open Access article distributed under the terms of the Creative Commons Attribution-NonCommercial-NoDerivs licence (<http://creativecommons.org/licenses/by-nc-nd/4.0/>), which permits non-commercial reproduction and distribution of the work, in any medium, provided the original work is not altered or transformed in any way, and that the work is properly cited. For commercial re-use, please contact [journals.permissions@oup.com](mailto:journals.permissions@oup.com). DOI: 10.1093/ofid/ofv210

Because the course of treatment was favorable, the patient only came for the routine examinations in our clinic every 6 months. At his visit in April 2013 he was asymptomatic. At the end of November in 2013, during his next scheduled examination, the patient complained about severe gait ataxia, headaches, persisting fatigue, as well as memory difficulties for 2 months, which forced him to stop his work as a bus driver. We initiated a comprehensive work up including detailed neurological investigations, blood and cerebrospinal fluid (CSF) analysis, neuroimaging, and neuropsychological testing.

In January 2014, the CSF showed a mononuclear pleocytosis with 75 cells/ $\mu$ L, an elevated protein of 985 mg/L, a normal glucose of 3.4 mmol/L, and 1184 HIV-1 RNA copies/mL, whereas HIV-1 in plasma was below 20 copies/mL. Human immunodeficiency virus-1 viral load in plasma and in CSF was quantified using Cobas TaqMan HIV-1 version 2.0 (Cobas Ampliprep; Roche Diagnostic, Basel, Switzerland) with a detection limit of 20 copies/mL. Drug resistance testing in HIV-1 reverse-transcriptase and protease using bulk sequencing of the CSF-HIV-1 RNA showed 2 nucleoside reverse-transcriptase inhibitor (NRTI) resistance-associated mutations (M184 V and K65R) and 1 non-NRTI (NNRTI) resistance-associated mutation (K103N). The cerebral magnetic resonance image showed increased signal on T2-weighted images in the subcortical and periventricular white matter, as well as in the basal ganglia and thalamus, without contrast enhancement (Figure 2).

The only pathological finding in the neurological examination was the patient's tendency to fall to the left side during a straight-line walking test. The neuropsychological evaluation confirmed neurocognitive impairments in executive functions, attention, working and nonverbal memory, speed of information processing, visuospatial abilities, and motor skills. Because functional impairments in everyday life were reported, the patient was diagnosed with HIV-associated mild neurocognitive disorder (Supplementary Appendix 1). Laboratory investigations revealed no alternative etiologies for the neurological symptoms. Explicitly, the duplex sonography of the brain-supplying arteries was normal with no signs of cerebrovascular disease. Moreover, there were no metabolic or neoplastic diseases that could have explained the neurological deficits.

Four months after ART intensification with AZT, 3TC, ritonavir-boosted darunavir (DRV/r), and raltegravir (RAL), the cellularity in CSF normalized to 1 cell/ $\mu$ L and HIV viral load was successfully suppressed. The protein level (0.84 mg/L) was still slightly elevated, and the glucose (3.89 mmol/L) was in a normal range. During the following months, the subjective complaints of equilibrium disturbance, headache, fatigue, and impaired memory progressively resolved. A follow-up neurological

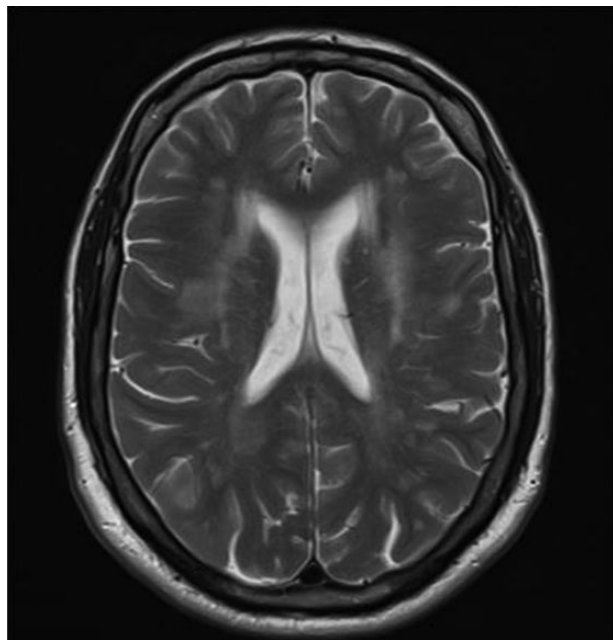
	Dec 98	Mar 99	Oct 02	Oct 04	Sept 07	Jan 14	Mar 14
<b>NRTI</b>			<b>Therapy break</b>				
AZT/3TC							
3TC							
TDF							
TDF/FTC							
<b>NNRTI</b>							
EFV							
<b>PI</b>							
NLV							
ATV/RTV							
DRV/RTV							
<b>II</b>							
RAL							
<b>CPE Score</b>	7	9		5	6	12	12
<b>HIV (plasma) Viremia Cp/ml</b>	46'000	<40		73'700	<20	<20	<20
<b>HIV (CSF) Viremia Cp/ml</b>						1184	<20
<b>CD4/ul</b>	71	139/11%		43/5%	441/19%	790/28%	626/31%

**Figure 1.** Human immunodeficiency virus (HIV) viremia, CD4 cell count, and antiretroviral therapy from 1998 to 2014. Abbreviations: ATV, atazanvir; AZT, zidovudine; CPE, central penetration effectiveness; DRV, darunavir; EFV, efavirenz; FTC, emtricitabine; II, integrase inhibitors; NLV, nelfinavir; NNRTIs, nonnucleoside reverse-transcriptase inhibitors; NRTIs, nucleoside reverse-transcriptase inhibitors; PI, protease inhibitors; RAL, raltegravir; RTV, ritonavir; TDF, tenofovir disoproxil fumarate; 3TC, lamivudine.

examination confirmed the total regression of the ataxia with a normal neurological status, including a normal straight-line walking test.

Nevertheless, the neuropsychological follow up 18 months after baseline testing showed only minimal regression of the neurocognitive deficiencies, with attention, speed of information processing, visuospatial abilities, and motor skills being

similar to baseline; however we observed significant improvement in verbal memory, nonverbal divergent thinking, and orientation memory. The questionnaire of Instrumental Activities of Daily Living showed no more impairments in daily life functioning. Because objectively neurocognitive impairments were still present, but without impairments in daily functioning, the patient was diagnosed with HIV-associated asymptomatic neurocognitive impairment.



**Figure 2.** Magnetic resonance imaging showing confluent T2-hyperintense signal changes.

## DISCUSSION

We describe the case of a 50-year-old patient infected with HIV-1 presenting with subacute neurological symptoms due to a “viral escape encephalitis” in the CSF with a multidrug-resistant virus. Human immunodeficiency virus, in addition to its tropism for the immune system, has a tropism for the central nervous system (CNS) [1, 2]. In general, HIV infection of the CNS responds well to combined ART. However, in some patients, HIV RNA is detectable in the CSF despite plasma viral control, or the CSF HIV-RNA level is  $\geq 1$  log greater than the plasma HIV-RNA level. This rare condition has been defined as “CSF escape”. There are conflicting studies regarding the exact clinical relevance of CSF escape: Eden et al [3] found asymptomatic CSF escape in 7 of 69 (10%) patients on ART, with a median of 121 copies/mL (interquartile range, 54–213 copies/mL) in the CSF. Cerebrospinal fluid viremia above 1000 cp/mL, such as that found in our case, were not found in these patients. Canestri et al [4] and Peluso et al [5] each reported a case series of 11 and 10 patients with CSF escape and neurological symptoms, respectively. The median CSF viral load of these patients was 880 copies/mL (range, 558–12 885 copies/mL)

and 3900 copies/mL (range, 134–9056 copies/mL), respectively, which is higher than in the case series of asymptomatic patients described by Eden et al [3] but comparable to the viral load in the CSF of our patient.

It is remarkable that at the time of neurological complaints, the patient's antiretroviral regimen had been unchanged for 9 years, which is much longer than in the above-mentioned case series, where the time of unchanged ART was 13 and 21 months, respectively. The HIV-1 RNA in the CSF of our patient harbored 2 NRTI (M184V and K65R) and 1 NNRTI (K103N) resistance-associated mutations. It is notable that the K103N mutation was preserved for 14 years after stopping NNRTI therapy. We assumed that the drug resistance mutations M184V and K103N emerged during or after discontinuation of treatment with AZT, 3TC, and EFV because these mutations were not present at diagnosis of HIV infection. It is possible that stopping these drugs simultaneously led to exposure to EFV monotherapy given the long half-life of this compound facilitating the emergence of NNRTI resistance [6]. We cannot prove that these resistance mutations originally developed in the CNS because no resistance test in plasma was performed in 2002 immediately after discontinuing the first ART regimen. However, the fact that we could not detect the M184V nor the K103N resistance mutations in the plasma before we restarted ART in October 2004 could be a hint that the mutations originally developed in the CNS. The second ART regimen with TDF, 3TC, and ATV/r achieved a sustained viral suppression in plasma; however, an autonomous replication and independent evolution of the HIV-1 harboring the K65R mutation (typically associated with virological failure of TDF) in the CSF occurred. This isolated mutation could have emerged in the CSF because the cerebral virus already harbored the M184V mutation, and thus the second treatment regimen was less effective in the CNS compared with plasma. The occurrence of isolated resistance-associated mutations in the CSF has been reported previously. In the above-mentioned case series, Canestri et al [4] found resistance-associated mutations in 7 of 8 CSF HIV-RNA strains, and Peluso et al [5] found resistance-associated mutations in 6 of 7 CSF HIV-RNA strains. They found resistance mutations for NRTI, NNRTI, and protease inhibitors (PI) [4]. This result emphasizes the importance of performing a resistance test in patients with viral escape in the CSF.

Letendre et al [7] have proposed the CNS penetration-effectiveness (CPE) score to estimate the drug penetration into the CNS and the correlation with CSF-HIV replication. Remarkably the CPE score of the second ART regimen with TDF, 3TC, and ATV/r in our patient had a low CPE score of only 5. Considering that presumably the HIV-1 already harbored the M184V mutation when this regimen was started, the adjusted CPE score was only 3. This low CPE score may have contributed to the development of the K65R mutation in CSF and the consequent viral escape in CSF. When we tailored

the salvage ART of our patient, we first considered the resistance pattern of the HIV-1 found in the CSF, but we also choose substances with an increased CPE score. We changed the PI atazanavir/ritonavir (CPE = 2) to darunavir/ritonavir (CPE = 3) and added AZT (CPE = 4) and RAL (CPE = 3) to achieve a high total CPE score of 12 or 10, considering the resistance-associated mutations in the CSF. With this treatment regimen, viral suppression in the CSF could be achieved within 4 months. In addition, the CSF pleocytosis normalized to 1 cell/ $\mu$ L.

Our case is further proof that compartmentalization of HIV-1 replication in the CNS can occur in patients taking ART regimen with poor intracerebral penetration. In addition to the low CSF drug concentration and treatment interruption, the impaired cellular immunity of our patient with a low CD4 nadir of only 43 cells/ $\mu$ L may have contributed to his viral escape in CSF. Several studies have described an association between low CD4 counts and neurocognitive impairment [8]. All of these factors probably contributed to symptomatic multidrug-resistant HIV replication in the CSF despite suppressed plasma viremia, which is a rare event. Similar to the patients of the above-mentioned case series, the viral escape encephalitis symptoms of our patient improved after optimizing ART. Ataxia as well as subjective complaints such as headaches and fatigue resolved, resulting in no more impairments in daily life functioning. However, follow-up neuropsychological examination showed only minimal regression of neuropsychological impairment, which we attribute to potential irreversible intracerebral damage occurring during a long-lasting, undiscovered, ongoing cerebral HIV-1 replication.

## CONCLUSIONS

Patients infected with HIV-1 with neurological complaints warrant further investigation of the CSF including measurement of HIV viral load and genotypic resistance testing, because isolated replication of HIV with drug-resistant variants can rarely occur despite viral suppression in plasma. Optimizing ART by using drugs with improved CNS penetration may achieve viral suppression in CSF with improvement of neurological symptoms.

## Supplementary Data

Supplementary material is available online at Open Forum Infectious Diseases online (<http://OpenForumInfectiousDiseases.oxfordjournals.org/>)

## Acknowledgments

We thank the patient for giving us the opportunity to publish his case.

**Potential conflicts of interest.** All authors: No reported conflicts. All authors have submitted the ICMJE Form for Disclosure of Potential Conflicts of Interest.

## References

1. Gorry PR, Bristol G, Zack JA, et al. Macrophage tropism of human immunodeficiency virus type 1 isolates from brain and lymphoid tissues predicts neurotropism independent of coreceptor specificity. *J Virol* 2001; 75:10073–89.
2. Peters PJ, Bhattacharya J, Hibbitts S, et al. Biological analysis of human immunodeficiency virus type 1 R5 envelopes amplified from brain and lymph node tissues of AIDS patients with neuropathology reveals two distinct tropism phenotypes and

- identifies envelopes in the brain that confer an enhanced tropism and fusigenicity for macrophages. *J Virol* **2004**; 78:6915–26.
3. Eden A, Fuchs D, Hagberg L, et al. HIV-1 viral escape in cerebrospinal fluid of subjects on suppressive antiretroviral treatment. *J Infect Dis* **2010**; 202:1819–25.
  4. Canestri A, Lescure FX, Jaureguiberry S, et al. Discordance between cerebral spinal fluid and plasma HIV replication in patients with neurological symptoms who are receiving suppressive antiretroviral therapy. *Clin Infect Dis* **2010**; 50:773–8.
  5. Peluso MJ, Ferretti F, Peterson J, et al. Cerebrospinal fluid HIV escape associated with progressive neurologic dysfunction in patients on antiretroviral therapy with well controlled plasma viral load. *AIDS* **2012**; 26:1765–74.
  6. Santoro MM, Sabin C, Forbici F, et al. Drug-resistance development differs between HIV-1-infected patients failing first-line antiretroviral therapy containing nonnucleoside reverse transcriptase inhibitors with and without thymidine analogues. *HIV Med* **2013**; 14:571–7.
  7. Letendre S, Marquie-Beck J, Capparelli E, et al. Validation of the CNS penetration-effectiveness rank for quantifying antiretroviral penetration into the central nervous system. *Arch Neurol* **2008**; 65:65–70.
  8. Ellis RJ, Badiee J, Vaida F, et al. CD4 nadir is a predictor of HIV neurocognitive impairment in the era of combination antiretroviral therapy. *AIDS* **2011**; 25:1747–51.