



ELSEVIER

European Journal of Cardio-thoracic Surgery 36 (2009) 1058–1063

EUROPEAN JOURNAL OF
CARDIO-THORACIC
SURGERYwww.elsevier.com/locate/ejcts

Taurolidine in the prevention and therapy of lung metastases

Beatrix Hoksch^{a,*}, Benjamin Rufer^a, Amiq Gazdhar^a, Murat Bilici^a, Morris Beshay^b,
Matthias Gugger^c, Ralph Alexander Schmid^a

^aDivision of General Thoracic Surgery, University Hospital, Berne, Switzerland

^bDivision of General Thoracic Surgery, Centre of Pulmonary Diseases, Evangelic Hospital, Bielefeld, Germany

^cInstitute of Pathology, University of Berne, Berne, Switzerland

Received 26 November 2008; received in revised form 8 April 2009; accepted 14 April 2009

Abstract

Objective: During surgery for colon carcinoma, tumour cells may spread into the blood and may lead to the development of distant metastases. The most frequent sites of metastases are the liver and lungs. A new therapeutic approach is required to prevent tumour implantation of freely circulating tumour cells during and after surgery and to treat established metastases. The aim of this prospective study was to observe the influence of long-term intravenous taurolidine on the development of lung metastases after intravenous injection of colon adenocarcinoma cells. **Methods:** Tumour cells (DHD/K12/TRb colon adenocarcinoma cell line, 1×10^6 cells) were injected into the right vena jugularis interna of BDIX rats. The animals ($n = 13$) were randomised into three groups: group 1: tumour cell implantation without taurolidine application (control group); group 2: tumour cell implantation and simultaneous start of the taurolidine injection through osmotic pump, removal of the osmotic pump on day 7; group 3: tumour cell implantation on day 0 and start of the taurolidine injection through osmotic pump on day 14. **Results:** In the taurolidine groups, the number and size of lung metastases were significantly lower compared to the control group ($p = 0.018$; $p = 0.018$ and $p = 0.036$; $p = 0.018$). Although the results of the intravenous long-term therapy with taurolidine in group 2 did not reach statistical significance in comparison with the results of group 3, a positive trend was revealed: The mean number of metastases in group 2 was 18.2 versus 28.2 in group 3. **Conclusions:** The application of taurolidine tends to prevent the development of lung metastases. Furthermore, taurolidine seems to reduce established lung metastases in this *in vivo* model. Taurolidine may offer additional therapeutic options in patients with colon adenocarcinoma. © 2009 European Association for Cardio-Thoracic Surgery. Published by Elsevier B.V. All rights reserved.

Keywords: Taurolidine; Colon adenocarcinoma; Lung metastases

1. Introduction

Colon adenocarcinoma is one of the leading causes of death by malignancy in Europe and the USA [1]. In the case of a curative treatment option, surgical resection remains the primary treatment modality for this cancer. During surgery, tumour cells may spread and may lead to both loco-regional recurrences and/or distant metastases [2–4]. More than 50% of all patients undergoing surgery for colon carcinoma can be expected to have a recurrence of the disease. The most frequent sites of recurrence are the liver and lungs: About 10% of the patients with a colon adenocarcinoma will develop lung metastases [5].

On the basis of this knowledge, the effect of taurolidine on the development of haematogenous adenocarcinoma metastases was examined in an experimental study with BDIX rats. Taurolidine has anti-adhesive and anti-angiogenic effects and induces apoptosis [6,7]. Up till now the majority of *in*

in vivo trials for the investigation of taurolidine and its impact on tumour development with colon adenocarcinoma cell lines deals with intra-peritoneal or subcutaneous growth [8,6,9]. The aim of this prospective study was to observe the influence of a long-term intravenous taurolidine injection on the development of lung metastases after intravenous injection of adenocarcinoma cells.

2. Material and methods

2.1. Animals

BDIX rats weighing 275–380 g (Charles River GmbH, Sulzfeld, Germany) were used. The animals were kept in single cages under standardised conditions with constant temperature (22 ± 1 °C), humidity (50–60%) and a 12:2 h light/dark cycle. Animals had free access to water and food. They received humane care in compliance with the European Convention on Animal Care, and the experiment was approved by the local veterinary committee (No.: 25/04).

* Corresponding author. Tel.: +41 31 632 3096; fax: +41 31 632 2327.
E-mail address: beatrix.hoksch@insel.ch (B. Hoksch).

2.2. Cell line

The DHD/K12/TRb colon adenocarcinoma cell line was used. The cell line was bought from the Center for Applied Microbiology & Research, ECACC (European Collection of Cell Cultures), Salisbury, UK. Cells were cultured in Dulbecco's MEM (Invitrogen AG, CH-4019 Basel, Switzerland), supplemented with penicillin, streptomycin (Invitrogen AG, CH-4019 Basel, Switzerland), and 5% CO₂ (37 °C). Cells were removed from the plates with 0.05% trypsin/0.02% EDTA, washed twice with PBS, suspended in medium, centrifuged and re-suspended in medium to the desired concentration.

For tumour implantation, a cell suspension containing 1×10^6 cells was prepared and the number of cells was controlled by a Neubauer-Zählkammer.

2.3. Application of taurolidine

A 2-ml taurolidine 2% (Geistlich Pharma AG, CH-6110 Wolhusen, Switzerland) was applied intravenously through a minipump (ALZET[®] Osmotic Pumps, 2 ml, Charles River Laboratories, Germany) continuously for 7 days. The osmotic pumps were prepared by following the instructions of Charles River Laboratories and were connected to the jugular vein by a special Rat Jugular Catheter (3¹/₂ × 5¹/₄, Carl Parker Associates, New York, USA).

2.4. Anaesthesia

After induction of anaesthesia in an isofluran chamber, the animals received an intra-peritoneal application of 50 mg kg⁻¹ pentobarbital.

During the surgery, the animals were placed on a heating pad.

2.5. Tumour induction

To provide evidence for tumour growth, we started a pilot study with two animals. These animals were sacrificed after tumour cell application on day 10 and day 15, respectively.

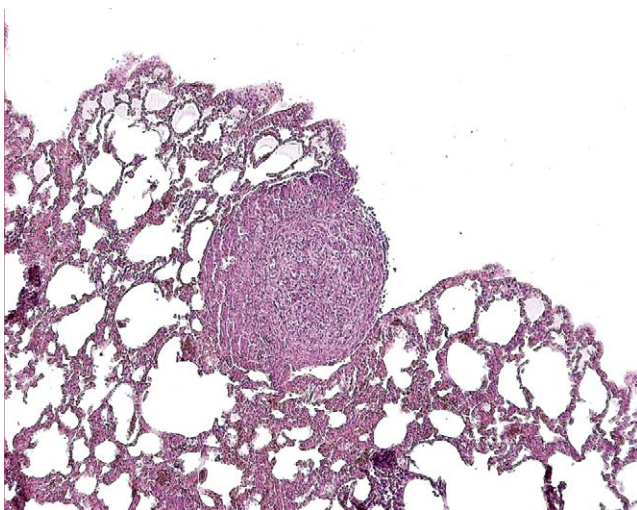


Fig. 1. Lung metastases (H.E.).

Both showed extensive dissemination of lung metastases (Fig. 1).

2.6. Animals and experimental groups

In the experimental prospective study, animals were randomised into three groups – group 1: tumour cell implantation (1×10^6 cells) without taurolidine application (control group); group 2: tumour cell implantation (1×10^6 cells) with simultaneous taurolidine application from day 0 to day 7, and removal of the osmotic pump on day 7; and group 3: tumour cell implantation (1×10^6 cells) with subsequent taurolidine application from day 14 to day 21.

Under anaesthesia, an incision was made on the right side of the neck and thorax (2 cm). The right vena jugularis interna was prepared. By venotomy, a small catheter was introduced and the tumour cell suspension was injected, and then the catheter was removed in groups 1 and 3 (Fig. 2).

In group 2, the prepared and filled osmotic pumps were implanted immediately after injection of the tumour cells. The special Rat Jugular Catheter was inserted by the same venotomy and fixed. For the osmotic pump, a small subcutaneous chamber was dissected on the back and the skin was closed. Seven days later, the empty osmotic pump was removed (anaesthesia as described above).

Animals of group 3 received the osmotic pump 14 days after tumour cell inoculation. The previous skin incision was re-opened, the right vena jugularis dissected and the pump

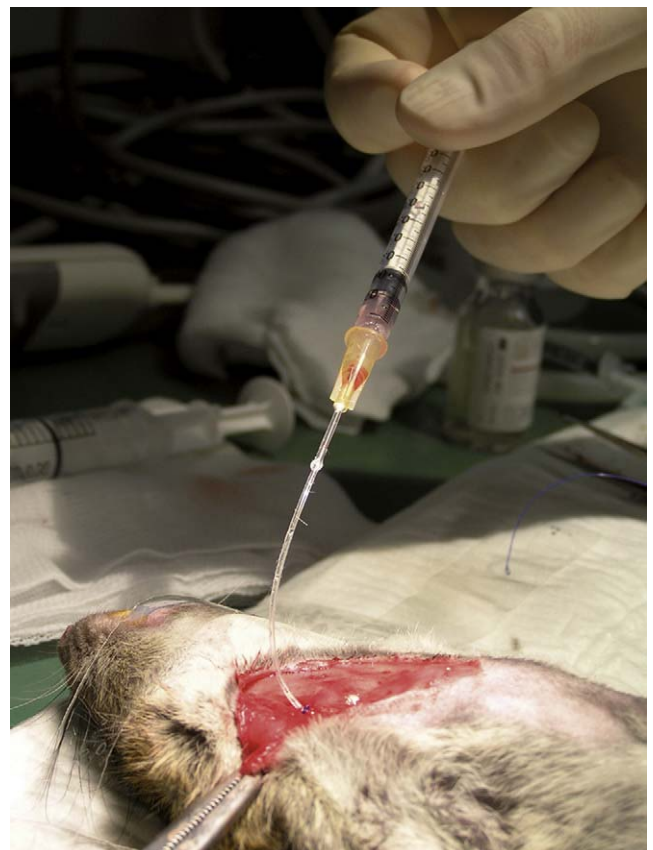


Fig. 2. Application of the tumor cells.

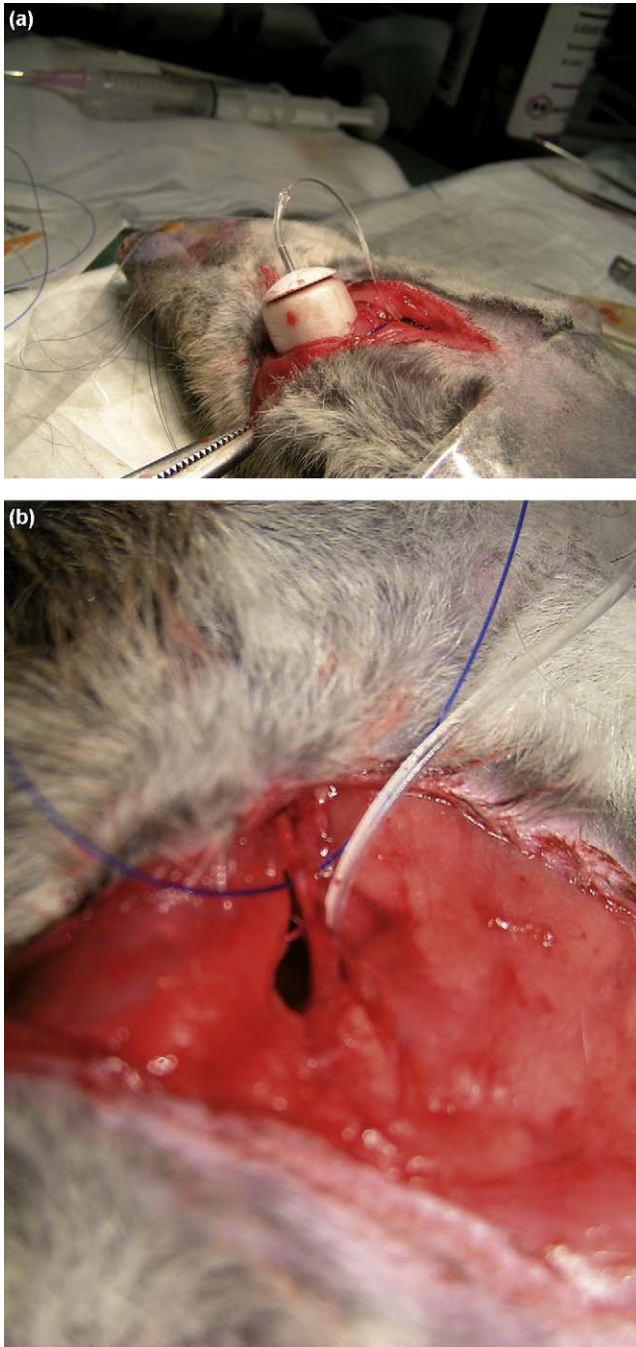


Fig. 3. Implantation of the osmotic pump/catheter in the right versus jugularis.

was implanted in the same way as described for animals in group 2 (Fig. 3a and b).

Group 1 served as the control group.

On the 21st day, animals were sacrificed under anaesthesia with pentobarbital.

2.7. Data analysis

The primary end point was the extent of lung metastases (size and number) in groups 2 and 3 in comparison with group 1 (control group).

The secondary end point was the extent of lung metastases (size and number) in group 2 in comparison with group 3.

2.8. Methods

The whole lungs were embedded in formaldehyde. Specimens were cut at 5 μm on defined levels in a distention of 100 μm (Leica RM 2155) and stained with haematoxylin and eosin (H.E.) for histological examination. The number and size (μm^2) of the metastases were registered (Nikon Eclipse E 800, Nikon DXM 1200 and PC program Lucia Image 5.1).

2.9. Statistics

Statistical analysis was carried out with the Wilcoxon rank-sum tests with a one-sided alternative hypothesis. No correction for multiple comparisons was performed.

Generally, p -values less than 0.05 were considered significant.

3. Results

3.1. Groups of animals and histological analysis of lung metastases

Table 1 shows the number of animals in each group and the development of lung metastases in the animals.

3.2. Number of lung metastases in all groups

In both taurolidine groups, the number of lung metastases was significantly lower compared with the control group ($p = 0.018$; $p = 0.018$) (Fig. 4 and Table 2).

Table 1
Groups of animals and histological analysis/evidence (*) of lung metastases.

	<i>n</i>	Lung metastases* (%)
Group 1 (control)	3	100
Group 2	5	60
Group 3	5	80

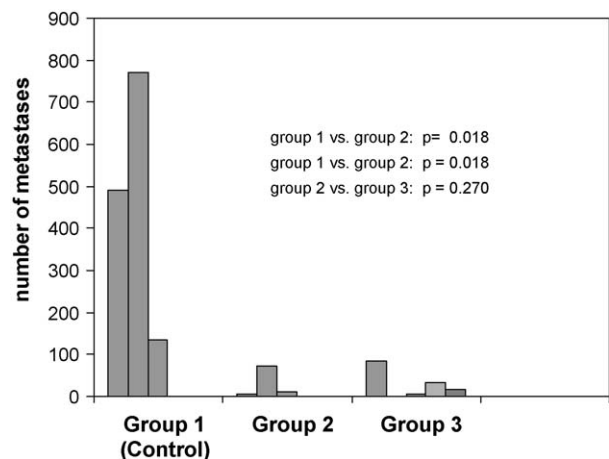
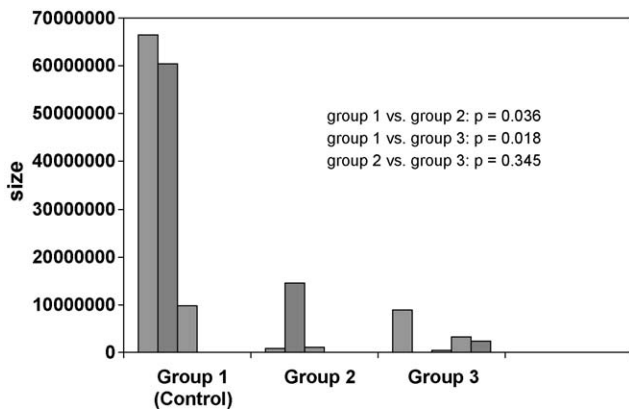


Fig. 4. Number of lung metastases in the different groups.

Table 2

Number and size (μm^2) of the lung metastases in the different groups $\bar{\emptyset}$ = mean, Σ = total/sum size of metastases in μm^2 .

Group 1 (control)			Group 2			Group 3		
Number of metastases		Size of metastases	Number of metastases		Size of metastases	Number of metastases		Size of metastases
1	491	66584556	1	7	927414	1	83	8878149
2	772	60478044	2	73	14480149	2	0	0
3	134	9851381	3	11	1046878	3	5	537134
–			4	0	0	4	35	3277246
–			5	0	0	5	18	2399775
Σ 1397		Σ 136913981		Σ 91	Σ 16454441		Σ 141	Σ 15092304
$\bar{\emptyset}$ 465.7 \pm 319.8		$\bar{\emptyset}$ 45637993.7		$\bar{\emptyset}$ 18.2 \pm 31.0	$\bar{\emptyset}$ 3290368.2		$\bar{\emptyset}$ 28.2 \pm 33.5	$\bar{\emptyset}$ 3018460.8

Fig. 5. Sum total of the size (mm^2) of lung metastases in the different groups.

Between groups 2 and 3, there was no significant difference with respect to the number of the lung metastases ($p = 0.270$).

3.3. Sum total size of lung metastases in all groups

The size of the lung metastases was significantly higher in the control group compared with groups 2 and 3 ($p = 0.036$; $p = 0.018$) (Fig. 5 and Table 2).

There was no significant difference between the taurolidine groups with respect to the size of metastases ($p = 0.345$).

4. Discussion

In the developed countries, colon carcinoma ranks first for incidence among gastrointestinal malignancies [10]. In general, patients with curatively resected colon cancer without a tumour involvement of the lymph nodes do not receive adjuvant chemotherapy. However, approximately 30–40% of these patients will develop loco-regional and/or distant metastases in the follow-up [1,11]. One explanation could be an incomplete lymph node staging or the missing of micro-metastases by classic histopathological examination [11]. However, another cause for this problem may be the release of tumour cells during the surgical resection. These free tumour cells can adhere, implant and grow – locally and distantly. Even if freely circulating tumour cells do not induce the development of local tumour recurrences or metastases

in every case, they are potential sources of tumour spread in the long term [12]. The hypothesis of tumour cell implantation by released free tumour cells has been verified in different trials *in vitro* and *in vivo* [2–4]. Koch et al. showed that free tumour cells found in blood samples during and after the operation led to a poorer outcome in comparison with patients without free tumour cells in the blood [3]. Parts of the underlying complex process of the development of metastases are known, such as cell adhesion, tumour cell invasion through the basement membrane and neoangiogenesis [2].

The pulmonary metastasectomy, in case of colon carcinoma, is an established technique in the multidisciplinary concept, but feasible only in 50% of the patients. In the case of complete resection, the 5-year survival rate ranged between 38.3% and 63.7% in comparison with those cases in which a resection was impossible (13%) [1,13]. A palliative chemotherapy (without resection of the lung metastases) shows survival rates of less than 15 months [14].

These statistics indicate a need for a new therapeutic approach to prevent tumour implantation of freely circulating tumour cells during and after surgery. The question is whether the application of a specific (cytotoxic) substance prevents the development of metastases in patients with colon adenocarcinoma. Taurolidine (a derivate of the amino acid taurine) has been widely used for treating severe infections such as peritonitis and pleural empyema for more than 25 years [2]. However, taurolidine has also been widely described for antineoplastic treatment in different cancer cell lines: Braumann et al. demonstrated a down-regulation of subcutaneous tumour growth (colon adenocarcinoma cell line DHD/K12/TRb cells) with an intravenous long-term therapy of 3% taurolidine [8]. Opitz et al. were able to show a significant reduction of local recurrence of malignant pleural mesothelioma using an intrapleural taurolidine treatment [15]. Kilian et al. inhibited tumour growth in ductal pancreatic adenocarcinoma by laparoscopic irrigation with taurolidine [16]. The effects of taurolidine are manifold. Amongst others, taurolidine is known to have anti-adhesive as well as anti-angiogenic properties [6,7]. It has been shown that long-term treatment with taurolidine can induce apoptosis [6,8]. The apoptosis could be partially caused by a mitochondrial cytochrome c-dependent apoptotic mechanism [17]. Furthermore, taurolidine reduces the production of vascular endothelial growth factor (VEGF), a major pro-angiogenic factor [8]. Additionally, taurolidine exerts a direct effect on glial and neuronal brain tumour cells through

currently unknown apoptotic pathways [18]. Lanfrancone et al. and Van Antwerp et al. found a decrease of tumour necrosis factor alpha (TNF α) and interleukin-1 β after taurolidine treatment [19,20].

Up to now, all known *in vivo* trials for the investigation of taurolidine and its impact on tumour development with colon adenocarcinoma cell lines deal with intra-peritoneal or subcutaneous growth [8,6,9,16,21]. Therefore, the development of lung metastases with the colon adenocarcinoma cell line DHD/K12/TRb had to be established in a first pilot phase. The spreading of free tumour cells was simulated by the direct injection of the tumour cell suspension of DHD/K12/TRb into the right vena jugularis. The cells went directly into the lungs and constituted lung metastases. Thereby, a model of colon adenocarcinoma lung metastases in BDIX rats was successfully established: In the pilot study, the animals showed lung metastases on day 10 and day 15, respectively, which means that lung metastases developed within 2 weeks.

This model allowed the effect of a continuous injection of taurolidine 2% in view of the development of lung metastases to be evaluated. All animals (100%) in the control group developed lung metastases in comparison with the treatment groups with 60% (group 2) and 80% (group 3), respectively. In the two groups with a taurolidine treatment, both the number and size of the lung metastases were significantly decreased in comparison with the control group. Although the results of intravenous long-term therapy with taurolidine in group 2 did not reach statistical significance in comparison with the results of group 3, a positive trend for the number of metastases was found (mean of group 2: 18.2 vs mean of group 3: 28.2). This means taurolidine may be a potential substance for preventing lung metastases when the application starts parallel to the releasing of free tumour cells, for example, during the primary colon resection. Furthermore, taurolidine may not only have the potential to prevent lung metastases of colon adenocarcinoma, but may also be used in their treatment: all the animals in the control group developed lung metastases, with a mean number of 465.7. In the case of treatment starting 2 weeks after tumour cell spread (group 3), one animal did not show lung metastases, another one had only five metastases. The mean number of metastases in group 3 was 28.2.

The sample size of this study is small. One reason for this is the high price of the osmotic pumps. To our knowledge, this trial is the first one showing the clear effect of taurolidine on lung metastases of colon adenocarcinoma in an animal model. This fact should be taken as an incentive for further studies.

5. Conclusion

To improve the outcome for patients with pulmonary metastatic colon adenocarcinoma, new concepts must be evaluated. The application of taurolidine tends to prevent the development of lung metastases and reduces the tumour growth in this *in vivo* model. Therefore, taurolidine represents an interesting substance for a multimodal approach in the therapy of colon adenocarcinoma even in the case of stages I and II (N0-status), in which adjuvant chemotherapy after the surgical resection is not regularly

recommended. Taurolidine may offer additional therapeutic options to prevent or treat lung metastases in the follow-up after surgical resection of colon adenocarcinoma.

Acknowledgement

The author would like to thank Jeannette Regan, PhD for help with the manuscript.

References

- [1] Pfannschmidt J, Dienemann H, Hoffmann H. Surgical resection of pulmonary metastases from colorectal cancer: a systematic review of published series. *Ann Thorac Surg* 2007;84:324–38.
- [2] Nestler G, Schulz HU, Schubert D, Krüger S, Lippert H, Pross M. Impact of taurolidine on the growth of CC531 coloncarcinoma cells *in vitro* and in a laparoscopic animal model in rats. *Surg Endosc* 2005;2:280–4.
- [3] Koch M, Kienle P, Kastrati D, Antolovic D, Schmidt J, Herfarth C, von Knebel Doeberitz M, Weitz J. Prognostic impact of hematogenous tumor cell dissemination in patients with stage II colorectal cancer. *Int J Cancer* 2006;12:3037–72.
- [4] Weitz J, Kienle P, Lacroix J, Willeke F, Benner A, Lehnert T, Herfarth C, von Knebel Doeberitz M. Dissemination of tumor cells in patients undergoing surgery for colorectal cancer. *Clin Cancer Res* 1998;4:343–8.
- [5] McCormack PM, Burt ME, Bains MS, Martini N, Rusch VW, Ginsberg RJ. Lung resection for colorectal metastases: 10-year results. *Arch Surg* 1992;127:1403–6.
- [6] Jacobi CA, Bouchier-Hayes D, Braumann C, Brock M, Pfirrmann RW, Redmond HP. Taurolidin in der Tumorthherapie – Vorstellung eines neuen Therapiekonzeptes. *UNI-MED Science*; 2003, First Edition.
- [7] Sun BS, Wang JH, Liu LL, Gong SL, Redmond HP. Taurolidine induces apoptosis of murine melanoma cells *in vitro* and *in vivo* by modulation of the Bcl-2 family proteins. *J Surg Oncol* 2007;27:241–8.
- [8] Braumann C, Schoenbeck M, Menenakos C, Kilian M, Jacobi CA. Effects of increasing doses of a bolus injection and an intravenous long-term therapy of taurolidine on subcutaneous (metastatic) tumor growth in rats. *Clin Exp* 2005;22:77–83.
- [9] Opitz I, Van der Veen H, Witte N, Braumann C, Mueller JM, Jacobi C. Instillation of taurolidine/heparine after laparotomy reduces intraperitoneal tumour growth in a colon cancer rat model. *Eur Surg Res* 2007;39:129–35.
- [10] Jemal A, Siegel R, Ward E, Murray T, Xu J, Smigal C, Thun MJ. Cancer statistics, 2006. *CA Cancer J Clin* 2006;56:106–30.
- [11] van Schaik PM, Hermans E, van der Linden JC, Pruijt JRM, Ernst MF, Bosscha K. Micro-metastases in stages I and II colon cancer are a predictor of the development of distant metastases and worse disease-free survival. *Eur J Surg Oncol* 2009;5:492–6.
- [12] Stoecklein NH, Hosch SB, Bezler M, Stern F, Hartmann CH, Vay C, Siegmund A, Scheunemann P, Schurr P, Knoefel WT, Verde PE, Reichelt U, Erbersdobler A, Grau R, Ultrich A, Izbicki JR, Klein CA. Direct genetic analysis of single disseminated cancer cells for prediction of outcome and therapy selection in esophageal cancer. *Cancer Cell* 2008;5:441–53.
- [13] Kobayashi H, Mochizuki H, Sugihara K, Morita T, Kotake K, Teramoto T, Kameoka S, Saito Y, Takahashi K, Hase K, Oya M, Maeda K, Hirai T, Kameyama M, Shirouzu K, Muto T. Characteristics of recurrence and surveillance tools after curative resection for colorectal cancer: a multicenter study. *Surgery* 2007;1:67–75.
- [14] Köhne CH, Cunningham D, Di Costanzo F, Glimelius B, Blijham G, Aranda E, Scheithauer W, Rougier P, Palmer M, Wils J, Baron B, Pignatti F, Schöffski P, Miceel S, Hecker H. Clinical determinants of survival in patients with 5-fluorouracil-based treatment for metastatic colorectal cancer: results of a multivariate analysis of 3825 patients. *Ann Oncol* 2002;13:308–17.
- [15] Opitz I, Lardinois D, Arni S, Hillinger S, Vogt P, Odermatt B, Rousson V, Weder W. Local recurrence model of malignant pleural mesothelioma for investigation of intrapleural treatment. *Eur J Cardiothorac Surg* 2007;5:773–8.
- [16] Kilian M, Gregor JI, Heukamp I, Braumann C, Guski H, Schimke I, Walz MK, Jacobi CA, Wenger FA. Impact of taurolidine and octreotide on liver metastasis and lipid peroxidation after laparoscopy in chemical induced ductal pancreatic cancer. *Invest New Drugs* 2005;23:157–64.

- [17] Han Z, Ribbizi I, Pantazis P. The antibacterial drug taurolidine induces apoptosis by a mitochondrial cytochrome c-dependent mechanism. *Anticancer Res* 2002;22:1959–64.
- [18] Stendel R, Stoltenburg-Didinger G, Al Keikh CL, Wattrodt M, Brock M. The effect of taurolidine on brain tumor cells. *Anticancer Res* 2002;2A:809–14.
- [19] Lanfrancione L, Boraschi D, Ghiara P, Falini B, Grignani F, Peri G, Mantovani A, Pelicci PG. Human peritoneal mesothelial cells produce many cytokines (granulocyte colony-stimulating factor [CSF], granulocyte–monocyte-CSF, macrophage-CSF, interleukin-1 [IL-1], and IL-6) and are activated and stimulated to grow by IL-1. *Blood* 1992;11:2835–42.
- [20] Van Antwerp DJ, Martin SJ, Verma IM, Green DR. Inhibition of TNF-induced apoptosis by NF-kappa B. *Trends Cell Biol* 1998;3:107–11.
- [21] McCourt M, Wang JH, Sookhai S, Redmond HP. Taurolidine inhibits tumor cell growth in vitro and in vivo. *Ann Surg Oncol* 2000;9:685–91.