

## ***Ixodes ricinus* L.: mast cells, basophils and eosinophils in the sequence of cellular events in the skin of infested or re-infested rabbits**

M. BROSSARD and V. FIVAZ

*Institut de Zoologie, Université, Chantemerle 22,  
CH-2000 Neuchâtel, Switzerland*

(Accepted 22 March 1982)

### SUMMARY

Some information on acquired resistance of rabbits against *Ixodes ricinus* ticks has been obtained by comparing tissue changes and cellular infiltration during 2 successive infestations, with particular emphasis on the cells involved in immediate type hypersensitivity reactions: mast cells, basophils and eosinophils. More degranulated mast cells were observed in tick lesions 2 h after the beginning of re-infestation than in the first infestation and more degranulated basophils were present on the 5th day of re-infestation. Numerous eosinophils infiltrated the dermis, especially on the 5th day of the second infestation.

### INTRODUCTION

Rabbits develop resistance against ticks after a single infestation (Bowessidjaou, Brossard & Aeschlimann, 1977) and tick nutrition and egg laying are partly disturbed. In this paper, we compare the tissue transformations and cellular infiltration around the tick rostrum during 2 sequential infestations. Rabbits are known to develop local immediate type hypersensitivity to ticks, and we have shown the presence of homocytotropic antibodies by Prausnitz-Küstner's test (Brossard, unpublished observations). Consequently, we have followed the evolution of skin mast cells, which are the effector cells of this reaction. Using a basophil degranulation test Benveniste, Egido, Guttierrez Millet & Camussi (1977) and Brossard, Monneron & Papatheodorou (1982) have shown that these cells progressively acquire a sensitivity to salivary antigens of ticks. Therefore, we have also considered the quantitative and qualitative evolution of this type of leucocyte. Eosinophils are regulatory cells of immediate type hypersensitivities (Gleich, 1977), attracted by mediators liberated during the degranulation of mast cells and basophils (for example ECF-A). During the 2 infestations carried out, we have therefore counted eosinophils in the lesions produced by ticks. Neutrophils and lymphocytes have also been considered in this study.

### MATERIALS AND METHODS

*Ixodes ricinus* ticks are reared routinely in our laboratory and the conditions of infestation have been described elsewhere (Bowessidjaou *et al.* 1977). Briefly, we

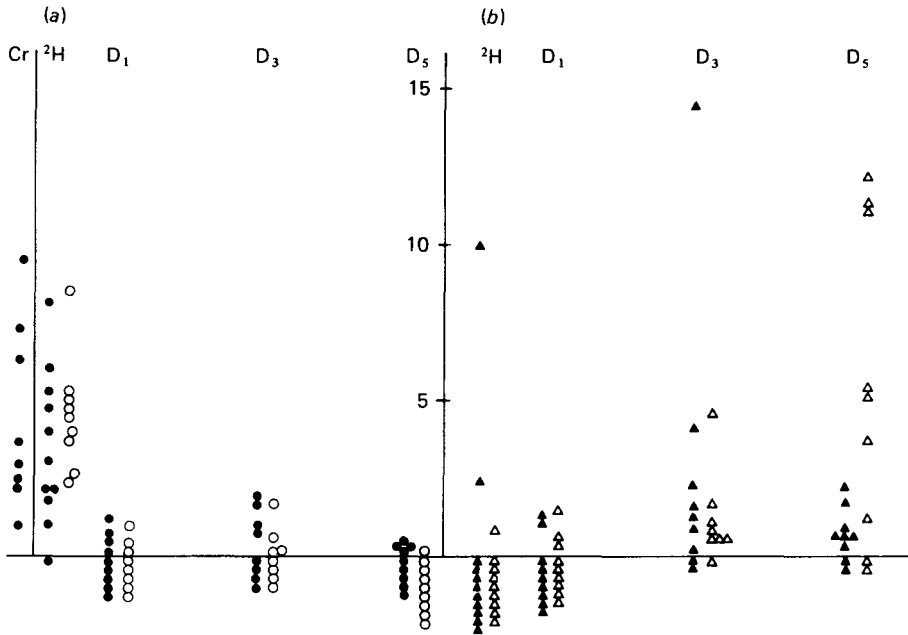


Fig. 1. Total mast cells (a) and basophils (b)/mm<sup>2</sup> in the skin of control rabbits or rabbits infested with *Ixodes ricinus*. In this and in subsequent figures each tick is represented by a symbol, black for the control or animals infested for the first time; white for the re-infested ones. The absence of cells in a lesion is pointed out by symbols under the abscissa. Cr, Control rabbits; 2H, D1, D3 and D5, observations made after 2 h, 1, 3 and 5 days of infestation or re-infestation.

infested one ear of Himalayan breed male rabbits (aac<sup>h</sup>c<sup>h</sup>), weighing about 2 kg, with 10 ♀♀ and 10 ♂♂ *I. ricinus*. In this species only the females feed, the males being used to fertilize the females allowing them to complete their blood meal. We re-infested the other ear of all animals with the same number of ticks 3 weeks later. At 2 h, 1, 3 or 5 days after the beginning of the infestation or re-infestation, 3 rabbits were killed. As a rule, 3 pieces of ear, with an attached tick, were taken off each animal surgically: exceptionally, 5 pieces of ear were removed from a rabbit infested for 2 h, and 2 pieces from another re-infested for 3 days. The tissues were fixed with 3% glutaraldehyde and 1% osmium tetroxide and embedded in Spurr resin. The sections (0.8 μm) were stained with 1% Toluidine blue. On 2 skin sections, cut lengthwise through the hypostome, mast cells and leucocytes (basophils, eosinophils, lymphocytes and neutrophils) were identified and counted. The total area of infiltrated skin (1–4 mm<sup>2</sup>) was examined. Each point in the figures 1–5 represents the number of cells/mm<sup>2</sup> counted for each tick (generally 3 ticks/rabbit). Eight pieces of rabbit ear, removed from 3 animals which had never been in contact with ticks, were prepared similarly to serve as controls. With this staining, normal or degranulated mast cells and basophils showed respectively many or few metachromatic granules.

For the classical van Gieson and haematoxylin–eosin stains, and in order to study the effect of collagenase, the pieces of skin were fixed in an aqueous solution of

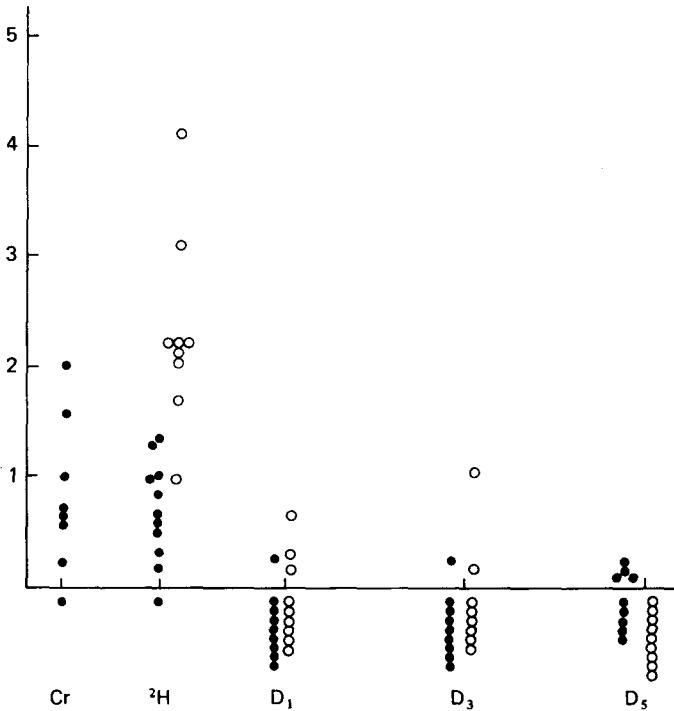


Fig. 2. Degranulated mast cells/mm<sup>2</sup> in the skin of control rabbits or rabbits infested with *Ixodes ricinus*. Explanations as for Fig. 1.

Bouin's fixative, embedded in paraffin and cut as 5–7  $\mu$ m sections. Collagenase was used at a concentration of 1 mg/ml in 0.3% NaCl for 60 min in a humid atmosphere at 50 °C.

## RESULTS

### *Common tissue phenomena observed during infestation and re-infestation*

The tick's rostrum penetrated deeply into the dermis (hypostome and chelicerae) and, sometimes, the ear cartilage was pierced (the phenomenon could be observed as early as 2 h after fixation of the tick, Pl. 1 A).

At the end of the first day of infestation, the rostrum was surrounded by an eosinophilic substance (haematoxylin–eosin stain, Pl. 1 B). This homogeneous zone was well marked by a red stain (van Gieson's method). It was composed of very tight fibres of collagen and was effectively digested by application of collagenase. As Stevens (1968) demonstrated, *I. ricinus* probably does not produce cement.

Three days after the beginning of infestation or re-infestation, a cavity formed under the mouthparts (Pl. 1 C). *I. ricinus* females probably fed partly on lysed tissues.

From the beginning of infestation, a great number of leucocytes infiltrated the dermis surrounding the mouthparts but not the epidermis.

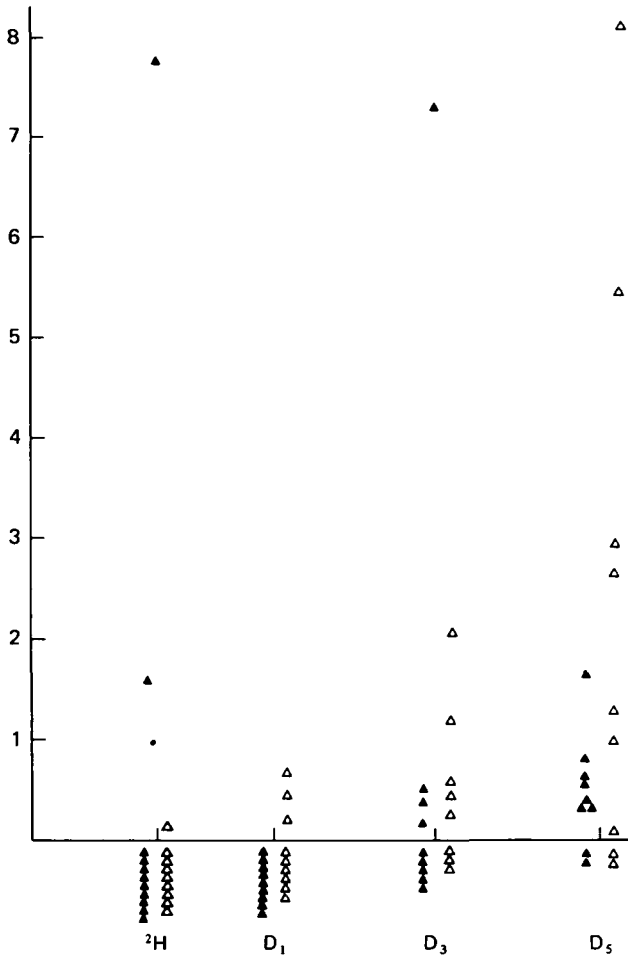


Fig. 3. Degranulated basophils/mm<sup>2</sup> in the skin of rabbits infested with *Ixodes ricinus*. Explanations as for Fig. 1.

### *Differential and sequential counting of infiltrating cells*

#### *Preliminary remark*

Since very few leucocytes infiltrated the ear skin of control rabbits, they are not shown on Figs 1, 3–5. Thereafter, the number/mm<sup>2</sup> of each type of infiltrating cell is given for each tick lesion observed 2 h, 1, 3 or 5 days after the beginning of infestation or re-infestation. Some of the major variations observed are described as follows.

#### *Mast cells (Pl. 2A, B)*

The total number of mast cells was small and similar to that in the control tegument and 2 h after the beginning of infestation (Fig. 1a). At the end of the first day, their number decreased. In control animals or in animals which had been infested for only 2 h, the number of degranulated mast cells was similar (Fig. 2). In only 2 cases were these cells not detected. At the beginning of re-infestation,

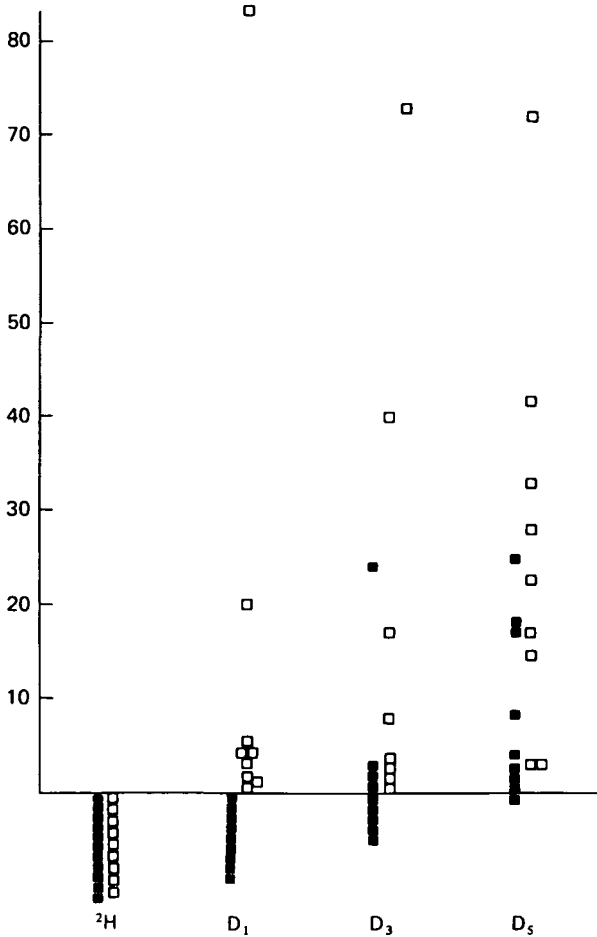


Fig. 4. Eosinophils in the skin of rabbits infested with *Ixodes ricinus*. Explanations as for Fig. 1.

degranulated mast cells were generally more numerous. At the end of the first day of infestation or re-infestation, their number decreased (Fig. 2) and in most cases they were no longer observable.

#### *Basophils* (Pl. 2C, D)

In only 2 tick lesions was the infiltration of basophils intensive during a first infestation (Fig. 1*b*, after 2 h and after 3 days). Generally, after 2 h or after the 1st day of infestation or re-infestation, few basophils infiltrated the tegument (Fig. 1*b*). This cellular type was more frequent after 3 days of tick attachment. On the 5th day, we observed an influx of basophils in re-infested animals, although there were always a few lesions which did not show this type of cell.

Except for 2 tick lesions, degranulated basophils appeared belatedly in the primarily infested animals (Fig. 3). On the 5th day, in at least 4 tick lesions, a greater number of these basophils infiltrated the re-infested animals. In 2 lesions

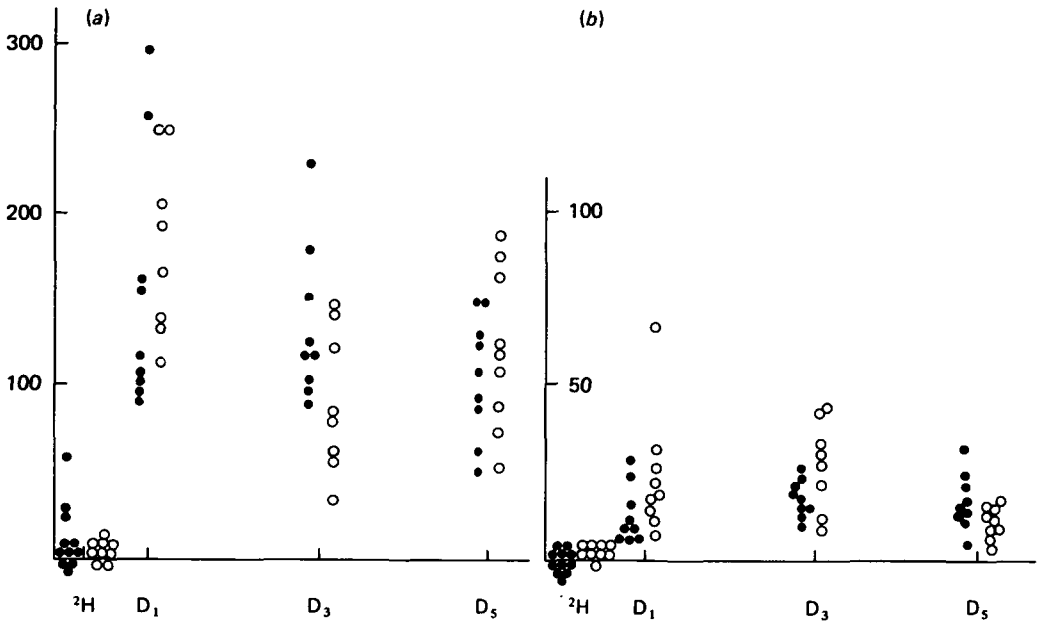


Fig. 5. Neutrophils (a) and lymphocytes (b)/mm<sup>2</sup> in the skin of rabbits infested with *Ixodes ricinus*. Explanations as for Fig. 1.

out of 9 no normal or degranulated basophils were observed in the 3 infested or 3 re-infested animals.

#### *Eosinophils* (Pl. 2E)

Two hours after the beginning of infestation or re-infestation, no eosinophil infiltration into the tick lesions was observed (Fig. 4). In rabbits, on first infestation, 4 tick lesions contained some eosinophils after 3 days. On the 5th day, all the lesions – with 1 exception – showed this type of leucocyte. After the 1st day of re-infestation, eosinophils were seen in all the lesions. Subsequently, they were always present. In 4 tick lesions, after 5 days, this infiltration was also more intense than in those observed during the first infestation.

#### *Neutrophils and lymphocytes*

Two hours after the beginning of infestation or re-infestation, few neutrophils and lymphocytes were detected. After 1 day, a great number of these cells infiltrated the tegument. From a quantitative point of view it was impossible to detect a difference from one infestation to the other (Fig. 5).

### DISCUSSION

In previous studies, we have shown that rabbits infested with *I. ricinus* females acquire a resistance that disturbs the 'blood' feeding and egg laying of ticks (Bowessidjaou *et al.* 1977). By passive injection of immune serum we have managed to partially transfer this immunity (Brossard, 1977; Brossard & Girardin, 1979).

The 'anti-tick salivary gland' antibodies detected by indirect immunofluorescence (Brossard, 1976) could neutralize certain salivary products and could perhaps also react with the intestinal epithelium of ticks, thus preventing normal feeding and digestion.

In order to add to our knowledge of the immunity developed by rabbits, we carried out the present histopathological study. During *I. ricinus* attachment, a cavity is formed at the distal extremity of the mouthparts. The ectoparasites probably feed on the lysed tissue and blood cells contained in this cavity. The composition and quantity of cells invading the rabbit tegument near the mouthparts alters during infestation and there are differences from one infestation to the other. In dogs parasitized by *Rhipicephalus sanguineus*, the neutrophils which penetrate the skin produce a cavity similar to that described above (Tatchell & Morhouse, 1970). Berenberg, Ward & Sonnenshine (1972) showed that salivary gland extract of *Dermacentor variabilis* produces chemotactic activity for neutrophils on incubation with dog, human or mouse serum or with purified human C<sub>5</sub>. This non-immunological reaction would explain the local influx of neutrophils in rabbit skin after the first day of infestation or re-infestation with *I. ricinus*, and the subsequent formation of a cavity (Fig. 5).

Mast cell breakdown occurs in dogs infested or re-infested with *R. sanguineus* (Theis & Budwiser, 1974). During this process, chemo-attractants for other cell types (for example, basophils and eosinophils) could be released. In rabbits infested with *I. ricinus*, certain mast cells observed near the mouthparts of ticks were degranulating and, at the beginning of re-infestation, the number of degranulated cells increases. At this time, some of these cells are undoubtedly sensitized by specific homocytotropic antibodies (IgE) and would degranulate specifically after contact with salivary antigens (immediate type hypersensitivity). In fact, Brossard (unpublished observations) detected such IgE antibodies in infested rabbits and also isolated a salivary allergen of approximate molecular weight  $14.5 \times 10^3$  Daltons.

In guinea-pigs infested by *Dermacentor andersoni*, a great number of basophils invade the skin (Allen, 1973). In our study, these cells infiltrated the dermis around the rostrum of *I. ricinus* less intensely. Their total number increased during infestation, particularly during re-infestation (Fig. 1*b*). Many of them were degranulated, especially during the second infestation (Fig. 3). These leucocytes could have lost their granules because of a reaction similar to the cutaneous basophil anaphylaxis described by Askenase, Debernardo, Tauben & Kashgarian (1978). We have shown with a degranulation test (see Benveniste *et al.* 1977) that these cells have become progressively sensitive to salivary antigens from the end of a first infestation (Brossard *et al.* 1982).

Vasoactive amines liberated by mast cells and basophils could then be harmful for the ticks. In cattle parasitized by *Boophilus microplus*, the early detachment of the larvae follows the release of histamine at the attachment site. In fact, experimentally, detachment has been reported to occur after the injection of this substance under the said site (Kemp & Bourne, 1980). In another parasitological system, guinea-pigs infested by an intestinal nematode (*Trichostrongylus colubriformis*), Rothwell, Prichard & Love (1974) suggest that histamine and serotonin alter the physiology of the worms and provoke their rejection more rapidly. These

substances, by increasing vascular permeability, would facilitate the local influx of cells, of serum and of specific protective antibodies. Histamine seems to be involved in the resistance acquired by rabbits to ♀♀ *I. ricinus*. Daily treatment of animals with the H<sub>1</sub>-antihistaminic mepyramine inhibited the effects of immunity on the ticks (Brossard, 1982).

On the 5th day of the first infestation, and particularly at the 5th day of re-infestation, a great number of eosinophils infiltrated the dermis (Fig. 4). This was also observed in cattle parasitized by *Ixodes holocyclus* (Allen, Doube & Kemp, 1976). They could be attracted to the mouthparts of the ticks by a chemotactic factor (ECF-A: Kay & Austen, 1971; Kay, Stechschulte & Austen, 1971), by antigen-antibody complexes (Kay & Austen, 1972), or by histamine (Clark, Gallin & Kaplan, 1975) liberated during mast cell and basophil degranulation. Eosinophils may control the intensity of the hypersensitivity reactions by producing an inhibitor of histamine liberation (Hubscher, 1975), or histaminase (Zeiger, Yurdin & Colten, 1976). If vasoactive amines are protective substances (see above), the mediators produced by the eosinophils would then decrease host immunity against ectoparasites, but other substances produced by these cells might disturb the metabolism of the ectoparasites and could perhaps damage their intestinal epithelium. Butterworth, Sturrock, Houba, Mahmoud, Sher & Rees (1975) and Butterworth, Wassom, Gleich, Loegering & David (1979) have shown that the external tegument of *Schistosoma mansoni*, in close contact with eosinophils, was damaged by the lysosomal products of these cells, or more specifically by peroxidase and the major basic protein.

This work was supported by the Swiss National Science Foundation (grant no. 3.303-78).

#### REFERENCES

- ALLEN, J. R. (1973). Tick resistance: basophil in skin reactions of resistant guinea-pigs. *International Journal for Parasitology* **3**, 195-200.
- ALLEN, J. R., DOUBE, B. M. & KEMP, D. H. (1976). Histology of bovine skin reactions to *Ixodes holocyclus* Neumann. *Canadian Journal of Comparative Medicine* **41**, 26-35.
- ASKENASE, P. W., DEBERNARDO, R., TAUBEN, D. & KASHGARLAN, M. (1978). Cutaneous basophil anaphylaxis. Immediate vasopermeability increases and anaphylactic degranulation of basophils at delayed hypersensitivity reactions challenged with additional antigen. *Immunology* **35**, 741-55.
- BENVENISTE, J., EGIDO, J., GUTTIERREZ MILLET, V. & CAMUSSI, G. (1977). Detection of immediate hypersensitivity in rabbits by direct basophil degranulation. *Journal of Allergy and Clinical Immunology* **59**, 271-9.
- BERENBERG, K. L., WARD, P. A. & SONNENSHINE, D. E. (1972). Tick-bite injury: Mediation by a complement-derived chemotactic factor. *Journal of Immunology* **108**, 451-6.
- BOWESSIDJAOU, J., BROSSARD, M. & AESCHLIMANN, A. (1977). Effects and duration of resistance acquired by rabbits on feeding and egg laying in *Ixodes ricinus* L.. *Experientia* **33**, 528-30.
- BROSSARD, M. (1976). Relations immunologiques entre Bovins et Tiques, plus particulièrement entre Bovins et *Boophilus microplus*. *Acta tropica* **33**, 15-36.
- BROSSARD, M. (1977). Rabbits infested with adult *Ixodes ricinus* L.: passive transfer of resistance with immune serum. *Bulletin de la Société de Pathologie Exotique* **70**, 289-94.
- BROSSARD, M. (1982). Rabbits infested with adult *Ixodes ricinus* L.: effects of mepyramine on acquired resistance. *Experientia* (in the Press).
- BROSSARD, M. & GIRARDIN, P. (1979). Passive transfer of resistance in rabbits infested with adult *Ixodes ricinus* L.: humoral factors influence feeding and egg laying. *Experientia* **35**, 1395-6.



- BROSSARD, M., MONNERON, J.-P. & PAPTAEODOROU, V. (1982). Progressive sensitization of circulating basophils against *Ixodes ricinus* L. antigens during repeated infestations of rabbits. *Parasite Immunology* (in the Press).
- BUTTERWORTH, A. E., STURROCK, R. F., HOUBA, V., MAHMOUD, A. A. F., SHER, A. & REES, P. H. (1975). Eosinophils as mediators of antibody-dependent damage to schistosomula. *Nature, London* **256**, 727-9.
- BUTTERWORTH, A. E., WASSOM, D. L., GLEICH, G. J., LOEGERING, D. A. & DAVID, J. R. (1979). Damage to schistosomula of *Schistosoma mansoni* induced directly by eosinophil major basic protein. *Journal of Immunology* **122**, 221-9.
- CLARK, R. A. F., GALLIN, J. I. & KAPLAN, A. P. (1975). The selective eosinophil chemotactic activity of histamine. *Journal of Experimental Medicine* **142**, 1462-76.
- GLEICH, G. J. (1977). The eosinophil: Structure and biochemical composition. *American Journal of Tropical Medicine and Hygiene* **26**, 126-33.
- HUBSCHER, T. (1975). Role of the eosinophil in the allergic reaction. I. EDI - an eosinophil-derived inhibitor of histamine release. *Journal of Immunology* **114**, 1379-88.
- KAY, A. B. & AUSTEN, K. F. (1971). The IgE-mediated release of an eosinophil leucocyte chemotactic factor from human lung. *Journal of Immunology* **107**, 899-902.
- KAY, A. B. & AUSTEN, K. F. (1972). Antigen-antibody induced cutaneous eosinophilia in complement-deficient guinea-pigs. *Clinical and Experimental Immunology* **11**, 37-42.
- KAY, A. B., STECHSCHULTE, D. J. & AUSTEN, K. F. (1971). An eosinophil leucocyte chemotactic factor of anaphylaxis. *Journal of Experimental Medicine* **133**, 602-19.
- KEMP, D. H. & BOURNE, A. (1980). *Boophilus microplus*: the effect of histamine on the attachment of cattle-tick larvae - studies *in vivo* and *in vitro*. *Parasitology* **80**, 487-96.
- ROTHWELL, T. L. W., PRICHARD, R. K. & LOVE, R. J. (1974). Studies on the role of histamine and 5-hydroxytryptamine in immunity against the nematode *Trichostrongylus colubriformis*. *In vivo* and *in vitro* effects of the amines. *International Archives of Allergy and Applied Immunology* **46**, 1-13.
- STEVENS, E. (1968). Tick feeding in relation to disease transmission. Ph.D. thesis, University of London.
- TATCHELL, R. J. & MORHOUSE, D. E. (1970). Neutrophils: their role in the formation of a tick lesion. *Science* **167**, 1002-3.
- THEIS, J. H. & BUDWISER, P. O. (1974). *Rhipicephalus sanguineus*: Sequential histopathology of the host arthropod interface. *Experimental Parasitology* **36**, 77-105.
- ZEIGER, R. S., YURDIN, D. L. & COLTEN, H. R. (1976). Histamine metabolism. II. Cellular and subcellular localization of the catabolic enzymes, histaminase and histamine methyl transferase, in human leucocytes. *Journal of Allergy and Clinical Immunology* **58**, 172-9.

## KEY TO LETTERING OF PLATES

<i>b</i>	normal basophil	<i>dm</i>	degranulated mast cell
<i>c</i>	chelicerae	<i>e</i>	eosinophil
<i>ca</i>	cavity	<i>ep</i>	epidermis
<i>co</i>	collagen	<i>h</i>	hypostome
<i>ct</i>	cartilage	<i>m</i>	normal mast cell
<i>d</i>	infiltrated dermis	<i>n</i>	neutrophil
<i>db</i>	degranulated basophil		

## EXPLANATION OF PLATES

## PLATE 1

Histopathological appearance of the skin of rabbits infested by *Ixodes ricinus* females.

A. Longitudinal section of a tick hypostome perforating the cartilage of the ear.

B. Cross-section of tick mouthparts surrounded by a dense zone of collagen.

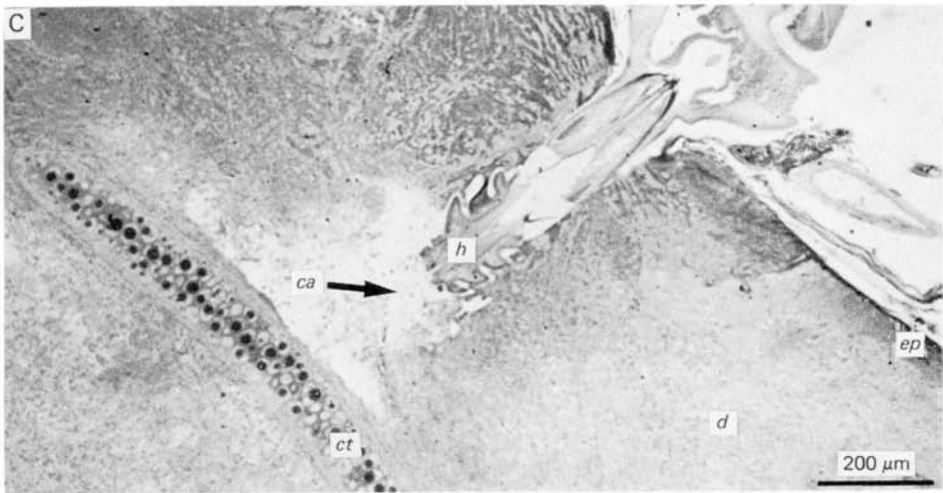
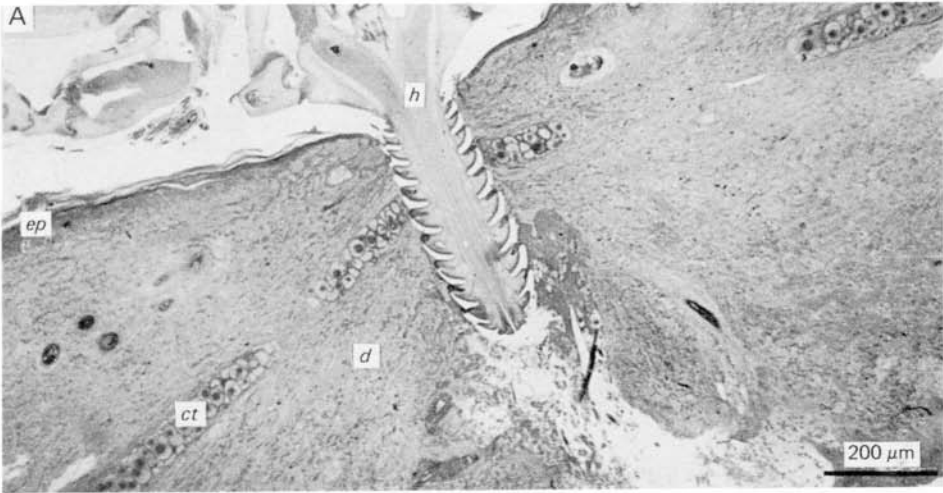
C. Cavity at the distal extremity of tick mouthparts.

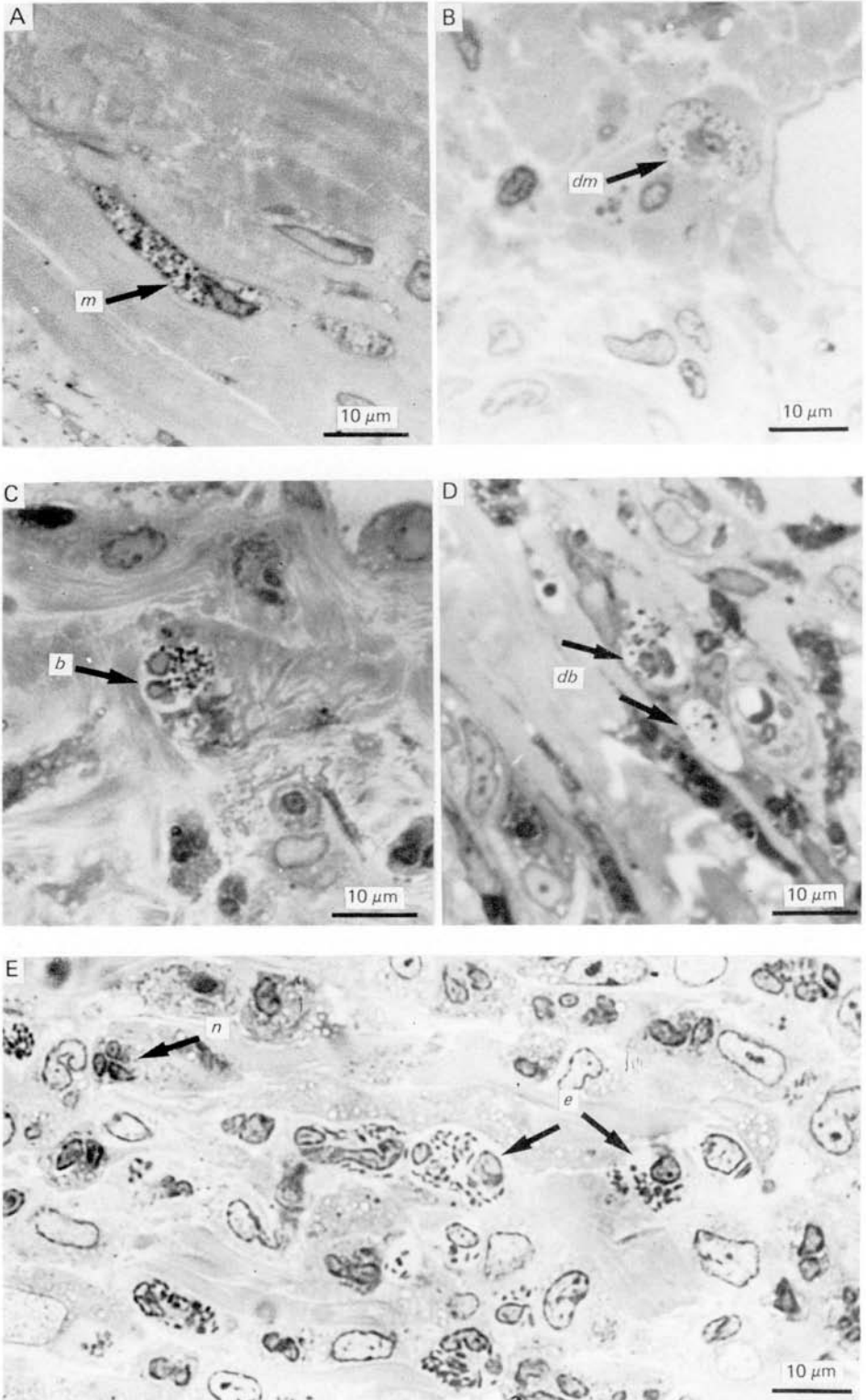
## PLATE 2

Details of histopathological skin of rabbits infested by *Ixodes ricinus* females.

- A. Normal mast cell.
- B. Degranulated mast cell.
- C. Normal basophil.
- D. Degranulated basophils.
- E. Eosinophils.

*Printed in Great Britain*





M. BROSSARD AND V. FIVAZ