



ELSEVIER

European Journal of Cardio-thoracic Surgery 13 (1998) 170–175

 EUROPEAN JOURNAL OF
 CARDIO-THORACIC
 SURGERY

Transmyocardial laser revascularisation in acutely ischaemic myocardium¹

Xavier M. Mueller^{a,*}, Hendrik H. Tevaearai^a, Claude-Yves Genton^b, Dominique Bettex^c,
 Ludwig K. von Segesser^a

^a Clinic for Cardiovascular Surgery, CHUV (Centre Hospitalier Universitaire Vaudois), CH-1011 Lausanne, Switzerland

^b Institute of Pathology, CHUV (Centre Hospitalier Universitaire Vaudois), CH-1011 Lausanne, Switzerland

^c Department of Anaesthesia, CHUV (Centre Hospitalier Universitaire Vaudois), CH-1011 Lausanne, Switzerland

Received 30 September 1997; received in revised form 10 November 1997; accepted 19 November 1997

Abstract

Objective: Although recent experience suggests that transmyocardial laser revascularisation (TMLR) relieves angina, its mechanism of action remains undefined. We examined its functional effects and analysed its morphological features in an animal model of acute ischaemia. **Methods:** A total of 15 pigs were randomised to ligation of left marginal arteries (infarction group, $n = 5$), to TMLR of the left lateral wall using a holmium:yttrium–aluminium garnet (Ho:YAG) laser (laser group, $n = 5$), and to both (laser–infarction group, $n = 5$). All the animals were sacrificed 1 month after the procedure. Haemodynamics and echocardiography with segmental wall motion score were carried out at both time intervals (scale 0–3: 0, normal; 1, hypokinesia; 2, akinesia; 3, dyskinesia). Histology of the involved area was analysed. **Results:** Laser group showed no change of the segmental wall motion score of the involved area 30 min after the laser channels were made (score: 0 ± 0). Infarction and laser–infarction groups both showed a persistent and definitive increase of the segmental wall motion score (at 30 min: 1.6 ± 0.3 and 2 ± 0 , respectively; at 1 month: 1.8 ± 0.2 and 1.8 ± 0.4 , respectively). These increases were all statistically significant in comparison with baseline values ($P < 0.5$), however comparison between infarction and laser–infarction groups showed no significant difference. On macroscopic examination of the endocardial surface, no channel was opened. On histology, there were signs of neovascularisation around the channels in the laser group, whereas in the laser–infarction group the channels were embedded in the infarction scar. **Conclusions:** In this acute pig model, TMLR did not provide improvement of contractility of the ischaemic myocardium. To the degree that the present study pertains to the clinical setting, the results suggest that mechanisms other than blood flow through the channels should be considered, such as a laser-induced triggering of neovascularisation or neural destruction. © 1998 Elsevier Science B.V. All rights reserved.

Keywords: Laser; Revascularization; Myocardium

1. Introduction

Coronary artery disease remains the leading cause of death in the Western world. Despite proven methods of treatment such as percutaneous transluminal coronary

angioplasty and coronary artery bypass grafting, many patients have distal or diffuse coronary artery disease, that are not amenable to these therapies.

In the early 1980s, Mirhoseini and Cayton [1] were the first to propose using a laser to drill channels through the myocardium in order to improve the blood supply directly from the left ventricular cavity to the ischaemic areas. Results of clinical trials uniformly indicate that transmyocardial laser revascularisation (TMLR) significantly reduces angina [2–4] and two

* Corresponding author. Tel.: +41 21 3142280; fax: +41 21 3142278; e-mail: Xavier.Mueller@chuv.hospvd.ch

¹ Presented at the 11th Annual Meeting of the European Association for Cardio-thoracic Surgery, Copenhagen, Denmark, September 28–October 1, 1997.

groups suggest that over time there is improved regional blood flow in treated areas [5,6].

The mechanism of action of the laser procedure remains largely undefined. It is not clear, whether laser-induced channels remain open for prolonged time or whether the beneficial effects of the procedure stem from the channels created or from a subsidiary adaptation elicited by other components of the laser such as a laser-induced triggering of neovascularisation or a laser-induced inhibition of pain.

The basis for attempting TMLR in patients came from positive results obtained in several canine experiments. However dogs are known for their native collaterals making them unsuitable for comparison with man. Therefore we sought to examine the long-term effects of TMLR in an animal with few native collaterals, the pig. The purpose of the study was two-fold, first to examine the haemodynamic and echocardiographic consequences of TMLR on the acutely ischaemic myocardium and second to analyse its macroscopic and microscopic features.

2. Material and methods

2.1. Laser variables

To create the laser channels, we used a holmium:yttrium–aluminium garnet (Ho:YAG) laser (CardioGenesis TMLR System, Santa Clara, CA) which emits a burst of three pulses of energy at the 2.1 μm wavelength, which is invisible radiation in the mid-infrared portion of the spectrum. The pulse width is 350 μs in duration. The output of the Ho:YAG laser is focused into a 365 μ core diameter low-OH quartz fibre with a cylindrical tip (1.75 mm diameter). A 633 nm helium neon laser beam is used as an aiming beam. The pulse repetition rate is 16 Hz for a burst of three pulses and the energy per pulse is 2.0 J.

2.2. Animal preparation

The study was carried out in 15 pigs weighing between 52 and 78 kg (mean, 66.9 ± 9.8 kg). The animals were premedicated with Ketaminol (10 mg/kg) and Atropine (2 mg) injected intramuscularly. A vascular access was established through a vein of the ear. After induction with sodium thiopental (5 mg/kg) through this venous line, the animals were intubated and anaesthesia was maintained by intravenous administration of sodium thiopental as needed. Animals were ventilated with room air. Respiratory rate and stroke volume were adjusted to maintain arterial blood gases within the normal physiologic range. Three ECG leads were installed. A left lateral cervicotomy was carried out to provide vascular access. An arterial line was inserted

into the carotid artery and a Swan-Ganz catheter was inserted through the jugular vein into the pulmonary artery to measure pressures of the right-sided heart chambers with cardiac output monitoring. A left lateral thoracotomy was carried out through the fifth intercostal space. The pericardium was opened and reflected to form a cradle for suspending the heart. After 30 min for stabilisation after the completion of surgery, baseline haemodynamic and echocardiographic data were recorded. The haemodynamic data included the heart rate, the mean arterial pressure, the right atrial pressure, the mean pulmonary artery pressure, the pulmonary capillary wedge pressure, and the cardiac output. The echocardiography was carried out with the probe positioned on the epicardium at the mid-height of the left ventricle. A short-axis ejection fraction was recorded and the motility of the lateral segment was evaluated on a scale from 0 to 3 (0, normal; 1, hypokinesia; 2, akinesia; 3, dyskinesia).

2.3. Experimental protocol

The animals were randomised either to a myocardial infarction (MI) group or a TMLR group or a TMLR and MI (TMLR–MI) group. In the MI group, several marginal branches of the circumflex artery were ligated circumferentially at about the junction of their proximal and medial thirds, in order to induce an acute MI on the lateral wall of the left ventricle. In the TMLR group, five channels were drilled at the mid-height of the left lateral wall, 1 cm apart. The external opening of each channel was marked with a non-resorbable stitch, in order to identify them later for histology. In both groups haemodynamic and echocardiographic data were recorded at 5 and 30 min. In the TMLR–MI group, both procedures were carried out at 30-min intervals with the same controls at 5 and 30 min after each procedure. The drilling of the channels was carried out first in order to avoid use of the laser on an acutely ischaemic myocardium which would have carried a too high risk of intractable ventricular arrhythmias. At the end of the operation, the thoracotomy was closed on a chest tube which was removed after the weaning from the ventilator.

2.4. Control operation

After a month, the animals were anaesthetised according to the same protocol. A right lateral cervicotomy was carried out for access for an arterial line and a Swan-Ganz catheter. The previous thoracotomy was reopened and the left lateral myocardial wall was freed. After 30 min of stabilisation after the completion of surgery, baseline haemodynamic and echocardiographic data were recorded. Animals were then sacrificed with an intravenous bolus injection of saturated potassium

chloride and hearts were rapidly excised for fixation in buffered formaldehyde 4% for histology.

2.5. Histology

After explantation of the heart, the endocardium was examined for all the channel openings in order to assess their permeability. The necrotic area and/or the channels area were identified and a transmural block of tissue containing this area was created. The myocardium was then sectioned transversely, in an axis perpendicular to the channel axis at the mid-level of the myocardial thickness. The tissue was then dehydrated and embedded in paraffin. Sections were stained with haematoxylin and eosin and with Masson’s trichrome stain for microscopic analysis.

2.6. Statistics

Data are expressed as mean value ± 1 S.D. Mean values at different time intervals were compared with the initial baseline mean value using a *t*-test. The Wilcoxon signed rank test was used for comparing regional motility scores. In the TMLR–MI group, the values at 5 and 30 min after the ligation of the coronary arteries were compared with the values taken 30 min after the creation of the channels. Values were considered to differ significantly if *P* < 0.05.

3. Results

3.1. Haemodynamics

All the haemodynamical parameters were stable throughout the procedures in the three groups, as no values at any time interval differed significantly from baseline values.

3.2. Echocardiographic findings

The ejection fraction in the short-axis plane at the level of the laser channels showed a transient decrease 5 min after the creation of the channels in the TMLR group, whereas it was persistently depressed 5 and 30 min after the coronary arteries ligation in the MI group. The segmental motility score of the involved areas showed the same trend although the transient increase of the score at 5 min in the TMLR group was not significant (Fig. 1). In the TMLR–MI group, the same sequence of events was observed successively (Fig. 2). Comparison between the MI and the TMLR–MI groups of segmental motility scores 30 min and 1 month after the coronary arteries ligation did not show any statistical significance. The segmental motility score never exceeded one after TMLR in both TMLR and TMLR–MI groups.

3.3. Macroscopic evaluation of the laser channels

In the TMLR group the endocardial openings of the five channels of each heart were completely occluded by a whitish scarry tissue. The same findings were established in the TMLR–MI group where the endocardial scars of the channels were all embedded in the infarction scar. In the same group the epicardial openings were also within the infarction scar attesting that all the channels were actually drilled in the infarction area.

3.4. Microscopic examination of the laser channels

In the TMLR group, the majority of the channels had their central area entirely replaced by fibrous tissue. The channels exhibited an elliptic morphology. Not a single patent channel with a diameter comparable with that of the original channels was ever identified. The degree of vascularisation within the scar tissue replacing the channel lumen was variable, and included capillaries as well as arterioles. In the TMLR–MI group the channels were hardly distinguishable in the infarction

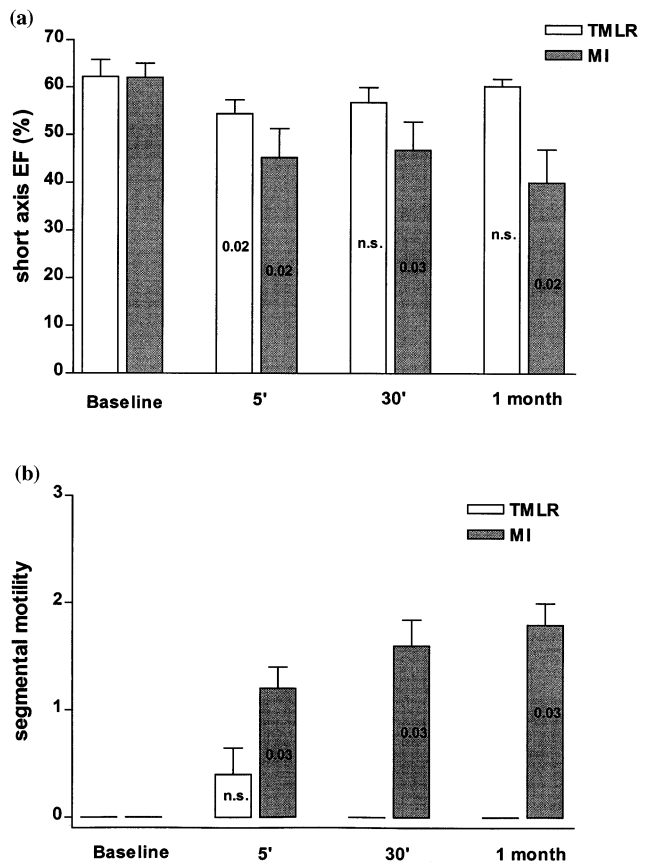


Fig. 1. Echocardiographic parameters recorded in the TMLR and MI groups, respectively. (a) Ejection fraction measured in the short axis view. (b) Segmental wall motion score of the lateral wall of the left ventricle. The figures in each column represent the *P*-value of the comparison with the baseline column. EF, ejection fraction; segmental motility, segmental wall motion score.

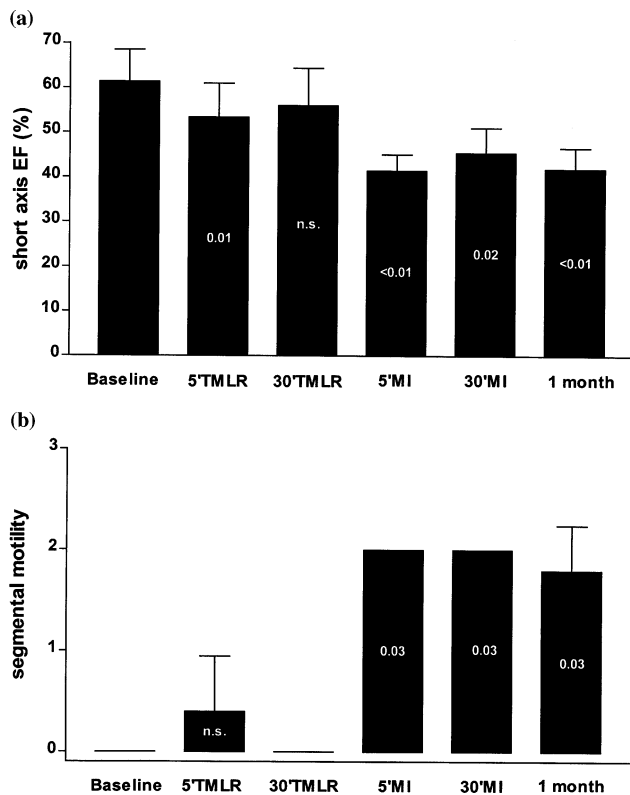


Fig. 2. Echocardiographic parameters recorded in the TMLR–MI group. (a) Ejection fraction measured in the short axis view. (b) Segmental wall motion score of the lateral wall of the left ventricle. The figures in the TMLR columns represent the *P*-value of the comparison with the baseline column, while the MI columns are compared with the value recorded 30 min after TMLR. Abbreviations as in Fig. 1.

scar. Residual proteinaceous material could be occasionally found in the channels.

4. Discussion

Much of the evidence concerning the beneficial effects of TMLR lies in clinical studies examining improvement in angina class and myocardial perfusion [6–8]. It is clear that TMLR provides some clinical improvement in many patients, but the mechanism by which myocardial laser injury is therapeutic remains controversial. In fact, the debate over long-term patency of channels as the primary mechanism for TMLR has intensified with accumulating experimental and clinical experience.

The results of this study demonstrate that there is no long-term benefit of TMLR on the acutely ischaemic myocardium in the pig model. On one hand there was no improvement of the segmental wall motion score and on the other hand there were neither macroscopic nor microscopic signs of protection of the involved myocardium even in the region directly adjacent to the

channels. In contrast, several studies have suggested that the presence of TMLR channels confers a physiologic benefit in the setting of acute ischaemia [8–10]. The reason for this discrepancy might lie in the different experimental models employed. Whether the model was a dog [8,9] or a sheep [10], none of these studies did take collateral blood flow into consideration. Further supporting this hypothesis, there is substantial evidence that laser-made channels cannot provide blood flow to ischaemic myocardium, either in dog hearts, when collateral flow was measured [11–14] or in pig hearts which have little collateral circulation [15].

The major potential limitation of the present study is that we have examined functional results and histology in acute (within 24 h) and subacute (up to 4 weeks) conditions. Although clinical studies have dealt with chronic ischaemia and long-term improvement of anginal symptoms, the results of animal models of acute ischaemia may provide important information for the understanding of the mechanism of action of the TMLR in the clinical application. Firstly, relief from angina has been reported to occur early after the procedure as neither unstable angina nor rehospitalisation for recurrent angina during the first 3 months following the procedure have been reported [6,16]. The lack of acute ventricular-derived blood through the channels is supported by our study and by others [11–14]. As neovascularisation has not had the time to develop, possible alternative explanations include induction of local 'anaesthesia' through destruction of myocardial efferent neural pathways. Secondly, recent studies on the rat myocardium showed that when an acute coronary occlusion was carried out 2 months after TMLR, a physiologically small but statistically significant protection was observed [17]. This phenomenon was not apparent in the acute setting. These findings suggest that different mechanisms might be involved in the physiology of acute and chronic channels. Data concerning angina relief in the chronic setting suggest that the effect is sustained over a time period of up to 2 years and may be associated with improved regional blood flow [5,16]. Results of positron emission tomography [6] and sestamibi [5] scanning studies have indicated that myocardial perfusion is improved in treated areas 3–6 months after the operation, with a statistically significant increase in the ratio between endocardial and epicardial myocardial perfusion.

An area of controversy lies in the number of channels drilled per area's unit. We chose to drill one channel per square centimetre for two reasons. Firstly, this was the channel density used in previous experimental studies [10,14]. Secondly, although various numbers of channels have been drilled in the clinical setting, the few studies describing the channel density reported one channel per square centimetre [5,6,18].

Previous histological studies in dogs and rats have casted doubts about the long-term patency of channels drilled with a CO₂ laser [12,19]. In our pig model, simple macroscopic analysis already demonstrates occlusion of the endocardial openings of all the channels by scar tissue in both TMLR and TMLR–MI groups. This observation clearly shows that channels created with a Ho:YAG laser are not able to bring blood directly from the endocardial surface toward myocardial tissue. Microscopically, the laser channels were invaded by an ingrowth of scar tissue with fibroblasts and new vessels. These newly formed vessels included capillaries, characteristic of granulation tissue, but also muscular arterioles, vessels that are rather uncommon in healing wounds. In addition to the vascular response, fibroblasts lay down collagen, resulting in occlusion of the channels by fibrosis. These histologic findings further support the inability of the channels to carry blood from the cardiac cavity. In the clinical setting there has been so far a single report from Cooley et al. [7], claiming long-term channel patency in a patient who died 3 months after the intervention. However the diameter of the so-called patent channels ranged between 20 and 75 μ m, in striking contrast to the original laser channels' diameters of almost 1 mm. These dimensions are in the same range as those of vascular structures observed within the scarred channel in our pigs. Therefore these 'patent channels' could be rather interpreted as 'channel remnants' rather than as truly endothelialised channels. Moreover one recent autopsy report of Burkoff et al. [20] in a patient who died 4 1/2 weeks after the TMLR procedure could not establish patent channels, but rather scarred channels with vascular structures within it. Thus histological descriptions might be misleading with regard to the interpretation of these vascular structures and careful macroscopical description of the endocardial opening should be mentioned. The elliptic morphology of the channels could be explained by the asymmetric distribution of thermal damage which can be seen as a more extensive zone of thermally altered tissue coaxial with the direction of myofibrils (i.e. along the fibres) as compared with the zone of thermal damage perpendicular to the direction of the myofibrils (i.e. across the fibres).

Our echocardiographic results correlate well with the macroscopic and the histological findings, as infarcted region showed persistent akinesia or dyskinesia whether TMLR was carried out or not. The transient hypokinesia observed in some animals 5 min after TMLR on healthy myocardium, might be due to the occasional lesion of an intramyocardial coronary artery branch. However this decrease of contractility always recovered after 30 min, suggesting a good myocardial tolerance to TMLR lesions.

Experimental studies, such as described in the present report, address issues of mechanism of action and do

not address issues of clinical effectiveness. Therefore, the negative findings of lack of acute channel blood flow and morphologic changes at 4 weeks do not in any way suggest lack of clinical efficacy to treat angina. However, it is important that the mechanism of clinical benefit of TMLR be elucidated. To the degree that the present study pertains to the clinical setting, the results suggest that mechanism(s) other than blood flow through the TMLR channels should be considered, such as neovascularisation stimulated by the scarring of the laser channels, or direct neural damage, or both at different time intervals.

References

- [1] Mirhoseini M, Cayton MM. Revascularization of the heart by laser. *J Microsurg* 1981;2:253–60.
- [2] Horvath KA, Cohn LH, Cooley DA, Crew JR, Frazier OH, Griffith BP, Kadipasaoglu K, Lansing A, Mannting F, March R, Mirhoseini MR, Smith C. Transmyocardial laser revascularization: results of a multicenter trial with transmyocardial laser revascularisation used as a sole therapy for end-stage coronary artery disease. *J Thorac Cardiovasc Surg* 1997;113:645–54.
- [3] Gassler N, Stubbe HM. Clinical data and histological features of transmyocardial laser revascularization with CO₂ laser. *Eur J Cardio-thorac Surg* 1997;12:25–30.
- [4] Vincent JG, Bardos P, Kruse J, Maas D. End stage coronary disease treated with the transmyocardial CO₂ laser revascularisation: a chance for the 'inoperable' patient. *Eur J Cardio-thorac Surg* 1997;11:888–94.
- [5] Horvath KA, Mannting F, Cummings N, Shernan S, Cohn LH. Transmyocardial laser revascularization: operative techniques and clinical results at two years. *J Thorac Cardiovasc Surg* 1996;111:1047–53.
- [6] Frazier OH, Cooley DA, Kadipasaoglu KA, Pehlivanoglu S, Lindenmeir M, Barasch E, Conger JL, Wilansky S, Moore WH. Myocardial revascularization with laser. Preliminary findings. *Circulation* 1995;92:II-58–65.
- [7] Cooley DA, Frazier OH, Kadipasaoglu KA, Pehlivanoglu S, Shannon RL, Angelini P. Transmyocardial laser revascularization. Anatomic evidence of long-term channel patency. *Tex Heart Inst J* 1994;21:220–4.
- [8] Mirhoseini M, Shelgikar S, Cayton MM. New concepts in revascularization of the myocardium. *Ann Thorac Surg* 1988;45:415–20.
- [9] Yano OJ, Bielefeld MR, Jeevanandam V, Treat MR, Marboe CC, Spotnitz HM, Smith CR. Prevention of acute regional ischemia with endocardial laser channels. *Ann Thorac Surg* 1993;56:46–53.
- [10] Horvath KA, Smith WJ, Laurence RG, Schoen FJ, Appleyard RF, Cohn LH. Recovery and viability of an acute myocardial infarct after transmyocardial laser revascularization. *J Am Coll Cardiol* 1995;25:258–63.
- [11] Whittaker P, Kloner RA, Przyklenk, K. Laser-mediated transmural channels do not salvage ischemic myocardium. *J Am Coll Cardiol* 1993;22:302–9.
- [12] Hardy RI, James FW, Millard RW, Kaplan S. Regional myocardial blood flow and cardiac mechanics in dog hearts with CO₂ laser-induced intramyocardial revascularization. *Basic Res Cardiol* 1990;85:179–97.
- [13] Landreneau R, Nawarawong W, Laughlin H, Riupperger J, Brown W, McDaniel W, NeKnown D, Curtis J. Direct CO₂ laser 'revascularization' of the myocardium. *Lasers Surg Med* 1991;11:35–42.

- [14] Kohmoto T, Fisher PE, Gu A, Zhu SM, DeRosa C, Smith CR, Burkhoff D. Physiology, histology, and 2-week morphology of acute transmural channel made with a CO₂-laser. *Ann Thorac Surg* 1997;63:1275–83.
- [15] Goda T, Wierbicki Z, Gaston A, Leandri J, Vouron J, Loisanse D. Myocardial revascularization by CO₂ laser. *Eur Surg Res* 1987;19:113–7.
- [16] Cooley DA, Frazier OH, Kadipasaoglu KA, Lindenmeir MA, Pehlivanoglu S, Kolff JW, Wilansky S, Moore WH. Transmyocardial laser revascularization: clinical experience with twelve month follow-up. *J Thorac Cardiovasc Surg* 1996;111:791–9.
- [17] Whittaker P, Rakusan K, Kloner RA. Transmural channels can protect ischemic tissue. Assessment of long-term myocardial response to laser and needle-made channels. *Circulation* 1996;93:143–52.
- [18] Krabatsch T, Dörschel K, Tülsner J, Hempel B, Hofmeister J, Lieback E, Hetzer R. Transmyocardial laser revascularization—Initial results in treating diffuse coronary disease. *Lasermedizin* 1995;11:192–8.
- [19] Owen ER, Canfield P, Bryant K, Hopwood PR. Observations of the effects of CO₂ laser on rat myocardium. *Microsurgery* 1984;5:140–3.
- [20] Burkhoff D, Fisher PE, Apfelbaum M, Kohmoto T, DeRosa CM, Smith CR. Histologic appearance of transmural laser channels after 4 1/2 weeks. *Ann Thorac Surg* 1996;61:1532–5.

Appendix A. Conference discussion

Dr F. Beyersdorf (*Freiburg, Germany*): Dr Mueller, is it correct that you have shown improvements in functional parameters whereas you could not show signs of tissue viability in the TMLR group? Our group has carried out TMLR in pigs before 6 h of coronary occlu-

sion. We found no improvement in perfusion but a decrease in triphenyltetrazolium chloride (TTC) non-staining in the laser groups. Obviously, in these TMLR experiments, there seem to be some contradictory findings if you look to all these parameters, because they do not fit all together. So what would be your explanation for the improvements in the regional contractility?

Dr X. Mueller: You mean for the laser group?

Dr F. Beyersdorf: Yes.

Dr X. Mueller: For the laser group actually there is no real improvement; there is a transient decrease of the ejection fraction and transient increase of the segmental wall motion score. And the most reasonable explanation would be that we probably hit some intramyocardial coronary branches during the procedure, which recovered after 30 min, and it might be due to the small size of these branches.

Dr J. Vaage (*Stockholm, Sweden*): I believe that both the Lausanne group and the Freiburg group do the TMLR before the infarction. That might be very important, because basically it could happen that the trauma induced by TMLR could induce a preconditioning response in the myocardium.

Dr O. Faber (*Debrecen, Hungary*): You suppose another mechanism. Did you find any neovascularisation in the group where you had infarction and laser?

Dr X. Mueller: In this group we saw few revascularisation signs in the channels area. In the laser group we felt there were more features of neovascularisation and especially, not only capillary structure, but arterials as well, which you do not find in normal scar tissue. But we don't have an explanation for that so far.

Dr T. Ferguson (*St. Louis, USA*): You have taken a normal myocardium that has a normal blood flow and you've traumatised it, and so repair is going to be a part of the process. Therefore wouldn't you expect to find neovascularisation?

Dr Mueller: Yes, of course. The question is whether this neovascularisation is increased in comparison with the normal scar tissue.