

Disclosure statement: The authors have declared no conflicts of interest.

Johan M. Lorenzen¹, Robert Krämer¹, Matthias Meier¹, Thomas Werfel², Katja Wichmann², Marius M. Hoepfer³, Gabriela Riemekasten⁴, Mike O. Becker⁴, Hermann Haller¹ and Torsten Witte⁵

¹Department of Medicine, Division of Nephrology and Hypertension, ²Department of Dermatology, Allergology and Venerology, ³Division of Pulmonary Medicine, Hanover Medical School, Hanover, ⁴Division of Rheumatology and Clinical Immunology and German Rheumatology Research Centre, Charité University Hospital, Berlin and ⁵Division of Immunology and Rheumatology, Hanover Medical School, Hanover, Germany.

Accepted 14 June 2010

Correspondence to: Johan M. Lorenzen, Division of Nephrology, Department of Medicine, Hanover Medical School, Carl-Neuberg-Strasse 1, 30625 Hanover, Germany. E-mail: j.m.lorenzen@gmail.com

References

- Black CM. The aetiopathogenesis of systemic sclerosis: thick skin–thin hypotheses. The Parkes Weber Lecture 1994. *J R Coll Physicians Lond* 1995;29:119.
- Systemic sclerosis: current pathogenetic concepts and future prospects for targeted therapy. *Lancet* 1996;347:1453.
- Mazzali M, Kipari T, Ophascharoensuk V, Wesson JA, Johnson R, Hughes J. Osteopontin—a molecule for all seasons. *Q J Med* 2002;95:3–13.
- Collins AR, Schnee J, Wang W *et al.* Osteopontin modulates angiotensin II-induced fibrosis in the intact murine heart. *J Am Coll Cardiol* 2004;43:1698–705.
- Wolak T, Kim H, Ren Y, Kim J, Vaziri ND, Nicholas SB. Osteopontin modulates angiotensin II-induced inflammation, oxidative stress, and fibrosis of the kidney. *Kidney Int* 2009;76:32–43.
- Pardo A, Gibson K, Cisneros J *et al.* Up-regulation and profibrotic role of osteopontin in human idiopathic pulmonary fibrosis. *PLoS Med* 2005;2:e251.
- Mori R, Shaw TJ, Martin P. Molecular mechanisms linking wound inflammation and fibrosis: knockdown of osteopontin leads to rapid repair and reduced scarring. *J Exp Med* 2008;205:43–51.
- Fan K, Dai J, Wang H *et al.* Treatment of collagen-induced arthritis with an anti-osteopontin monoclonal antibody through promotion of apoptosis of both murine and human activated T cells. *Arthritis Rheum* 2008;58:2041–52.

Rheumatology 2010;49:1991–1993

doi:10.1093/rheumatology/keq146

Advance Access publication 20 May 2010

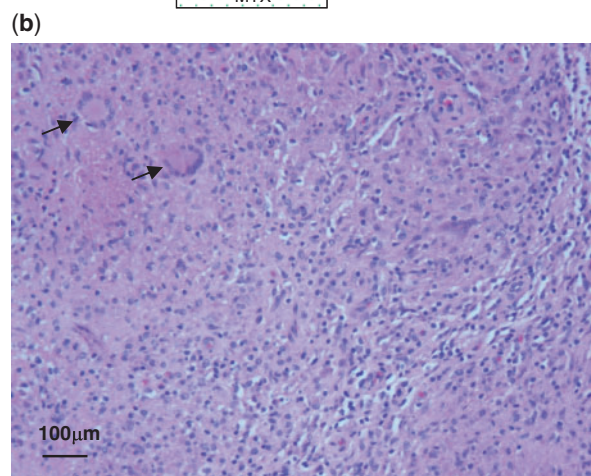
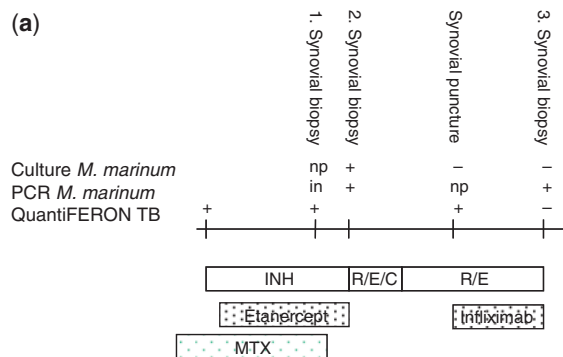
Possible role of anti-TNF monoclonal antibodies in the treatment of *Mycobacterium marinum* infection

SiR, TNF plays a major role in mycobacterial defence. *Mycobacterium marinum* (*M. marinum*) infection typically

presents with chronic inflammation of hands and feet [1, 2]. Its diagnosis is often delayed and antibiotic treatment is long-standing. Safe re-exposition to anti-TNF therapy after successful bacterial elimination was reported [3], yet addition of anti-TNF monoclonal antibodies to control inflammation seemed paradoxical so far.

A 44-year-old Caucasian farmer presented with dactylitis of a toe. Local glucocorticoid injection induced a chronic fistula, which was surgically removed. Several months later carpal arthritis and tenosynovitis developed and the patient reported inflammatory back pain. Suspecting spondyloarthritis, NSAIDs and glucocorticoids were introduced, later co-medicated with MTX, yet proved insufficient. Assessment of latent tuberculosis before anti-TNF therapy showed a positive IFN- γ -release assay [IGRA; QuantiFERON-TB Gold in Tube (QFT), Cellestis Ltd, Victoria, Australia; Fig. 1a] [4]. Isoniazid was introduced against latent tuberculosis. Etanercept was added 1 month later and within few weeks synovitis and back pain improved. Unexpectedly carpal tenosynovitis

Fig. 1 (a) Laboratory findings regarding *M. marinum* infection. np: not performed; in: PCR reaction inhibited; INH: isoniazid; R: rifampin; E: ethambutol; C: clarithromycin. (b) Histological findings of synovial tissue. Synovial tissue specimens of the carpus showing classical findings of *M. marinum* infection: granuloma formation, dense infiltrates of mononuclear cells and several giant cells (arrow).



deteriorated. Synovial biopsy revealed granuloma formation with giant cells (Fig. 1b). Microbiological cultures were not performed and PCR for mycobacteria failed due to reaction inhibition (Fig. 1a). MTX was stopped due to elevated liver enzymes. Synovitis flared and the fistula of the toe reopened. A second synovial biopsy led to the detection of *M. marinum* and to the discontinuation of etanercept. Histology was unchanged. Given the high-grade infection in an immunocompromised patient, standard therapy with ethambutol, clarithromycin and rifampin was initiated and after 4 months clarythromycin was stopped [2]. Yet carpal synovitis progressed. MRI showed synovial proliferation with bone oedema without destructive osteomyelitis. After thorough discussion and with informed consent of the patient, we added a treatment with the monoclonal TNF antibody infliximab at a dosage of 5 mg/kg/month. Hereby, clinical remission was induced. After stopping anti-bacterial therapy, a third synovial biopsy of the carpus showed marked improvement of inflammation and part resolution of the granuloma. There was no growth of mycobacteria, yet PCR for *M. marinum* was positive. QFT was then negative. Infliximab was stopped. Ten months later the patient had no signs of cutaneous or soft tissue inflammation. On-demand NSAIDs are sufficient to control intermittent back pain.

The positive QFT was interpreted as latent tuberculosis infection and treated accordingly. Yet, further work based on relapse during etanercept and MTX revealed active *M. marinum* infection in the cultured biopsy (Fig. 1a). QFT measures IFN- γ release by T lymphocytes in response to specific antigens. Notably, few non-tuberculous mycobacteria like *M. marinum*, *Mycobacterium kansasii* and *Mycobacterium szulgai* also express the antigens used in the QFT [4, 5] explaining the positive IGRA.

The positive *M. marinum*-PCR in the third biopsy is not surprising as it might equally detect dead and vital particles of bacterial DNA and is therefore not helpful in surveillance [6]. Even more so as the initial PCR had failed. Follow-up can only be properly managed by thorough clinical controls, instruction of the patient and repeating bacterial cultures.

As TNF is known to play a central role in granuloma persistence, it might surprise that despite anti-TNF treatment with etanercept, the pathologist reported classical findings of *M. marinum* infection such as granuloma formation and giant cells (Fig. 1b). Current data show that monoclonal antibodies to TNF, but not the soluble receptor etanercept, are effective in treating granulomatous diseases like Crohn's disease, sarcoidosis or localized WG. Thus, our histological data are in perfect agreement with differential clinical effects of soluble receptors vs monoclonal antibodies.

Reactivation of latent *Mycobacterium tuberculosis* infection caused by TNF-blocking therapy may be fatal. Therefore, clinicians are often reluctant to re-expose patients to anti-cytokine therapy after successful antibiotic treatment. However, recently a TNF-blocking strategy was successful in controlling inflammation in a life-threatening

tuberculous paradoxical reaction [7]. The question was raised whether anti-TNF strategies might be helpful in critical situations of tuberculous paradoxical reactions [8]. Regarding *M. marinum*, recent case reports document *M. marinum* infection under TNF inhibition, but also safe re-exposition to anti-TNF therapy after elimination of the bacteria [3, 9, 10]. In our case, local and systemic inflammation persisted for months despite adequate anti-microbial treatment. Based on the considerations above, we decided to use the monoclonal antibody infliximab with the intent to control clinical signs of inflammation and to destroy local granuloma. This procedure proved to be successful and raises the provocative question of whether continuation or introduction of TNF inhibition by monoclonal antibodies should not be advocated in cases of localized granulomatous infections with *M. marinum*. It is tempting to speculate that time to elimination of bacteria as well as time to remission of inflammation could be considerably shortened.

Rheumatology key message

- Anti-TNF monoclonal antibodies may help to control inflammation caused by *M. marinum* infection.

Disclosure statement: The authors have declared no conflicts of interest.

**Christian Garzoni^{1,*}, Sabine Adler^{2,*},
Christoph Boller¹, HansJakob Furrer² and
Peter M. Villiger¹**

¹Department of Rheumatology, Clinical Immunology and Allergology and ²Division for Infectious Diseases, University Hospital and University of Bern, Bern, Switzerland.

Accepted 13 April 2010

Correspondence to: Peter M. Villiger, Department of Rheumatology and Clinical Immunology and Allergology, Inselspital, University Hospital and University of Bern, CH-3010, Bern, Switzerland. E-mail: peter.villiger@insel.ch

*Christian Garzoni and Sabine Adler equally contributed to this work.

References

- 1 Aubry A, Chosidow O, Caumes E, Robert J, Cambau E. Sixty-three cases of *Mycobacterium marinum* infection: clinical features, treatment, and antibiotic susceptibility of causative isolates. *Arch Intern Med* 2002;162: 1746–52.
- 2 Griffith DE, Aksamit T, Brown-Elliott BA *et al.* An official ATS/IDSA statement: diagnosis, treatment, and prevention of nontuberculous mycobacterial diseases. *Am J Respir Crit Care Med* 2007; 175:367–416.
- 3 Dare JA, Jahan S, Hiatt K, Torralba KD. Reintroduction of etanercept during treatment of cutaneous *Mycobacterium marinum* infection in a patient with ankylosing spondylitis. *Arthritis Rheum* 2009;61:583–6.
- 4 Villiger PM, Zellweger J-P, Moeller B. Novel screening tools for latent tuberculosis: time to leave an old friend? *Curr Opin Rheumatol* 2009;21:238–43.

- 5 Arend SM, van Meijgaarden KE, de Boer K *et al.* Tuberculin skin testing and in vitro T cell responses to ESAT-6 and culture filtrate protein 10 after infection with *Mycobacterium marinum* or *M. kansasii*. *J Infect Dis* 2002; 186:1797–807.
- 6 Thomsen VO, Kok-Jensen A, Buser M, Philippi-Schulz S, Burkhardt HJ. Monitoring of patients with pulmonary tuberculosis: can PCR be applied? *J Clin Microbiol* 1999;37: 3601–7.
- 7 Wallis RS, van Vuuren C, Potgieter S. Adalimumab treatment of life-threatening tuberculosis. *Clin Infect Dis* 2009; 48:1429–32.
- 8 Wallis RS. Infectious complications of tumor necrosis factor blockade. *Curr Opin Infect Dis* 2009;22:403–9.
- 9 Rallis E, Koumantaki-Mathioudaki E, Frangoulis E, Chatziolou E, Katsambas A. Severe sporotrichoid fish tank granuloma following infliximab therapy. *Am J Clin Dermatol* 2007;8:385–8.
- 10 Chopra N, Kirschenbaum AE, Widman D. *Mycobacterium marinum* tenosynovitis in a patient on etanercept therapy for rheumatoid arthritis. *J Clin Rheumatol* 2002;8:265–8.

Rheumatology 2010;49:1993–1994
 doi:10.1093/rheumatology/keq161
 Advance Access publication 26 May 2010

Reversible cerebral vasoconstriction syndrome in a female patient with systemic lupus erythematosus

SIR, Headaches are common in patients with SLE, especially those suffering from CNS involvement (CNS-SLE) with or without cerebral vasculitis [1, 2]. Reversible cerebral vasoconstriction syndrome (RCVS) is characterized by the association of severe ‘thunderclap headaches’ with or without additional neurological manifestations and a ‘string of beads’ appearance on cerebral arteries, which resolves spontaneously in 1–3 months [3]. RCVS and cerebral vasculitis have several overlapping features. We report a case of RCVS in an SLE patient that was misdiagnosed initially as lupus-associated cerebral

vasculitis. To our knowledge, this is the first case of RCVS described in an SLE patient.

A 40-year-old female patient was diagnosed with SLE at the age of 25 years. She presented at the age of 27 years with a severe flare-up characterized by intra-alveolar haemorrhage and CNS-SLE (headaches, psychosis and seizure). She had no aPLs. Her follow-up was characterized by poor treatment adherence.

Since December 2008, she has been followed up in our department for World Health Organization classes IV–V lupus nephritis and treated according to the Euro-Lupus regimen. While clinico-biological remission was noted, she presented 2 days before the fifth cyclophosphamide pulse with an acute severe headache that disappeared spontaneously and the patient received the planned 500 mg i.v. cyclophosphamide. Her treatment included prednisone (30 mg/day), atorvastatin, omeprazole, calcium carbonate and cholecalciferol.

She was readmitted to the hospital 2 days later for acute severe headache associated with nausea and vomiting. The headache was of sudden onset, recurrent, described as ‘thunderclap headache’, peaking in <10 s with maximal pain intensity graded as 9.5/10 on the visual scale. She also experienced a brief generalized seizure. Physical examination was normal. A head CT scan was normal. The cerebrospinal fluid was haematic. A cerebral magnetic resonance angiogram (MRA) demonstrated multifocal cerebral arterial stenosis (Fig. 1A). The diagnosis of lupus-associated cerebral vasculitis was considered; she was treated promptly with three daily pulses of 750 mg i.v. methylprednisolone, plasmapheresis and levetiracetam.

The headaches persisted leading us to reconsider the diagnosis. A careful awareness of the characteristics of headaches and the neuro-angiographic findings led us to advocate the hypothesis of RCVS; cyclophosphamide was suspected to contribute to the cerebral vasoconstriction.

We then changed our strategy: i.v. nimodipine, discontinuation of plasmapheresis and replacement of cyclophosphamide by mycophenolate mofetil (3 g/day). The

Fig. 1 Cerebral MRA findings. MRA showing multifocal segmental stenosis of cerebral arteries (A). Control MRA done 40 days later showing resolution of the cerebral arterial vasoconstriction (B). Arrows refer to the multifocal arterial stenoses (A) that have almost completely regressed (B).

