

BRIEF REPORT

Acute Cytomegalovirus Colitis Presenting during Primary HIV Infection: An Unusual Case of an Immune Reconstitution Inflammatory Syndrome

Ulrich von Both,¹ Reto Laffer,¹ Christina Grube,¹ Walter Bossart,² Ariana Gaspert,³ and Huldrych F. Günthard¹

¹Division of Infectious Diseases and Hospital Epidemiology, ²Institute of Medical Virology, and ³Department of Pathology, University Hospital Zurich, Zurich, Switzerland

Severe ulcerous cytomegalovirus pancolitis developed during primary human immunodeficiency virus (HIV) infection in a patient who underwent early combination antiretroviral treatment. This massive inflammatory process led to acute colon perforation. Serological testing demonstrated cytomegalovirus reactivation. Severe immunosuppression caused by primary HIV infection resulted in cytomegalovirus colitis, and initiation of early combination antiretroviral therapy triggered an immune reconstitution inflammatory syndrome potentially leading to colonic perforation.

Acute retroviral syndrome is defined by unspecific symptoms that can vary greatly, and it occurs in 40%–90% of HIV-infected individuals [1, 2]. On rare occasions, opportunistic infections present simultaneously with acute retroviral syndrome [1], and only 2 reports mentioning acute cytomegalovirus (CMV) disease in primary HIV infection were found in the literature [3, 4]. To date, no case of immune reconstitution inflammatory syndrome during primary HIV infection has been reported.

CMV is one of the most common causes of opportunistic infections in persons with AIDS, and clinical CMV disease has been reported in up to 40% of these patients [5, 6]. Similar to other common herpesvirus infections in HIV-infected patients, CMV disease almost exclusively occurs as a result of reactivation

of the latent virus in a previously infected host. Clinically manifested CMV disease in HIV-infected patients usually presents in severely immunocompromised patients with CD4 cell counts <100 cells/ μ L, with 85% of patients showing retinitis. Esophagitis and colitis have been observed in 2.7% and 7.3% of these patients, respectively [6, 7]. Colitis is the most common extraocular manifestation of CMV disease in HIV-infected patients, although only a few anecdotal reports of CMV colitis in immunocompetent hosts are found in the literature [8, 9]. Most patients with CMV colitis present with diarrhea, abdominal pain, fever, weight loss, and cachexia. Extensive gastrointestinal hemorrhage and perforation have also been reported.

Case report. A 40-year-old man who had sex with men presented in July 2005 at our tertiary care hospital with a 3-week history of weight loss, frequent diarrhea, nausea, and vomiting, accompanied by fevers and oral candidiasis. Furthermore, the patient reported having had flu-like symptoms without exanthema for 7 days. Clinical examination revealed tachycardia, tachypnea, a temperature of 38.3°C, and diffuse abdominal pain, combined with massive pain on rectal examination. Initial blood counts revealed anemia (hemoglobin level, 10.6 g/dL), leukocytosis (leukocyte count, 11.66×10^3 leukocytes/ μ L), and a massively elevated C-reactive protein level (387 mg/L). The result of an HIV screening test was positive, and a subsequent Western blot assay confirmed the result. The result of a p24 antigen test was negative, the patient's plasma HIV RNA level was 3,080,000 copies/mL, and his CD4 cell count was 164 cells/ μ L (with 22% neutrophils). Primary HIV infection was suspected on the basis of clinical findings at presentation, anamnestic sexual risk exposure, and a previous negative HIV test result (in July 2004) and was later confirmed by an anti-gp120 avidity assay [10]. Following initiation of early antiretroviral treatment (ART; lopinavir plus ritonavir, zidovudine, and lamivudine) and cotrimoxazole prophylaxis, the patient's clinical condition aggravated, and colonoscopy and subsequent biopsy findings led to the diagnosis of a severe, ulcerous acute colitis. The patient began to receive empirical intravenous antibiotic therapy with ciprofloxacin and amoxicillin–clavulanic acid; later, therapy was switched to ciprofloxacin and metronidazol. Antibiotic therapy was stopped after numerous tests yielded results negative for diverse bacterial, viral, and parasitic pathogens. During the following days, the patient improved clinically. Twenty days after hospital admission and 14 days after initiation of early combination ART, he suddenly developed high fevers, combined with an acute abdomen and elevated inflammation parameters. Abdominal CT

Received 16 August 2007; accepted 24 October 2007; electronically published 16 January 2008.

Reprints and correspondence: Dr. Ulrich von Both, Div. of Infectious Diseases and Hospital Epidemiology, University Hospital Zurich, Rämistrasse 100, 8091 Zurich, Switzerland (Ulrich.vonboth@usz.ch).

Clinical Infectious Diseases 2008;46:e38–40

© 2008 by the Infectious Diseases Society of America. All rights reserved.

1058-4838/2008/4604-00E3\$15.00

DOI: 10.1086/526783

showed a pneumoperitoneum, indicating perforation of the colon (figure 1A), and the patient underwent emergency subtotal colectomy. Histopathological examination revealed severe ulcerous colitis with acute inflammation and granulation tissue on hematoxylin-eosin staining (figure 1B and 1C). Subsequent immunohistochemical examination for immediate early antigen and early antigen revealed multiple cells with cytomegalovirus inclusions, thus confirming the diagnosis of CMV pancolitis (figure 1D). The patient immediately started receiving gancyclovir therapy, and a perioperatively installed course of intravenous piperacillin-tazobactam was continued for 14 days. Serological and virological examinations 7 days after hospital admission revealed a negative CMV PCR result, a negative CMV IgM test result, and a CMV IgG titer of 98 IE/mL. On the day of histopathological diagnosis of CMV pancolitis (27 days after

hospital admission), the CMV PCR result was positive (plasma CMV RNA level, 1327 copies/mL). Twelve days later, the patient had a positive CMV IgM test result and an IgG titer >400 IE/mL. These results unambiguously confirmed reactivation of CMV disease presenting as severe ulcerous pancolitis during primary HIV infection.

Because of the development of severe neutropenia (neutrophil level, 370 cells/ μ L) and worsening anaemia (hemoglobin level, 8.0 g/dL), gancyclovir and zidovudine were replaced with valgancyclovir and abacavir, respectively. Furthermore, trimethoprim plus sulfamethoxazole prophylaxis was replaced with pentamidine inhalation. Again, intravenous antibiotics (ciprofloxacin and metronidazol) were initiated until the neutropenia resolved after 14 days.

Following this period, CMV disease and HIV infection were

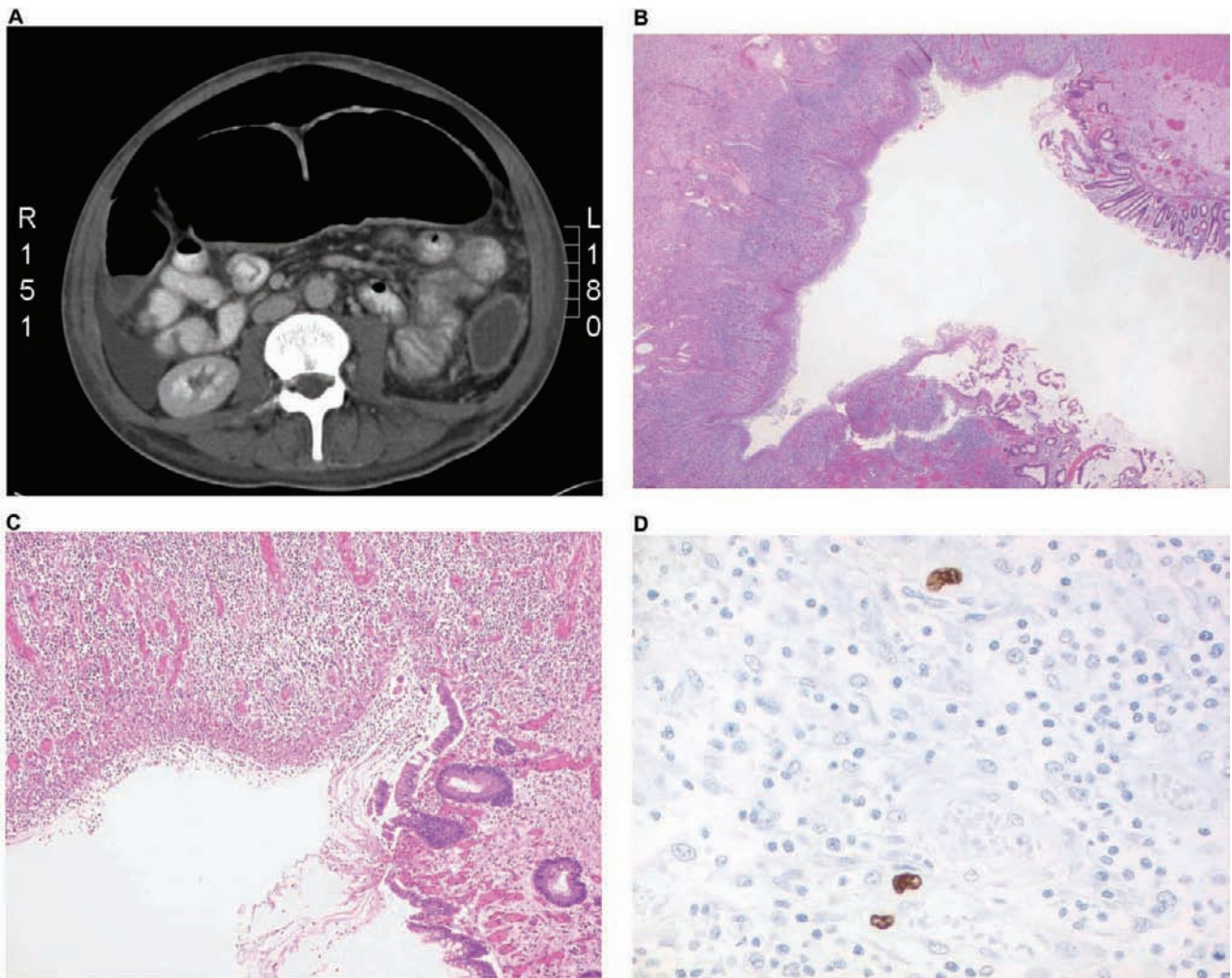


Figure 1. A, Abdominal CT showing a pneumoperitoneum indicating perforation of the colon. B, Hematoxylin-eosin stain revealing severe ulcerous colitis (original magnification, $\times 15$). C, Hematoxylin-eosin stain revealing ulcerous colitis with acute inflammation and granulation tissue (original magnification, $\times 40$). D, Immunohistochemical stain for detection of immediate early antigen and early antigen, revealing cells with cytomegalic inclusions (original magnification, $\times 200$).

successfully controlled, and the patient recovered rapidly. Repeated colonoscopic and serological monitoring has revealed no reactivation of CMV disease to date, and the patient's CD4 cell count increased to 932 cells/ μ L (with 32% neutrophils) over a 2-year period of successful combination ART; the patient had a constant plasma HIV RNA level <50 copies/mL.

Discussion. We report—to our knowledge for the first time—the occurrence of acute CMV pancolitis in the context of primary HIV infection that presented as an immune reconstitution inflammatory syndrome 2 weeks after initiation of combination ART. At initial presentation to the hospital, the patient showed a complete clinical picture of an acute retroviral syndrome, including diarrhea, abdominal pain, fever, and weight loss. Laboratory results revealed an increased HIV load and massive immunosuppression (CD4 cell count, 164 cells/ μ L [with 22% neutrophils]). Because other infectious and non-infectious causes were ruled out and because almost 50% of patients with primary HIV infection present with gastrointestinal symptoms, the initial diarrhea can be attributed to primary HIV infection. After the period of clinical improvement, the second episode of severe diarrhea, combined with high fever and malaise, started 2 weeks after initiation of early combination ART and was further aggravated by the occurrence of a colon perforation demanding subtotal colectomy. Two weeks prior to colon perforation, a colonoscopy and several biopsies were performed. The findings of the procedures led to the diagnosis of colitis, although CMV immunohistochemical test results were negative at that time. Results of histopathological examination of the biopsy specimens obtained during colectomy, however, confirmed the diagnosis of acute pancolitis, and serological tests and CMV PCR clearly confirmed CMV reactivation. In aggregate, the time of events suggests that severe immunosuppression during primary HIV infection, reflecting profound CD4 cell depletion of gut mucosa, resulted in CMV reactivation with subsequent pancolitis [11]. Initiation of early combination ART subsequently led to immune reconstitution inflammatory syndrome, and overshooting anti-CMV-specific CD8 cell responses to the abundant CMV antigens in the colon probably led to perforation. Occurrence of immune reconstitution inflammatory syndrome is supported by the rapid decrease in HIV load and the rapid increase in CD4 cell count after initiation of early combination ART (CD4 cell count, 186 cells/ μ L [with 37% neutrophils]; HIV RNA level, 6500 copies/mL). The minimal increase in absolute CD4 cell count, combined with a striking increase in CD4 cell percentage, should be evaluated in the context of valganciclovir therapy, which the patient had received for 2 weeks at that time [12].

In the literature to date, only 2 cases of acute CMV colitis have been described in the context of primary HIV infection. Although we present, to our knowledge, the first case of an

immune reconstitution inflammatory syndrome-associated and reactivated severe intestinal CMV disease, Capetti et al. [3] attributed CMV-associated hemorrhagic colitis in their patient directly to acute HIV infection. Intense symptoms occurred only 9 days after the diagnosis of primary HIV infection, and the patient had a normal CD4 cell count and did not initiate combination ART at that time. Smith et al. [4] reported a case of CMV colitis during early HIV infection, with their patient only retrospectively receiving a diagnosis of HIV infection. This patient had not received combination ART, and HIV seroconversion was suspected to have occurred ~4 months prior to diagnosis of CMV colitis.

In general, even though diarrhea is frequently associated with primary HIV infection, our case demonstrates that severe CMV colitis can present during primary HIV infection, and in rare cases, early combination ART may result in an immune reconstitution inflammatory syndrome.

Acknowledgments

We thank the patient, for participating in the Zurich Primary HIV Infection Study, and Joseph Wong, for critical review of the manuscript.

Potential conflicts of interest. All authors: no conflicts.

References

1. Aceto L, Karrer U, Grube C, et al. Primary HIV-1 infection in Zurich: 2002–2004 [in German]. *Schweiz Rundsch Med Prax* **2005**;94:1199–205.
2. Kahn JO, Walker BD. Acute human immunodeficiency virus type 1 infection. *N Engl J Med* **1998**;339:33–9.
3. Capetti A, Piconi S, Magni C, Quirino T, Trabattoni D, Clerici M. Unusual presentation of acute cytomegalovirus disease during primary HIV-1 infection: antigen-specific T-cell response analyses and clinical outcome. *AIDS* **2006**;20:1566–7.
4. Smith PR, Glynn M, Sheaff M, Aitken C. CMV colitis in early HIV infection. *Int J STD AIDS* **2000**;11:748–50.
5. Jacobson MA, Mills J. Serious cytomegalovirus disease in the acquired immunodeficiency syndrome (AIDS): clinical findings, diagnosis, and treatment. *Ann Intern Med* **1988**;108:585–94.
6. Cheung TW, Teich SA. Cytomegalovirus infection in patients with HIV infection. *Mt Sinai J Med* **1999**;66:113–24.
7. Gallant JE, Moore RD, Richman DD, Keruly J, Chaisson RE. Incidence and natural history of cytomegalovirus disease in patients with advanced human immunodeficiency virus disease treated with zidovudine. The Zidovudine Epidemiology Study Group. *J Infect Dis* **1992**;166:1223–7.
8. Carter D, Olchovsky D, Pokroy R, Ezra D. Cytomegalovirus-associated colitis causing diarrhea in an immunocompetent patient. *World J Gastroenterol* **2006**;12:6898–9.
9. Klauber E, Briski LE, Khatib R. Cytomegalovirus colitis in the immunocompetent host: an overview. *Scand J Infect Dis* **1998**;30:559–64.
10. Rusert P, Kuster H, Joos B, et al. Virus isolates during acute and chronic human immunodeficiency virus type 1 infection show distinct patterns of sensitivity to entry inhibitors. *J Virol* **2005**;79:8454–69.
11. Brenchley JM, Schacker TW, Ruff LE, et al. CD4⁺ T cell depletion during all stages of HIV disease occurs predominantly in the gastrointestinal tract. *J Exp Med* **2004**;200:749–59.
12. Studies of ocular complications of AIDS Foscarnet-Ganciclovir Cytomegalovirus Retinitis Trial. 1. Rationale, design, and methods. AIDS Clinical Trials Group (ACTG). *Control Clin Trials* **1992**;13:22–39.