



Outcome of ruptured abdominal aortic aneurysm repair: impact of aortic morphology

Mario Lachat¹ and Johnny Steuer^{1,2*}

¹Clinic for Cardiovascular Surgery, University Hospital, Zurich, Switzerland; and ²Department of Surgery, Stockholm South Hospital, Stockholm, Sweden

Online publish-ahead-of-print 3 April 2015

This editorial refers to ‘The effect of aortic morphology on peri-operative mortality of ruptured abdominal aortic aneurysm’[†], by the IMPROVE Trial Investigators, on page 1328.

Soon after endovascular aortic repair (EVAR) was introduced as a therapeutic alternative to open surgical repair >20 years ago, pioneering work was done to demonstrate the feasibility of EVAR not only in elective management of patients with abdominal aortic aneurysm (AAA), but also in ruptured AAA (rAAA).^{1,2} During the last two decades, EVAR has emerged from being a novelty to becoming the predominant therapy in patients undergoing elective repair in many centres, and randomized controlled trials (RCTs) have shown reduced peri-operative mortality in relation to open repair.^{3,4} Plausibly, haemodynamically compromised patients with rAAA would benefit from a less invasive procedure, in most cases done under local anaesthesia, avoiding drastic blood pressure fluctuations.⁵ Thereby, it would seem reasonable to expect improved peri-operative outcome after EVAR compared with open repair in rAAA. However, the implementation of a round-the-clock EVAR readiness poses logistical challenges, which may contribute to EVAR not yet being as well established for the treatment of rAAA, albeit that in some centres algorithms have been developed to manage patients with rAAA almost exclusively by way of EVAR.⁶

Even though observational studies have demonstrated advantages of EVAR over open repair in rAAA patients, the results have been debated and questioned, not least regarding possible selection bias. The first two published small RCTs on rAAA did not settle the controversy; no difference in mortality was found.^{7,8} Equally, in the most recent and largest multicentre RCT yet published on rAAA, the IMPROVE trial, there was no 30-day mortality difference, when analysing the data on an intention-to-treat basis.⁹ In their latest report, the IMPROVE Trial Investigators conducted an observational study of the treatment received, and not based on the original randomization, with the aim of identifying morphological parameters that influence the outcome.¹⁰ There was an inverse relationship between aneurysm neck length and 30-day mortality. The authors

concluded that since short aneurysm necks increase the difficulty and complication rate in open repair and impede conventional EVAR, their findings may explain the benefit of EVAR shown in observational studies, but not in RCTs. In the observational studies, patients with challenging aortic neck (short, angulated, or even absent) were not treated endovascularly, but underwent open repair, and surgery of juxta-renal aneurysms carries a higher risk of an adverse outcome (Figure 1). To rule out such a bias, the IMPROVE Trial Investigators suggest that future studies should describe the aortic anatomy more accurately and that the results should be adjusted for neck length.

Endovascular aortic repair is a less invasive operation, which in elective cases has very low mortality, <1%, and it can be carried out as a fast-track procedure (short stay or even outpatient).^{11,12} The main advantages of EVAR are that it can be performed percutaneously, under local anaesthesia, and that left ventricular wall stress from aortic cross-clamping is avoided.¹³ Because of such advantages, in many acute cardiovascular patients, nowadays endovascular interventions have nearly completely replaced open surgery [percutaneous coronary intervention (PCI) for acute coronary ischaemia, thoracic EVAR for ruptured descending aorta, etc.]. In our experience, EVAR for rAAA in the average IMPROVE moderate risk and stable patient with favourable anatomy (neck length >10 mm) is generally performed percutaneously under local anaesthesia, and is frequently completed in ~60 min. Post-operatively, most patients can leave the Intensive Care Unit the next morning. Using this algorithm, 30-day mortality has been reduced to 10%, a figure which has not been demonstrated with open repair.¹⁴

Perhaps EVAR indeed has no advantages over open repair, but one should not draw definitive conclusions from the present morphology study, as it does have some important limitations. It is a retrospective observational study, designed *a posteriori*. The statistical analyses were not performed on the original randomized groups (intention-to-treat), but on rearranged ‘as treated’ groups. In the IMPROVE trial, 36% of the patients allocated to an EVAR strategy were considered unsuitable (especially when the proximal aneurysm neck length was <10 mm), and were instead treated by open repair.

The opinions expressed in this article are not necessarily those of the Editors of the *European Heart Journal* or of the European Society of Cardiology.

[†] doi:10.1093/eurheartj/ehv521.

* Corresponding author. Department of Surgery, Stockholm South Hospital, 11883 Stockholm, Sweden. Tel: +46 8 616 23 13, Fax: +46 8 616 23 09, Email: joste@live.se

Published on behalf of the European Society of Cardiology. All rights reserved. © The Author 2015. For permissions please email: journals.permissions@oup.com.

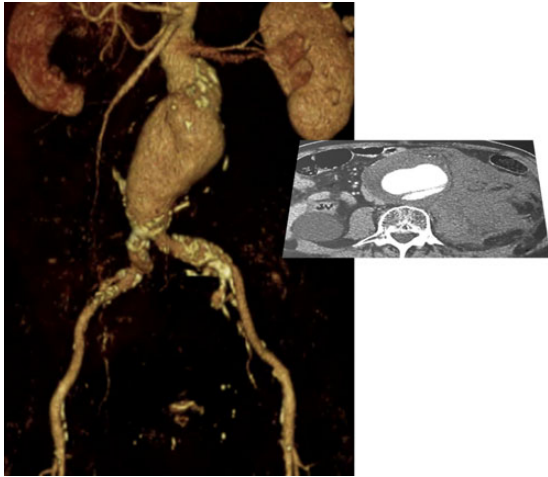


Figure 1 Ruptured juxtarenal aneurysm with a very short neck (<5 mm), ruling out conventional endovascular aortic repair (EVAR). In such cases, endovascular repair requires the use of either parallel grafts (chimneys/periscopes) or fenestrated/branched devices.

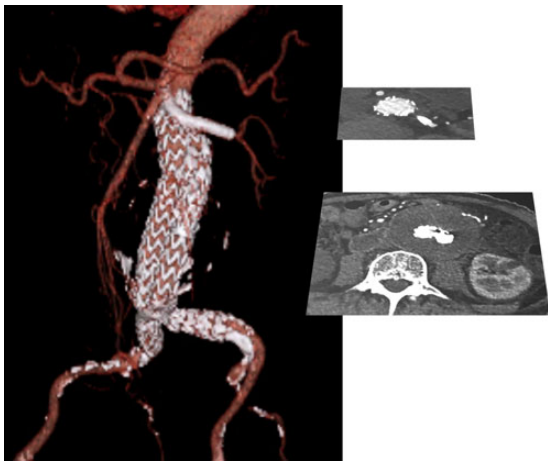


Figure 2 Follow-up computed tomography showing a patent chimney graft to the left renal artery.

One more concern is that morphological data on the infra-renal neck was missing in up to 20%. It would be of interest to reanalyse the previously published RCTs and observational studies with adjustment for neck length in patients with neck length >10 mm to obtain a valid comparison.

In summary, the present paper using data from the IMPROVE trial to explore the effect of aortic morphology on the outcome, analysing the groups according to operation received and not by randomized group, raises further questions, and, even though EVAR is less invasive and carries many theoretical advantages, the available RCTs

have failed to demonstrate a benefit on survival compared with open repair in rAAA. The debate will go on as to which method is superior. No doubt, EVAR has become a highly valuable alternative to open repair in rAAA. With the use of available adjuncts to conventional EVAR, such as parallel grafts (chimney/periscope), and upcoming off-the-shelf devices for branched or fenestrated EVAR, most ruptured aneurysms can be managed endovascularly (Figure 2), and, hence, maybe only by comparing open repair with complex EVAR would the comparison be fully valid. We look forward to further results from the IMPROVE trial, which may clarify some of these issues.

Conflict of interest: none declared.

References

- Ohki T, Veith FJ, Sanchez LA, Cynamon J, Lipsitz EC, Wain RA, Morgan JA, Zhen L, Suggs WD, Lyon RT. Endovascular graft repair of ruptured aortoiliac aneurysms. *J Am Coll Surg* 1999;**189**:102–112; discussion 112–113.
- Yusuf SW, Whitaker SC, Chuter TA, Wenham PW, Hopkinson BR. Emergency endovascular repair of leaking aortic aneurysm. *Lancet* 1994;**344**:1645.
- Greenhalgh RM, Brown LC, Kwong GP, Powell JT, Thompson SG; EVAR trial participantst. Comparison of endovascular aneurysm repair with open repair in patients with abdominal aortic aneurysm (EVAR trial 1), 30-day operative mortality results: randomised controlled trial. *Lancet* 2004;**364**:843–848.
- Prinssen M, Verhoeven EL, Buth J, Cuypers PW, van Sambeek MR, Balm R, Buskens E, Grobbee DE, Blankensteijn JD; Dutch Randomized Endovascular Aneurysm Management (DREAM) Trial Group. A randomized trial comparing conventional and endovascular repair of abdominal aortic aneurysms. *N Engl J Med* 2004;**351**:1607–1618.
- Bjorck M. Surgery for ruptured abdominal aortic aneurysm. *BMJ* 2014;**348**:g95.
- Mayer D, Aeschbacher S, Pfammatter T, Veith FJ, Norgren L, Magnuson A, Rancic Z, Lachat M, Horer T, Skoog P, Larzon T. Complete replacement of open repair for ruptured abdominal aortic aneurysms by endovascular aneurysm repair: a two-center 14-year experience. *Ann Surg* 2012;**256**:688–695; discussion 695–696.
- Hinchliffe RJ, Bruijstens L, MacSweeney ST, Braithwaite BD. A randomised trial of endovascular and open surgery for ruptured abdominal aortic aneurysm—results of a pilot study and lessons learned for future studies. *Eur J Vasc Endovasc Surg* 2006;**32**:506–513; discussion 514–515.
- Reimerink JJ, Hoornweg LL, Vahl AC, Wisselink W, van den Broek TA, Legemate DA, Reekers JA, Balm R, Amsterdam Acute Aneurysm Trial Collaborators. Endovascular repair versus open repair of ruptured abdominal aortic aneurysms: a multicenter randomized controlled trial. *Ann Surg* 2013;**258**:248–256.
- Investigators IT, Powell JT, Sweeting MJ, Thompson MM, Ashleigh R, Bell R, Gomes M, Greenhalgh RM, Grieve R, Heatley F, Hinchliffe RJ, Thompson SG, Ulug P. Endovascular or open repair strategy for ruptured abdominal aortic aneurysm: 30 day outcomes from IMPROVE randomised trial. *BMJ* 2014;**348**:f7661.
- IMPROVE Trial Investigators. The effect of aortic morphology on peri-operative mortality of ruptured abdominal aortic aneurysm. *Eur Heart J* 2015;**36**:1328–1334.
- Al-Zuhir N, Wong J, Nammuni I, Curran G, Tang T, Varty K. Selection, thirty day outcome and costs for short stay endovascular aortic aneurysm repair (SEVAR). *Eur J Vasc Endovasc Surg* 2012;**43**:662–665.
- Lachat ML, Pecoraro F, Mayer D, Guillet C, Glenck M, Rancic Z, Schmidt CA, Puipe G, Veith FJ, Bley J, Bettex D. Outpatient endovascular aortic aneurysm repair: experience in 100 consecutive patients. *Ann Surg* 2013;**258**:754–758; discussion 758–759.
- Harpole DH, Clements FM, Quill T, Wolfe WG, Jones RH, McCann RL. Right and left ventricular performance during and after abdominal aortic aneurysm repair. *Ann Surg* 1989;**209**:356–362.
- Veith FJ, Lachat M, Mayer D, Malina M, Holst J, Mehta M, Verhoeven EL, Larzon T, Gennai S, Coppi G, Lipsitz EC, Gargiulo NJ, van der Vliet JA, Blankensteijn J, Buth J, Lee WA, Biasi G, Deleo G, Kasirajan K, Moore R, Soong CV, Cayne NS, Farber MA, Raithel D, Greenberg RK, van Sambeek MR, Brunkwall JS, Rockman CB, Hinchliffe RJ, RAAA Investigators. Collected world and single center experience with endovascular treatment of ruptured abdominal aortic aneurysms. *Ann Surg* 2009;**250**:818–824.