

# Modified Nikaidoh procedure for the correction of complex forms of transposition of the great arteries with ventricular septal defect and left ventricular outflow tract obstruction: mid-term results

Peter Kramer<sup>a,†</sup>, Stanislav Ovroutski<sup>a,\*,†</sup>, Roland Hetzer<sup>b</sup>, Michael Hübler<sup>b,c,†</sup> and Felix Berger<sup>a,†</sup>

<sup>a</sup> Department of Congenital Heart Disease and Pediatric Cardiology, Deutsches Herzzentrum Berlin, Berlin, Germany

<sup>b</sup> Department of Cardiothoracic and Vascular Surgery, Deutsches Herzzentrum Berlin, Berlin, Germany

<sup>c</sup> Division of Congenital Cardiovascular Surgery, University Children's Hospital, Zurich, Switzerland

\* Corresponding author. Department of Congenital Heart Disease and Pediatric Cardiology, Deutsches Herzzentrum Berlin, Augustenburger Platz 1, 13353 Berlin, Germany. Tel: +49-304593-2800; e-mail: [ovroutski@dhzb.de](mailto:ovroutski@dhzb.de) (S. Ovroutski).

Received 1 July 2013; received in revised form 4 September 2013; accepted 12 September 2013

## Abstract

**OBJECTIVES:** Different surgical techniques for the treatment of complex transposition of the great arteries (TGA) with ventricular septal defect and left ventricular outflow tract obstruction (LVOTO) have been developed, in particular the Rastelli operation, the réparation à l'étage ventriculaire procedure and the Nikaidoh procedure. The hitherto published results of the Nikaidoh procedure and its modifications compare favourably with those of other techniques; however, experience with the Nikaidoh procedure is still limited. Here, we report our institutions' early and mid-term results with modifications of the Nikaidoh procedure.

**METHODS:** Twenty-one patients who underwent a modified Nikaidoh procedure between 2006 and 2012 at our institution, either as aortic root translocation ( $n = 17$ ) or as *en bloc* rotation of the arterial trunk ( $n = 4$ ), were studied retrospectively.

**RESULTS:** There were 2 early and 1 mid-term deaths. The follow-up continued for a median of 2.3 years (range 0.3–6.4 years). During the follow-up, the performance of the reconstructed left ventricular outflow tract (LVOT) remained excellent: no reobstruction and no aortic valve regurgitation classified as more than mild were observed. Left ventricular function was well preserved. In 4 patients, a significant reoccurring right ventricular outflow tract obstruction due to conduit failure was observed; so far, two reoperations with conduit replacement have been necessary. The mean right ventricular outflow tract peak gradient was  $24 \pm 7.2$  mmHg at the last follow-up in the remaining patients. No reobstruction of the right ventricular outflow tract occurred in patients with preserved pulmonary valve tissue after *en bloc* rotation.

**CONCLUSIONS:** The aortic translocation procedure is a valuable surgical option for patients with complex (TGA) with ventricular septal defect and LVOTO. The mid-term results document excellent performance of the reconstructed LVOT. Modifications of the Nikaidoh procedure that preserve pulmonary valve tissue may further reduce the need for right ventricular outflow tract reoperation.

**Keywords:** Complex transposition of the great arteries • Ventricular septal defect • Left ventricular outflow tract obstruction • Modified Nikaidoh procedure • Aortic root translocation

## INTRODUCTION

So far, there is no consensus about the optimal surgical management of complex forms of transposition of the great arteries (TGA) with left ventricular outflow tract obstruction (LVOTO) and ventricular septal defect (VSD). Various techniques have been applied to the repair of this lesion type, notably the Rastelli procedure, the réparation à l'étage ventriculaire (REV) and the aortic translocation (Bex/Nikaidoh) procedure. Introduced in 1969, the Rastelli operation has become the standard procedure for the surgical repair of complex forms of TGA [1]. It can be performed with good early results and low early mortality; however, mid- and long-term results have been shown to be unsatisfactory [2–4]. Some authors

report the probability of survival without reoperation to be as low as 40% only 5 years after the Rastelli operation [5]. High rates of reinterventions and reoperations due to degeneration of the conduit with right ventricular outflow tract obstruction (RVOTO) and to a lesser extent also due to reobstruction of the left ventricular outflow tract (LVOT) have been found. Most importantly, a high incidence of late deaths has been reported in several studies and 20-year survival excluding early mortality was found to be ~60% [2–4]. The REV technique, introduced in 1982 by Lecompte *et al.*, was shown to reduce the risk of right ventricular outflow tract (RVOT) and LVOT reobstruction, resulting in lower reoperation rates [5, 6]. Moreover, the late mortality is substantially lower.

The initial concept of the aortic translocation procedure was first described by Bex *et al.* [7] in 1980 and the surgical technique

<sup>†</sup>Both the first and the last two authors contributed equally to this work.

was later applied by Nikaidoh *et al.* [8] in 1984. The main conceptual goal of the Nikaidoh procedure is to improve the surgical results through an anatomical correction by translocation of the aortic root over the LVOT, resulting in a more normal alignment of the outflow tracts and in preservation of the right ventricular cavity. Several modifications, including application of an arterial switch, a modified Konno procedure, performance of an *en bloc* rotation of the arterial trunk and combination with the Senning or Mustard procedure in patients with congenitally corrected transposition of the great arteries (ccTGA), have since been described [9–12]. Although introduced more than two decades ago, the Nikaidoh procedure and its modifications have been far less widely used than the Rastelli operation or the REV, probably due to its demanding surgical technique. Hence, the number of reported cases is still relatively small.

Here, we report the early and mid-term results of our single-centre experience in patients who underwent aortic translocation for complex TGA with VSD and LVOTO.

## MATERIALS AND METHODS

Between 2006 and 2012, the aortic translocation procedure was performed in 21 patients with complex forms of TGA at our institution. Hospital and out-patient records were analysed retrospectively. For those patients not followed at our institution, data were obtained by contacting the attending cardiologist. Detailed follow-up information was available for all but 1 patient. During the study period, a Rastelli procedure was performed in 4 patients;

in 3 patients aortic translocation was not expected to be of significant advantage due to limited space for posterior translocation and in 1 patient a major coronary artery crossing the RVOT precluded safe excision of the autograft. In addition, LVOTO resection and/or pulmonary valve reconstruction allowed the performance of an arterial switch operation in 6 patients.

## Patients

The median age at operation was 9.9 months (range 1.7 months to 21.5 years), median weight was 9.6 kg (range 4.4–59 kg) and the male-to-female ratio was 2:1. Routine echocardiography was performed preoperatively in all patients. A supplementary preoperative MRI investigation was performed in 7 cases where the exact intracardiac anatomy and outflow tract geometry could not be sufficiently visualized by echocardiography. In 18 patients preoperative cardiac catheterization for haemodynamic studies was carried out at our own or in the referring institutions. The anatomic characteristics are listed in Table 1. D-TGA was present in 19 patients, of whom 4 had double-outlet right ventricle (DORV) morphology and 2 had ccTGA. Situs solitus was present in 19 and situs inversus in 2 cases. Additional diagnoses with importance for the surgical management included straddling of the mitral valve in 2 patients. Coronary anomalies were found in 3 patients, 1 of whom had a single coronary ostium. In 15 of 21 patients prior palliative operations had been performed, the most frequent procedure being the creation of an aortopulmonary shunt in patients with severe cyanosis (Table 2). Two patients were previously

**Table 1:** Anatomic and haemodynamic data

				Value n (%)	
Situs	Solitus			19 (90.5)	
	Inversus			2 (9.5)	
Anatomic classifications	TGA	{S,D,D}		14 (66.7)	
		DORV {S,D,D}		3 (14.3)	
		{I,L,L}		1 (4.8)	
		DORV {I,L,L}		1 (4.8)	
		{S,L,L}		2 (9.5)	
Associated cardiac malformations	ccTGA			2 (9.5)	
	Straddling mitral valve			2 (9.5)	
	Multiple VSD (>1)			4 (19.0)	
	ASD/PFO			10 (47.6)	
Coronary anatomy	PDA	normal	TGA	1LCx2R	17 (81.0)
		ccTGA		1R2LCx	1 (4.8)
	Coronary anomalies	TGA		1L2RCx	2 (9.5)
		ccTGA		2LCxR	1 (4.8)
LVOTO Morphology	Isolated valvular stenosis			–	
	Isolated subvalvular stenosis			1 (4.8)	
	Multilevel LVOTO			17 (81)	
	Pulmonary atresia			3 (14.3)	
Pressure gradient (mmHg)				Mean ± SD	
PV diameter (mm)				76 ± 15	
PV Z-score				8.7 ± 4.9	
				–3.0 ± 2.0	

Coronary anatomy classification according to Leiden convention. Z-scores were calculated from [13].

TGA: transposition of the great arteries; DORV: double-outlet right ventricle; ccTGA: congenitally corrected transposition of the great arteries; VSD: ventricular septal defect; ASD: atrial septal defect; PFO: patent foramen ovale; PDA: patent ductus arteriosus; LVOTO: left ventricular outflow tract obstruction; PV: pulmonary valve; SD: standard deviation.

**Table 2:** Previous procedures

	n (%)
Catheter interventions	
Rashkind BAS	6 (28.6)
Dilatation of restrictive ASD	1 (4.8)
Closure of MAPCA	2 (9.5)
APS dilatation and/or stent implantation	3 (14.3)
Peripheral PA dilatation and stent implantation	1 (4.8)
Surgery	
APS (total)	13 (61.9)
Classic BTS	3 (14.3)
Modified BTS	8 (38.1)
Central APS	2 (9.5)
Glenn anastomosis	2 (9.5)
Patch enlargement of PA bifurcation	1 (4.8)

BAS: balloon atrial septostomy; ASD: atrial septal defect; MAPCA: major aortopulmonary collateral artery; APS: aortopulmonary shunt; PA: pulmonary artery; BTS: Blalock-Taussig shunt.

thought not to be eligible for biventricular repair and had received palliation with a bi-directional Glenn anastomosis. Most of these patients (11/15) had been operated on at institutions other than our own; 4 patients had had more than one previous operation. Prior catheter intervention had been performed in 8 patients, the most frequent procedure being the Rashkind balloon atrial septostomy (Table 2). More than one catheter intervention had been carried out in 4 patients.

## Surgical technique

Modifications of the Nikaidoh procedure were performed using moderate-to-deep hypothermia and cold crystalloid and colloid cardioplegia. Mean aortic cross-clamp time and mean cardiopulmonary bypass time were  $155 \pm 35$  and  $236 \pm 51$  min, respectively (Table 3). After establishment of cardiopulmonary bypass and cardioplegia, the ascending aorta and main pulmonary artery were transected, followed by circular excision and mobilization of the coronary arteries. For the aortic translocation, the aortic root was excised by a circumferential right ventriculotomy just below the aortic annulus. The stenotic pulmonary valve annulus and the conal septum were divided by an anterior incision which extended into the VSD. The stenotic LVOT was then enlarged and the VSD closed by the insertion of a triangular-shaped Dacron patch. In 2 cases, the LVOT reconstruction and VSD closure were achieved by using a muscle flap from the conal septum. Subsequently, the aortic root autograft was rotated  $180^\circ$  and translocated above the LVOT, where it was anastomosed to the left ventricle and the VSD patch. Coronary arteries were reimplemented, followed by reconstruction of the ascending aorta. A Lecompte manoeuvre was performed beforehand in all but 3 cases. In 1 adult patient, the coronary arteries were not detached but only mobilized and the aortic root was translocated posteriorly without rotation. For the RVOT reconstruction and establishment of continuity to the pulmonary artery, valved bovine heterografts (Contegra<sup>®</sup>, Medtronic, Minneapolis, MN, USA) were used in 17 patients. In 4 patients, a complete *en bloc* resection of the aortic and pulmonary root was performed. After resection, the entire arterial trunk was rotated  $180^\circ$  and the pulmonary and aortic root

**Table 3:** Operation details

	Value
	Mean $\pm$ SD
Aortic cross-clamp time (min)	$155 \pm 35$
Cardiopulmonary bypass time (min)	$236 \pm 51$ n (%)
LVOT reconstruction	
Aortic translocation	17 (81)
Without coronary detachment	1 (4.8)
<i>En bloc</i> rotation	4 (19)
RVOT reconstruction	
Valved conduit	17 (81)
Monocuspid patch	2 (9.5)
Transannular patch	1 (4.8)
Subvalvular resection only	1 (4.8)
Additional surgical procedures	
MV chordae translocation	2 (9.5)
Senning procedure	2 (9.5)
TV reconstruction	1 (4.8)
Take-down of Glenn anastomosis	2 (9.5)
Closure of additional VSD	4 (19)
ASD/PFO closure	10 (47.6)
Enlargement of peripheral PA	1 (4.8)
APS ligation	13 (61.9)
PDA ligation	2 (9.5)

LVOT: left ventricular outflow tract; RVOT: right ventricular outflow tract; MV: mitral valve; TV: tricuspid valve; VSD: ventricular septal defect; ASD: atrial septal defect; PFO: patent foramen ovale; PA: pulmonary artery; APS: aortopulmonary shunt; PDA: patent ductus arteriosus.

were anastomosed to the corresponding outflow tract. In 1 of these patients the pulmonary valve autograft did not require any enlargement. In 2 cases, a monocuspid patch created from a Contegra<sup>®</sup> conduit was used to enlarge the RVOT, while in 1 case a transannular patch was inserted. Several concomitant surgical procedures were performed (Table 3). These included take-down of a Glenn anastomosis and superior vena cava reconstruction, translocation of mitral valve chordae, enlargement of the pulmonary artery bifurcation and reconstruction of the tricuspid valve. In 2 patients with ccTGA an atrial switch with a Senning procedure was performed.

## Statistical analysis

Time-related analysis of survival and freedom from reoperation or reintervention events was performed using the Kaplan-Meier method. For group comparison and identification of risk factors for early mortality and RVOT reconstruction, either the unpaired two-tailed *t*-test for continuous variables or Fisher's exact test for categorical data was used, as appropriate. A *P*-value of  $\leq 0.05$  was considered to be statistically significant.

## RESULTS

### Survival

There were 2 early deaths. In both cases, extracorporeal membrane oxygenation (ECMO) was required due to poor left

ventricular performance in the early postoperative period. In 1 case, the reduced function was attributed to a circumscribed coronary perfusion deficit in the circumflex artery territory as was revealed by cardiac catheterization; in this patient, the circumflex artery originated from the right coronary artery (1L2RCx). The second patient was 17 years old and preoperatively exhibited a severely hypertrophied and dysfunctional left ventricle. Postoperatively she had seriously compromised global myocardial contractility without obvious coronary ischaemia documented in coronary angiography. Neither patient could be successfully weaned from ECMO and both died. During the mid-term follow-up, 1 death occurred 4 months postoperatively. This 2-year old female patient had experienced a prolonged postoperative course, complicated by fulminant sepsis with multiorgan failure but recovered completely and had been discharged in good clinical condition and with unrestricted cardiac function. She died abroad; unfortunately, closer information concerning the cause of death is unavailable to us. The overall 5-year survival was 86% (Fig. 1). Aortic cross-clamp time and cardiopulmonary bypass time were significantly longer ( $204 \pm 69$  vs  $150 \pm 30$  min and  $342 \pm 5$  vs  $224 \pm 40$  min,  $P = 0.04$  and  $P < 0.001$ , respectively) in the cases of early deaths compared to the survivors.

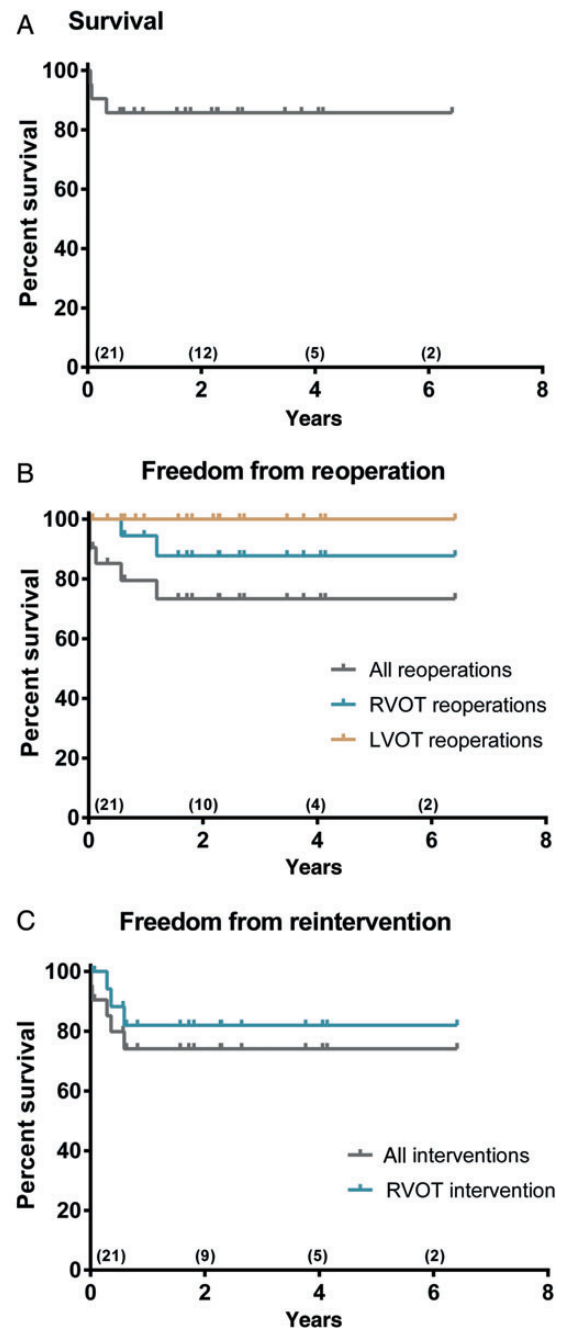
### Early postoperative morbidity

In the survivors, the postoperative course was uneventful in most cases, with short mechanical ventilation time (median 1.5 days, range 0.2–33.6 days), short intensive care unit stay (median 7 days, range 3–33 days) and short postoperative hospital stay (median 12 days, range 6–49 days). Postoperative complications included excessive bleeding ( $n = 1$ ), cardiac tamponade ( $n = 1$ ) and fulminant sepsis with multiorgan failure and associated necrotizing enterocolitis ( $n = 1$ ). Three patients needed permanent pacemaker implantation for complete atrioventricular block following wide excision of the severe LVOTO. In all other patients sinus rhythm was noted and no dysrhythmias occurred during the follow-up. Early catheter intervention was required in 3 cases. In 2 patients with multiple VSD, interventional device closure of relevant residual VSD was performed successfully without complications. In 1 patient with reconstruction of the superior vena cava after Glenn take-down a significant obstruction developed and was successfully dilated. At discharge, all patients had unobstructed left and right ventricular outflow tracts. Left ventricular function was good in 15/19 and mildly impaired in 3/19 patients. Only 1 patient had moderate dysfunction with electrocardiographic signs of ischaemia but without confirmation of coronary perfusion deficits in angiography. Postoperative MRI showed a small subendocardial scar in the left anterior descending artery territory; thus, temporary postoperative kinking or distortion of the left anterior descending artery was assumed. Left ventricular function recovered quickly and remained good during the follow-up period.

### Follow-up results

The follow-up continued for a median of 2.3 years (range 0.3–6.4 years). The results are summarized in Table 4.

**Functional capacity.** At the last follow-up, 16 patients showed unlimited physical capacity consistent with New York Heart Association (NYHA) or modified Ross heart failure classification



**Figure 1:** Survival, freedom from reoperation and freedom from reintervention after aortic translocation. Kaplan–Meier analysis of overall survival (A), overall freedom from reoperation and freedom from LVOT and RVOT reoperation (B) and overall freedom from reintervention and freedom from RVOT reintervention (C) after aortic translocation procedure. (B) Reoperations include pacemaker implantation ( $n = 3$ ), mitral valve reconstruction ( $n = 1$ ) and RVOT conduit replacement ( $n = 2$ ). Figures in parentheses represent numbers of patients at risk; numbers refer to overall freedom from reoperation in (B) and overall freedom from reintervention in (C). LVOT: left ventricular outflow tract; RVOT: right ventricular outflow tract.

functional class I. In 3 patients, 1 with severe pulmonary valve insufficiency after RVOT reconstruction with a transannular patch, 1 with moderate baffle stenosis after aortic translocation and the Senning procedure and 1 with residual mitral valve incompetence after translocation of the chordae, moderately limited physical capacity corresponding to functional class II was observed.

**Table 4:** Echocardiographic and clinical findings at the last follow-up

			n (%)
LVOT	LVOTO		-
	Aortic valve regurgitation	None/trivial	14 (77.7)
		Mild	4 (22.3)
		>Mild	-
LV function	Good (LVEF $\geq$ 60%)		15 (83.3)
	Mild impairment (LVEF 50–60%)		3 (16.7)
	>Mild impairment (LVEF < 50%)		-
RVOT	RVOTO	None (<30 mmHg)	12 (75)
		Mild (<50 mmHg)	2 (12.5)
		Moderate (<70 mmHg)	1 (6.3)
		Severe (>70 mmHg)	1 (6.3)
	PV regurgitation	None/trivial	9 (56.3)
		Mild	4 (25)
		Moderate	2 (12.5)
		Severe	1 (6.3)
RV function	Good		16 (88.9)
	Mild impairment		1 (5.5)
	Moderate impairment		1 (5.5)
Functional capacity		I	16 (88.9)
NYHA or modified Ross heart failure classification functional class		II	2 (11.1)
		>II	-

RVOT figures exclude 2 patients with conduit replacement. Echocardiographic determination of LVEF was performed using Simpson's method while RV function was assessed visually.

LVOT: left ventricular outflow tract; LVOTO: left ventricular outflow tract obstruction; LV: left ventricle; LVEF: left ventricular ejection fraction; RVOT: right ventricular outflow tract; RVOTO: right ventricular outflow tract obstruction; PV: pulmonary valve; RV: right ventricle; NYHA: New York Heart Association.

**Left ventricle and left ventricular outflow tract.** Unobstructed flow in the LVOT and well-preserved aortic valve competence could be documented in all survivors during the follow-up. Freedom from LVOT reoperation is 100% at 5 years (Fig. 1B). No aortic insufficiency more than mild occurred, with no regurgitation observed in 5, trivial in 9 and mild in 4 patients. Left ventricular systolic function was generally good, with ejection fractions >60% in 16/18 patients; only 2/18 patients had a mild systolic dysfunction with ejection fractions of 50 and 58%, respectively. Trivial-to-mild mitral regurgitation was present in 7 patients. Both children with preoperative mitral valve straddling developed moderate valve insufficiency after translocation of the chordae. One of them had subsequent mild left ventricular dysfunction and underwent mitral valve reconstruction 2.5 years after aortic translocation, with good results. Ventricular function was significantly improved.

**Right ventricular outflow tract.** During the follow-up period, the RVOT performance and pulmonary function remained good in most patients. Significant RVOT reobstruction occurred in 4/18 patients; in these cases, catheter intervention with pulmonary artery dilatation and/or stent implantation was performed. Overall freedom from catheter reintervention was 74.1% at 5 years and freedom from catheter intervention due to RVOT reobstruction was 81.9% after the same period (Fig. 1C). Two patients subsequently required conduit replacement 0.6 and 1.2 years after aortic translocation (Fig. 1B) and 1 patient is awaiting reoperation with a peak RVOT pressure gradient of >70 mmHg. Of the remaining patients, 12/14 had a systolic pressure gradient of <30 mmHg across the RVOT and 2 had mild obstructions with gradients of 30–35 mmHg. The mean RVOT peak gradient at the last follow-up was  $24 \pm 7.2$  mmHg, excluding the 4 patients with

significant reobstruction. Trivial or no pulmonary regurgitation was observed in 9 patients, mild in 4 and moderate in 2. One patient with a transannular patch RVOT reconstruction after *en bloc* translocation developed severe pulmonary regurgitation with consequential moderate right ventricular dilatation and mild-to-moderate dysfunction. All other patients had good systolic right ventricular function. At 5 years, overall freedom from reoperation was 73.4% and freedom from RVOT reoperation 87.7% (Fig. 1B). Statistical analysis did not indicate younger age at operation ( $8 \pm 1$  vs  $34 \pm 66$  months,  $P = 0.45$ ), heterograft conduit RVOT reconstruction (4/14 vs 0/4,  $P = 0.52$ ), performance of Lecompte manoeuvre (3/15 vs 1/3,  $P = 1$ ) or Z-score of the conduit size ( $1.8 \pm 1$  vs  $1.7 \pm 0.8$ ,  $P = 0.87$ ) to be associated with the development of RVOT reobstruction.

## DISCUSSION

Here, we present our early and mid-term results of one of the largest hitherto published series of patients undergoing modified Nikaidoh procedures for the correction of complex TGA with VSD and LVOTO.

This study shows excellent mid-term results of the aortic translocation procedure with respect to LVOT performance. Echocardiography documented laminar outflow without signs of reobstruction in all patients and the competence of the translocated aortic valve was well preserved, with no aortic valve insufficiency exceeding mild regurgitation being observed. The overall performance of the reconstructed RVOT in our cohort was satisfactory. Significant reobstructions of the heterograft conduit necessitating catheter intervention and/or surgical conduit replacement occurred in four patients (22%). In the remaining

patients no or only mild reobstruction was documented and preserved competence of the conduit valve as well as uncompromised right ventricular function was present in most cases.

The surgical method of choice for the management of complex TGA with VSD and LVOTO remains a matter of debate. The most frequently applied Rastelli procedure can be performed with low early mortality and morbidity. However, long-term results have been shown to be unsatisfactory in various large retrospective studies [2–4]. Reoperations for RVOT conduit replacement are inevitable and 5-year rates of freedom from RVOT reintervention between 40 and 85% have been reported [2–5, 14]. In addition, a considerable number of reoperations for residual or reoccurring LVOTO have been necessary, with freedom from LVOTO reoperation rates varying between 84% at 15 years and 95% at 20 years. Most importantly, these studies revealed a disturbingly high number of late deaths, with a 20-year survival rate of about 60%, only one study by Brown *et al.* [14] presenting an exceptionally better long-term survival at 20 years of 93%. The REV technique was introduced to overcome the disadvantages of the Rastelli procedure and to reduce the risks of LVOT and RVOT reoperation. Extensive resection of the conal septum results in a somewhat straighter configuration of the LVOT and the direct right ventricular to pulmonary artery anastomosis avoids the use of prosthetic conduits. This resulted in a considerably improved long-term survival of 85% at 25 years in a large series of patients [6]. Even though also resulting in an improved long-term freedom from LVOT reoperation of 95% at 25 years, RVOT reoperations were frequent, with freedom from reoperation being about 80% at 5 years and 33% at 25 years.

Although the Nikaidoh procedure was already introduced in 1984, experience with it is still clearly limited compared with that of the Rastelli or REV in terms of patient numbers and follow-up duration as well as the number of performing institutions. The reasons for its less frequent application in the management of complex TGA remain unclear, one factor probably being the more complex operative technique. The main theoretical advantage of the Nikaidoh procedure and its modifications is the resulting more natural intracardiac geometry and alignment of the outflow tracts through the concomitant posterior translocation of the aortic root over the LVOT, allowing reconstruction of the RVOT in an orthotopic position. The favourable LVOT configuration minimizes the risk of reoccurring LVOTO, while the orthotopic RVOT reconstruction reduces the risk of reobstruction due to sternal compression. In addition, the Nikaidoh procedure can be performed independently of the VSD location and morphology as well as in patients with additional intracardiac malformations precluding the Rastelli procedure, such as straddling of the atrioventricular valves. The results of the Nikaidoh procedure and its modifications published so far are very promising [10, 11, 15–17]. Overall early mortality is low, with figures of 0–5% being reported [16–20]. Most importantly, the number of late deaths is substantially lower after aortic translocation than after the Rastelli or REV procedure. Overall survival rates were 95–100% with no late deaths in 5 of the largest series. Three late deaths occurred in the Pittsburgh series, of which 2 were considered preventable [18].

In our cohort, 2 early deaths due to left ventricular dysfunction occurred. Prolonged aortic cross-clamp time and cardiopulmonary bypass time were associated with early mortality. However, given the small cohort size and small number of events, the possibilities of statistical analysis and the potential for drawing meaningful conclusions are limited. From our experience, we would reason that in high-risk patients, for instance, older patients with

compromised left ventricular function and severe hypertrophy, the performance of operative techniques requiring shorter cross clamp and bypass times such as the Rastelli procedure should be considered. Additionally, we would emphasize that careful consideration should be given to the coronary anatomy, since coronary anomalies may increase the mortality risk.

None of the studies with larger series of patients reported any required LVOTO reoperations after aortic translocation [10, 11, 15, 16]. Additionally, and in accordance with our observations, the competence of the translocated aortic valve was generally well preserved. If regurgitation occurred, it was found to be mild in most cases, was usually present already early after operation and did not tend to progress [10, 11, 15, 16]. However, a few patients with moderate valve insufficiency after aortic translocation were reported in the Pittsburgh (3/12) and Boston series (1/11) [11, 15]. One patient requiring reoperation due to severe regurgitation was mentioned in a later publication from Pittsburgh, which is, to our knowledge, the only reported case of severe aortic valve incompetence after modified Nikaidoh procedure so far [18]. Distortion of the sinotubular junction of the free autograft during implantation has been discussed as a possible cause of significant regurgitation, a complication not observed with the original technique used by Nikaidoh, which did not detach the left coronary artery and did not transect the ascending aorta [10, 11]. This emphasizes the importance of leaving the sinotubular junction intact in order to minimize aortic root distortion and preserve valve competence. On the other hand, Nikaidoh's group found a dilated aortic annulus in 63% of their patients [10]. Exact dimensions were not given by the authors, but they did not encounter signs of aortic valve distortion or significant regurgitation. No aortic root dilatation has been observed in our cohort, which is consistent with the findings reported by other authors [11, 15]. It has to be noted though that the follow-up duration of Nikaidoh's series is significantly longer and dilatation of the aortic annulus may occur late after translocation. However, it does not seem to cause significant regurgitation. Yet, the overall experience with the aortic translocation procedure is limited and the long-term performance of the translocated aortic root and the impact of different translocation techniques on the performance remain to be determined.

Rates for RVOT reoperation vary between 5/12 (42%) patients during a median follow-up of 4.3 years reported from Boston and 3/20 (15%) of early surviving patients during a mean follow-up of 5.9 years mentioned in the series from Pittsburgh (detailed data are not given and exact figures might be slightly different) [11, 18, 21]. In the series of Nikaidoh's group from Texas, freedom from RVOT reoperation was found to be 64% at 15 years and 20 years, as concluded from the Kaplan–Meier analysis [10]. In addition, more recent studies with shorter follow-up time and lesser numbers of patients, no reoperations were necessary so far [16, 22]. Although the utilization of valved conduits in the modified Nikaidoh procedure inevitably necessitates reoperations, the results of the RVOT performance after the aortic translocation procedure compare favourably with published results of the Rastelli procedure. Posterior translocation of the aortic valve allows orthotopic RVOT reconstruction and leaves more space for the establishment of the right ventricle to pulmonary artery connection. This minimizes the risk of RVOT compression and probably enhances the conduit durability. Translocation techniques which preserve pulmonary valve tissue, such as the *en bloc* rotation or double root location, may further decrease the risk of reoccurring RVOTO due to preserved growth potential of the pulmonary root [19, 23]. In our cohort, four patients received an *en bloc* rotation

and all are free from RVOT reobstruction. However, RVOT reconstruction with patch enlargement of the native pulmonary root may result in significant pulmonary regurgitation, which was observed in one of our patients.

## Limitations

Limitations of this study are inherent to its retrospective nature for which consistency in data acquisition and follow-up examinations are not given. The possibilities of statistical analysis are limited by the small study cohort and short follow-up duration. The long-term benefits of the modified Nikaidoh procedure need to be evaluated with a larger number of patients and longer follow-up interval.

## Conclusion

The anatomic correction of complex TGA with VSD and LVOTO achieved by the Nikaidoh procedure and its modifications results in favourable intracardiac geometry and performance of the reconstructed outflow tracts. The excellent LVOT performance observed makes aortic translocation our procedure of choice for the treatment of this lesion. The major concern remains the necessity of reoperations due to reobstruction of the heterograft reconstructed RVOT. Modifications of the aortic translocation procedure in which pulmonary valve tissue is preserved have the potential to further reduce the need for RVOTO reoperation and consequently may further improve the long-term outcome after correction of complex TGA.

**Conflict of interest:** none declared.

## REFERENCES

- [1] Rastelli GC. A new approach to 'anatomic' repair of transposition of the great arteries. *Mayo Clin Proc* 1969;44:1-12.
- [2] Horer J, Schreiber C, Dworak E, Cleuziou J, Prodan Z, Vogt M *et al.* Long-term results after the Rastelli repair for transposition of the great arteries. *Ann Thorac Surg* 2007;83:2169-75.
- [3] Kreutzer C, De Vive J, Oppido G, Kreutzer J, Gauvreau K, Freed M *et al.* Twenty-five-year experience with Rastelli repair for transposition of the great arteries. *J Thorac Cardiovasc Surg* 2000;120:211-23.
- [4] Dearani JA, Danielson GK, Puga FJ, Mair DD, Schleck CD. Late results of the Rastelli operation for transposition of the great arteries. *Semin Thorac Cardiovasc Surg Pediatr Card Surg Annu* 2001;4:3-15.
- [5] Lee JR, Lim HG, Kim YJ, Rho JR, Bae EJ, Noh CI *et al.* Repair of transposition of the great arteries, ventricular septal defect and left ventricular outflow tract obstruction. *Eur J Cardiothorac Surg* 2004;25:735-41.
- [6] Di Carlo D, Tomasco B, Cohen L, Vouhe P, Lecompte Y. Long-term results of the REV (reparation a l'etage ventriculaire) operation. *J Thorac Cardiovasc Surg* 2011;142:336-43.
- [7] Bex JP, Lecompte Y, Baillot F, Hazan E. Anatomical correction of transposition of the great arteries. *Ann Thorac Surg* 1980;29:86-8.
- [8] Nikaidoh H. Aortic translocation and biventricular outflow tract reconstruction. A new surgical repair for transposition of the great arteries associated with ventricular septal defect and pulmonary stenosis. *J Thorac Cardiovasc Surg* 1984;88:365-72.
- [9] Hraska V. Anatomic correction of corrected transposition {1,D,D} using an atrial switch and aortic translocation. *Ann Thorac Surg* 2008;85:352-3.
- [10] Yeh T Jr, Ramaciotti C, Leonard SR, Roy L, Nikaidoh H. The aortic translocation (Nikaidoh) procedure: mid-term results superior to the Rastelli procedure. *J Thorac Cardiovasc Surg* 2007;133:461-9.
- [11] Bautista-Hernandez V, Marx GR, Bacha EA, del Nido PJ. Aortic root translocation plus arterial switch for transposition of the great arteries with left ventricular outflow tract obstruction: intermediate-term results. *J Am Coll Cardiol* 2007;49:485-90.
- [12] Yamagishi M, Shuntoh K, Matsushita T, Fujiwara K, Shinkawa T, Miyazaki T *et al.* Half-turned truncal switch operation for complete transposition of the great arteries with ventricular septal defect and pulmonary stenosis. *J Thorac Cardiovasc Surg* 2003;125:966-8.
- [13] Pettersen MD, Du W, Skeens ME, Humes RA. Regression equations for calculation of z scores of cardiac structures in a large cohort of healthy infants, children, and adolescents: an echocardiographic study. *J Am Soc Echocardiogr* 2008;21:922-34.
- [14] Brown JW, Ruzmetov M, Huynh D, Rodefeld MD, Turrentine MW, Fiore AC. Rastelli operation for transposition of the great arteries with ventricular septal defect and pulmonary stenosis. *Ann Thorac Surg* 2011;91:188-93.
- [15] Morell VO, Jacobs JP, Quintessenza JA. Aortic translocation in the management of transposition of the great arteries with ventricular septal defect and pulmonary stenosis: results and follow-up. *Ann Thorac Surg* 2005;79:2089-92.
- [16] Hu SS, Liu ZG, Li SJ, Shen XD, Wang X, Liu JP *et al.* Strategy for biventricular outflow tract reconstruction: Rastelli, REV, or Nikaidoh procedure? *J Thorac Cardiovasc Surg* 2008;135:331-8.
- [17] Mair R, Sames-Dolzer E, Vondryš D, Lechner E, Tulzer G. En bloc rotation of the truncus arteriosus—an option for anatomic repair of transposition of the great arteries, ventricular septal defect, and left ventricular outflow tract obstruction. *J Thorac Cardiovasc Surg* 2006;131:740-1.
- [18] Morell VO, Wearden PD. Technique of aortic translocation for the management of transposition of the great arteries with a ventricular defect and pulmonary stenosis. *Oper Tech Thorac Cardiovasc Surg* 2008;13:181-7.
- [19] Mair R. En-bloc rotation of the truncus arteriosus—a technique for complete anatomic repair of transposition of the great arteries/ventricular septal defect/left ventricular outflow tract obstruction or double outlet right ventricle/left ventricular outflow tract obstruction. *Oper Tech Thorac Cardiovasc Surg* 2009;14:45-54.
- [20] Leonard SR, Nikaidoh H. The aortic translocation (Nikaidoh) operation. *Oper Tech Thorac Cardiovasc Surg* 2008;13:172-80.
- [21] Emani SM, Beroukhi R, Zurakowski D, Pigula FA, Mayer JE, del Nido PJ *et al.* Outcomes after anatomic repair for d-transposition of the great arteries with left ventricular outflow tract obstruction. *Circulation* 2009;120:553-58.
- [22] Hazekamp MG, Gomez AA, Koolbergen DR, Hraska V, Metras DR, Mattila IP *et al.* Surgery for transposition of the great arteries, ventricular septal defect and left ventricular outflow tract obstruction: european congenital heart surgeons association multicentre study. *Eur J Cardiothorac Surg* 2010;38:699-706.
- [23] Hu SS, Li SJ, Wang X, Wang LQ, Xiong H, Li LH *et al.* Pulmonary and aortic root translocation in the management of transposition of the great arteries with ventricular septal defect and left ventricular outflow tract obstruction. *J Thorac Cardiovasc Surg* 2007;133:1090-2.