

A non-traumatic, blue-purple auricle: case report

A SEWNAIK, J KAMARASHEV*, N S PETERS†, J B VAN RIJSWIJK‡

Abstract

Objective: We report a typical case of earlobe lymphocytoma.

Method: A case report and literature review are presented.

Results: A 10-year-old girl presented with a blue-coloured earlobe. A diagnosis of Lyme disease was confirmed by serological tests. Lyme borreliosis is the most common tick-borne disease in the northern hemisphere. It is caused by the spirochete *Borrelia burgdorferi sensu lato*. The patient was successfully treated with antibiotics.

Conclusion: The diagnostic process and ENT symptomatology of Lyme disease and borrelial lymphocytoma are summarised and discussed.

Key words: *Borrelia*; Lyme Disease; Earlobe; Lymphocytoma

Introduction

Head and neck manifestations of Lyme borreliosis are common, occurring in up to 75 per cent of cases.^{1,2} Thus, the otolaryngologist may be called upon to diagnose cases lacking the typical history of erythema migrans or recent tick bite (as occurs in approximately 10–40 per cent of all cases).

Borreliosis is caused by the *Borrelia burgdorferi sensu lato* species complex, which is further divided into at least 11 different genomic species.³ Ticks (*Ixodes ricinus* species complex) act as vectors for the transmission of Lyme borreliosis from rodents to humans, and borreliosis is currently the most prevalent tick-transmitted illness in the northern hemisphere.

The borrelia spirochete shares structural similarities with *Treponema pallidum* and, like syphilis, borreliosis may cause systemic illness. However, it is unusual to observe the complete progression of the disease, in which a tick bite leads to a skin lesion, followed by involvement of the cardiovascular and nervous systems, and then arthritis. When diagnosing Lyme borreliosis, one should remember that there is no disease without signs or symptoms, and thus there is no diagnosis in the absence of clinical manifestations.³ In everyday medical practice, the only sign that enables a reliable clinical diagnosis is a typical erythema migrans skin lesion (which occurs in 60–90 per cent of patients with symptomatic infection).⁴

Earlobe lymphocytoma, meningoradiculoneuritis (Garin–Bujadoux–Bannwarth syndrome) and acrodermatitis chronica atrophicans are highly indicative of Lyme borreliosis, but even so, serological and/or microbial (i.e. culture or polymerase chain reaction) analysis is needed for accurate diagnosis. Most other signs and symptoms are of low or even no diagnostic value.³

Case report

A previously healthy 10-year-old girl was referred by her general practitioner because of an unexplained, slowly

progressive, thickened, blue-purple right auricle of several months' duration (Figure 1). After specific questioning, the patient and her mother vaguely remembered an insect bite to the patient's right pinna. They denied any fever, rhinorrhoea, cough, rash, bruising, bleeding or trauma. Upon specific questioning, they also denied any erythema migrans like skin lesions.

Ear microscopy findings and pure tone audiometry were normal. Initial laboratory investigation indicated significantly increased levels of borrelia-specific immunoglobulin (Ig)M and marginally increased levels of IgG antibodies. Testing for borrelia C6 peptide serum antibodies was positive. Liver enzyme tests were normal, and no other laboratory indicators of infection were found (the erythrocyte sedimentation rate was 8 mm/hour, the C-reactive protein level less than 1.0 mg/l and the white blood cell count normal ($6.7 \times 10^9/l$; 38 per cent lymphocytes)). Tests for rheumatoid factors, anti-nuclear antibodies (AnA), anti-proteinase and anti-myeloperoxidase were all negative.

With these results (i.e. right-sided earlobe lymphocytoma and positive borrelia serology), the patient was diagnosed with Lyme disease, and was treated with a 10-day oral course of doxycycline 100 mg twice daily (starting three days after the Figure 1 photographs were taken). Under this treatment, the blue discolouration and thickening of the right pinna resolved completely within several weeks (two weeks after the Figure 1 photographs had been taken, there was hardly any observable difference between the right and left auricle left (Figure 2)).

Discussion

Borrelial lymphocytoma is a solitary, bluish-red swelling or nodule with a diameter of up to a few centimetres, consisting of a dense, B-cell lymphocytic infiltration of the dermis and subcutis. The infiltration is polyclonal with a predominance of B lymphocytes, and often shows germinal centres. The lesion is most frequently located on the earlobe in

From the Department of Otorhinolaryngology, Head and Neck Surgery, Erasmus Medical Center Rotterdam, The Netherlands, the Departments of *Dermatology and †Otorhinolaryngology, Head and Neck Surgery and Facial Plastics, University Hospital Zürich, and ‡Paediatric department of the City-Hospital (Stadsspital) Triemli, Zürich, Switzerland.

Accepted for publication: 6 August 2009. First published online 11 December 2009.

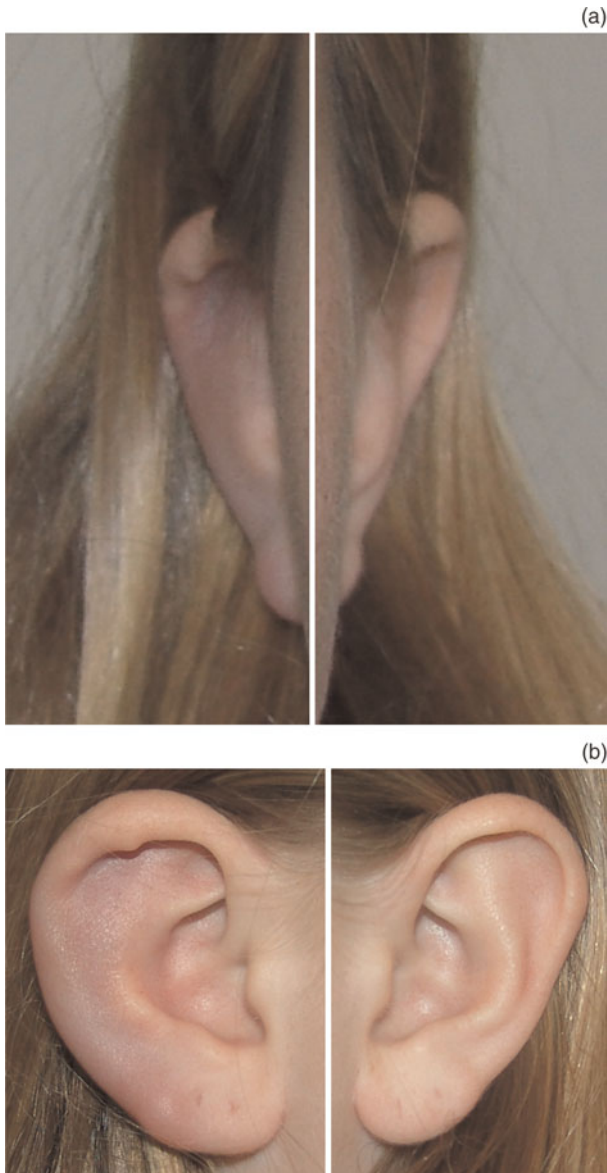


FIG. 1

(a) Anterior and (b) lateral composite views of the patient's right and left ears, 3 days before commencing a 10-day course of oral doxycycline.

children, and in the region of the areola mammae in adults. This rare manifestation of Lyme disease arises later and is of a longer duration than erythema migrans, but finally also resolves spontaneously. Borreliolymphocytoma has been defined as a subacute manifestation of early disseminated Lyme borreliosis, but may sometimes occur at the site of a tick bite (i.e. early localised infection), as was possibly the case in our patient.⁵

A diagnosis of borreliolymphocytoma can be supported by the presence of (or a history of) erythema migrans, by positive serology (as in our patient) or both. Histological examination is needed in patients with lymphocytoma at a location other than the earlobe.³

Borreliolymphocytoma is the most common type of cutaneous B-cell pseudolymphoma, but is the least common skin manifestation of Lyme borreliosis. The clinical differential diagnosis includes insect bite reactions, primary cutaneous (malignant) lymphoma, foreign body granuloma, sarcoidosis, cutaneous metastasis, keloid, perichondritis and granulomatous contact dermatitis.^{4,6}

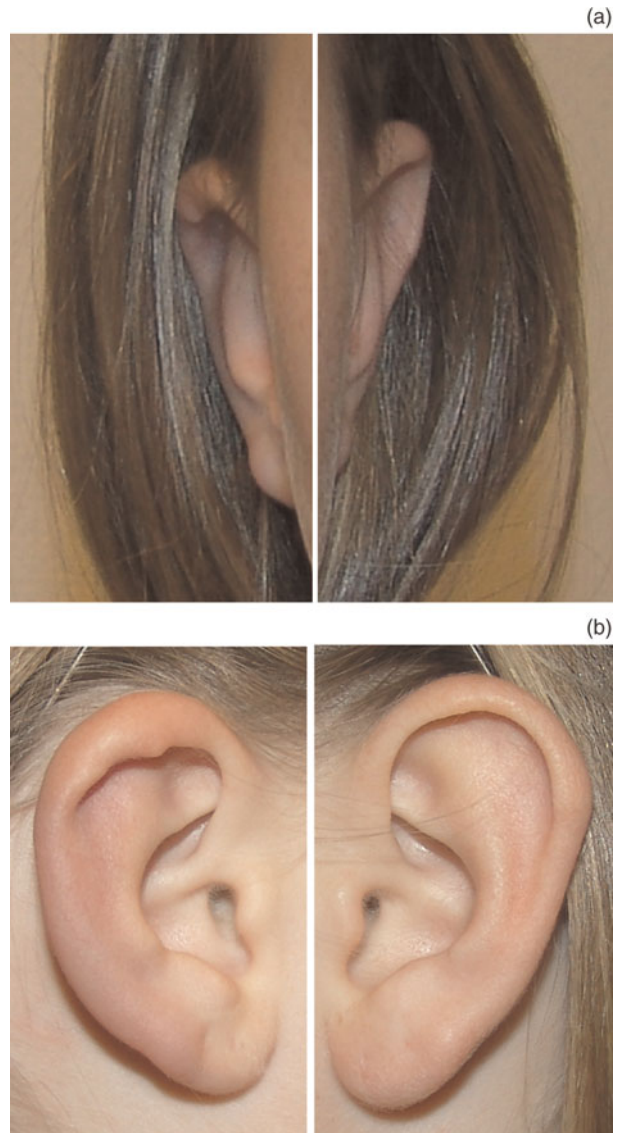


FIG. 2

(a) Anterior and (b) lateral composite views of the patient's right and left ears; photographs taken two weeks after Figure 1.

Lyme disease is a multisystem illness which primarily affects the skin, nervous system, heart and joints. Within this framework, more or less specific head and neck involvement is seen in the majority of patients.^{1,2}

In patients who live in or have travelled through endemic areas, (bilateral) facial nerve palsy (especially in childhood) and (bilateral) sudden hearing loss should prompt the otolaryngologist to consider Lyme disease in the differential diagnosis (although still rare).⁷

Neuroborreliosis can arise at any time during the course of Lyme borreliosis. Early neuroborreliosis typically features aseptic meningitis and involvement of the cranial and peripheral nerves.³

Recently, Oymar and Tveitnes reported the clinical characteristics of children with neuroborreliosis in an endemic area of Scandinavia (from 1996 to 2006, within a university hospital setting).⁸ A total of 143 children were diagnosed with neuroborreliosis. The most common clinical presentations were symptoms of mild meningitis (75 per cent) and/or facial nerve palsy (69 per cent). All cases were diagnosed between April and December, in

keeping with similar studies from other northern European countries, and most were diagnosed between June and October (the peak Lyme disease season), as was our case.

- **Lyme borreliosis is the most common tick-borne disease in the northern hemisphere**
- **The diagnosis can be very difficult because many of the symptoms are similar to those of other disorders**
- **When confronted with unclear skin lesions and/or other unusual symptoms, especially facial nerve palsy and/or sudden hearing loss, the otolaryngologist should not hesitate to include Lyme disease in the differential diagnosis**

Although the causal relationship between Lyme borreliosis and sensorineural hearing loss is difficult to verify, Lyme neuroborreliosis is a rare but potentially treatable cause of sudden deafness and/or vestibular neuronitis.⁷ It can be accompanied by musical or other auditory hallucinations.⁹

Conclusion

In view of the likelihood of head and neck manifestations of Lyme disease, the otolaryngologist may be called upon to diagnose cases lacking a history of erythema migrans or recent tick bite.⁴ Lyme disease is a clinical diagnosis, and laboratory tests should only be used to clarify diagnostic issues. Diagnosing Lyme disease can be very difficult because many of its symptoms are similar to those of other disorders. When confronted with unclear skin lesions and/or other unusual symptoms, especially facial nerve palsy and/or sudden hearing loss, the otolaryngologist should not hesitate to include Lyme disease in the differential diagnosis. The presented case serves as a reminder that a non-traumatic, blue-coloured ear lesion should trigger investigation for Lyme disease.

References

- 1 Lesser TH, Dort JC, Simmen DP. Ear, nose and throat manifestations of Lyme disease. *J Laryngol Otol* 1990;**104**: 301–4
- 2 Moscatello AL, Worden DL, Nadelman RB, Wormser G, Lucente F. Otolaryngologic aspects of Lyme disease. *Laryngoscope* 1991;**101**:592–5
- 3 Stanek G, Strle F. Lyme borreliosis. *Lancet* 2003;**362**:1639–47
- 4 Mullegger RR. Dermatological manifestations of Lyme borreliosis. *Eur J Dermatol* 2004;**14**:296–309
- 5 Asbrink E, Hovmark A. Early and late cutaneous manifestations in Ixodes-borne borreliosis (erythema migrans borreliosis, Lyme borreliosis). *Ann N Y Acad Sci* 1988;**539**:4–15
- 6 Grange F, Wechsler J, Guillaume JC, Tortel J, Tortel MC, Audhuy B *et al.* Borrelia burgdorferi-associated lymphocytoma cutis simulating a primary cutaneous large B-cell lymphoma. *J Am Acad Dermatol* 2002;**47**:530–4
- 7 Quinn SJ, Boucher BJ, Booth JB. Reversible sensorineural hearing loss in Lyme disease. *J Laryngol Otol* 1997;**111**: 562–4
- 8 Oymar K, Tveitnes D. Clinical characteristics of childhood Lyme neuroborreliosis in an endemic area of northern Europe. *Scand J Infect Dis* 2009;**41**:88–94
- 9 Stricker RB, Winger EE. Musical hallucinations in patients with Lyme disease. *South Med J* 2003;**96**:711–15

Address for correspondence:
Dr Jeroen B van Rijswijk,
ENT Surgeon and Facial Plastics,
ORL-Klinik,
Universitäts-Spital Zürich,
Frauenklinikstrasse 24,
8091 Zürich, Switzerland.

E-mail: jeroen@vanryswyk.nl

Dr J B van Rijswijk takes responsibility for the integrity of the content of the paper.
Competing interests: None declared
