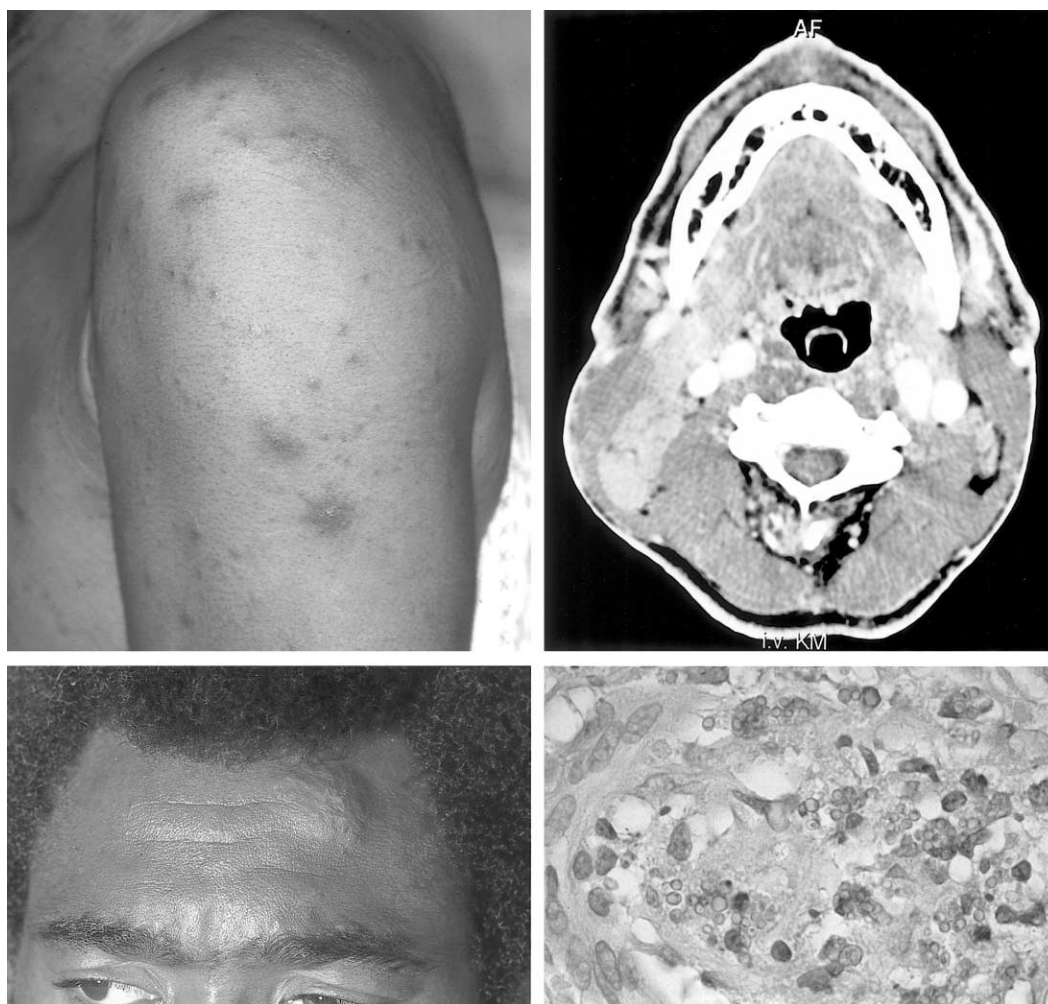


## ANSWER TO PHOTO QUIZ

Philip A. Mackowiak, Section Editor

## African Immigrant with Weight Loss and Disseminated Skin Lesions

(See pages 698–9 for Photo Quiz)



**Figure 1.** Upper left, Photograph showing skin lesions on arm and shoulder of patient. Upper right, CT scan of neck revealing multiple enlarged lymph nodes. Lower left, Detail of a skin ulcer on forehead of patient. Lower right, Histologic examination of skin biopsy specimen showing perivascular infiltrates of neutrophil granulocytes and ovoid yeasts (diameter, 15  $\mu\text{m}$ ) and a thick cell wall (periodic acid–Schiff stain; original magnification,  $\times 400$ ).

Diagnosis: Disseminated African histoplasmosis in an African patient with AIDS.

The disease process included skin eruptions, bone lesions, and hematologic and multiple-organ involvement, and the cause was *Histoplasma capsulatum* var. *duboisii*.

*H. capsulatum* var. *duboisii*, the causative agent of African histoplasmosis, is a thermally dimorphic fungus that grows in

mold form at 25°C and in yeast form at 37°C. Compared with *H. capsulatum* var. *capsulatum*, *H. capsulatum* var. *duboisii* is much larger (12–15 vs. 2–4  $\mu\text{m}$ ) and has a thicker wall, although mycelial forms are indistinguishable. African histoplasmosis is endemic in Central and West Africa south of the Sahara and north of the Zambezi River. As a result of intensification of travel and immigration, the number of cases of African his-

toplasmosis is likely to increase in industrialized countries in the future. The natural habitat is soil contaminated with bird droppings or bat excrement. It is thought that *H. capsulatum* var. *duboisii* enters the body through the lungs, although primary pulmonary infection has not been demonstrated. Although cutaneous inoculation is an alternative mode of acquisition, human-to-human transmission is not a significant route of infection transmission.

Patients usually present with focal disease affecting the skin, subcutaneous tissue, and bone, leading to skin ulcers or nodules, subcutaneous tender nodules, and osteolytic bone lesions (mainly in the skull, ribs, and vertebrae). A rare case of involvement of the gastrointestinal tract that mimics gastrointestinal cancer has also been reported [1]. In addition, a rapidly progressive systemic dissemination with multiple-organ involvement (including liver, spleen, lung, and kidney) is possible. There is no clear correlation between host immune status and infection with *H. capsulatum* var. *duboisii* [2].

Diagnosis chiefly relies on demonstration of the quite characteristic large, oval yeasts seen on direct microscopic examination of tissue biopsy specimens (figure 1, lower right). Confirmation by culture is possible, but difficult, because the long generation time (6 to >30 h, depending on medium and inoculum) allows for growth of saprophytic fungi and bacteria.

Antigen testing of blood or urine specimens has adequate sensitivity only for disseminated disease, which is quite rare in patients with African histoplasmosis. The results of serologic tests are generally negative [3], because cross-reaction may occur with *Blastomyces* species and *Coccidioides immitis*. The histoplasmin skin test is of epidemiological interest only. Most patients with a positive reaction to *H. capsulatum* var. *duboisii* antigen also react positively to *H. capsulatum* var. *capsulatum* antigen, and vice versa.

The standard treatment for *H. capsulatum* var. *duboisii* infection is amphotericin B at a dosage of 1 mg/kg per day, with a minimum cumulative dose of 2 g [4, 5]. Itraconazole and ketoconazole are alternatives mainly for the nondisseminated form of disease or for use after induction therapy with amphotericin B. Fluconazole is less active than itraconazole against *H. capsulatum* infection [6, 7]; moreover, resistance to fluconazole may develop [8]. Caspofungin has little activity in vivo [9]. Prolonged treatment ( $\geq 6$  months) is mandatory to decrease the risk of relapse. Our patient received systemic amphotericin B (1 mg/kg of body weight) for 2 weeks, followed

by itraconazole (400 mg per day for 10 weeks, then 200 mg per day) maintenance therapy, which is also used for the classic form of histoplasmosis.

Prognosis of focal disease is affected by relapses that occur up to several years after antifungal therapy has been stopped, which makes the term "remission" more accurate than "cure," unless data from prolonged follow-up are available. The outcome for disseminated African histoplasmosis in HIV-positive patients has been poor thus far [10]. Our experience demonstrates that, even in these cases, remission is possible, if early diagnosis is followed by adequate antimycotic therapy.

**Barbara Hasse and Andreas Kronenberg**

Division of Infectious Diseases and Hospital Epidemiology,  
University Hospital Zurich, Zurich, Switzerland

## References

1. Khalil M, Iwatt AR, Gugnani HC. African histoplasmosis masquerading as carcinoma of the colon: report of a case and review of the literature. *Dis Colon Rectum* **1989**;32:518–20.
2. Al-Abdely H, Graybill JR. Histoplasmosis, blastomycosis, coccidioidomycosis, and cryptococcosis. In: *Tropical infectious diseases*. New York: Churchill Livingstone, **1999**:626–9.
3. Manson's tropical diseases. 20th ed. Philadelphia: WB Saunders, **1996**.
4. Hajjeh RA. Disseminated histoplasmosis in patients infected with the human immunodeficiency virus. *Clin Infect Dis* **1995**;21(Suppl 1):S108–10.
5. Lortholary O, Denning DW, Dupont B. Endemic mycoses, a treatment update. *J Antimicrob Chemother* **1999**;43:321–31.
6. Bullock WE. *Histoplasma capsulatum*. In: Mandell GL, Bennett JE, Dolin R, eds. *Mandell, Douglas, and Bennett's principles and practice of infectious diseases*. 5th ed. New York: Churchill Livingstone, **1999**:2720–31.
7. Sarosi GA, Johnson PC. Disseminated histoplasmosis in patients infected with the human immunodeficiency virus. *Clin Infect Dis* **1992**;14(Suppl 1):S60–7.
8. Wheat LJ, Hafner R, Wulfsohn M, et al. Prevention of relapse of histoplasmosis with itraconazole in patients with the acquired immunodeficiency virus syndrome. *Ann Intern Med* **1993**;118:610.
9. Kohler S, Wheat LJ, Connolly P, et al. Comparison of the echinocandin caspofungin with amphotericin B for treatment of histoplasmosis following pulmonary challenge in a murine model. *Antimicrob Agents Chemother* **2000**;44:1850–4.
10. Ramdial P, Mosam A, Dlova NC, Saar N, Aboobaker J, Singh SM. Disseminated cutaneous histoplasmosis in patients infected with human immunodeficiency virus. *J Cutan Pathol* **2002**;29:215–25.

Reprints or correspondence: Dr. Barbara Hasse, Div. of Infectious Disease and Hospital Epidemiology, University Hospital, CH-8091 Zürich, Switzerland (b.hasse@gmx.ch).

**Clinical Infectious Diseases** **2003**;37:726–7

© 2003 by the Infectious Diseases Society of America. All rights reserved.  
1058-4838/2003/3705-0018\$15.00