

Varicella-Zoster Virus Is Strongly Associated with Atypical Necrotizing Herpetic Retinopathies

J. Garweg and M. Böhnke

From the Department of Ophthalmology, University of Bern, Inselspital, Bern, Switzerland

Aqueous humor samples from nine patients with atypical necrotizing retinopathies of suspected viral origin, six with acute retinal necrosis syndrome (ARN), and 17 with active cytomegalovirus (CMV) retinitis underwent amplification for viral DNA of herpes simplex virus type 1 (HSV-1), varicella-zoster virus (VZV), and human CMV. VZV DNA was detected in seven of the nine aqueous humor samples from patients with atypical necrotizing retinopathies of suspected viral origin and in four of the six samples from individuals with ARN; of the two other samples from patients with ARNS, no viral DNA was found in one, and both CMV DNA and HSV-1 DNA, but not VZV DNA, were detected in one (this patient presented with bilateral ARNS 2 months after being successfully treated for CMV retinitis). Thus, VZV is likely to be the main pathogen of atypical necrotizing herpetic retinopathies. DNA amplification may be used to establish an early, sensitive, and reliable diagnosis of any form of necrotizing retinopathy in 80% of cases, irrespective of viral etiology.

Acute necrotizing retinitis has long been recognized as an associated complication of several disorders in which symptoms of an immunocompromised state, such as Hodgkin's disease, are manifested [1–3]. However, Urayama et al. [4] were the first to describe this condition in immunocompetent, otherwise healthy individuals, and they termed it acute retinal necrosis syndrome (ARN). The well-defined clinical picture includes acute iridocyclitis, vitritis, visual deterioration, necrotizing retinitis, occlusive retinal vasculitis, and eventually rhegmatogenous detachment of the atrophic retina.

In unilaterally diagnosed cases of acute necrotizing retinitis, subsequent involvement of the other eye occurs within 1 year in 30% [5] to 70% [6] of cases, but late involvement after a lapse of up to 26 years has been reported [7]; risk to the second eye can be reduced by about 80% [6] if virustatic therapy with acyclovir is administered for ≥ 3 months. Patients may have a history of previous systemic disease, such as herpes simplex or zoster dermatitis, but by no means is this a matter of course [8, 9]. In immunocompromised patients, lesions of suspected viral origin do not always bear the hallmarks of well-characterized clinical syndromes, such as ARN or cytomegalovirus (CMV) retinopathy, and these lesions have been categorized together under the designation "necrotizing herpetic retinopathies" [10].

After an individual has become infected, it is reasonable to expect that viral particles will remain predominantly cell-associated. For this reason, cultures of samples from the

virtually cell-free aqueous and vitreous compartments are negative; therefore, such means cannot be used to establish viral etiology [9, 11, 12]. However, analysis of paired aqueous and serum samples for the existence of specific antibodies has led to successful diagnoses in 65% of cases [13–15]; if this procedure is carried out on a sequential basis, 72%–86% of cases may be successfully diagnosed [16].

Of course, more invasive measures, such as vitreoretinal biopsy, may also be implemented to confirm viral etiology [17], but these measures are indicated only in cases where the disease progresses despite therapy and implicates both eyes; however, a specific infrastructure is required for their execution, and this substructure is not always available [18]. By using DNA detection methods, the infection may be diagnosed in < 48 hours after the onset of clinical symptoms [19], and this result can then be later corroborated by sequential serological analysis.

In this prospective study, aqueous humor samples from patients with recently diagnosed atypical necrotizing retinopathies of unknown origin, patients with ARN, and patients with CMV retinitis underwent DNA amplification and hybridization with primers for different viruses of the family of herpesviruses. The data for the patients with atypical necrotizing retinopathies were compared with those for the patients with ARN and patients with CMV retinitis.

Patients

Between 1990 and 1995, 32 patients presenting with necrotizing retinopathies of suspected viral origin were treated at the Departments of Ophthalmology at the University of Hamburg (Hamburg, Germany) and the University of Bern (Bern, Switzerland) (table 1). Aqueous humor samples were collected from these patients and from 30 healthy controls undergoing anterior segment surgery. On the basis of clinical findings, ocular pa-

Received 3 June 1996; revised 1 October 1996.

Reprints or correspondence: Dr. J. Garweg, Department of Ophthalmology, University of Bern, Inselspital, CH-3010 Bern, Switzerland.

Clinical Infectious Diseases 1997;24:603–8

© 1997 by The University of Chicago. All rights reserved.
1058-4838/97/2404-0010\$02.00

Table 1. Diagnoses for 32 patients presenting with necrotizing retinopathies.

Clinical diagnosis, history	No. of patients	No. with history of zoster dermatitis
Atypical retinopathy of suspected viral origin	9	6
Remission after chemotherapy for Hodgkin's disease	1	1
HIV infection	2	2
AIDS	6	3
Acute retinal necrosis syndrome	6	0
No previous disease	5	0
AIDS	1	0
Cytomegalovirus retinitis, AIDS	17	NA

NOTE. Additional information may be obtained from the text under the heading of Patients. NA = data not available.

thologies fell into one of three categories: atypical retinopathies, ARN, and CMV retinitis.

Atypical retinopathies of unknown origin. Atypical retinopathy was diagnosed for nine patients since the clinical picture did not meet the criteria for either ARN or CMV retinitis as defined by the American Uveitis Society [10, 20]. One of these individuals had a history of Hodgkin's disease, which was in remission following chemotherapy that had been administered 2 years before; zoster dermatitis was diagnosed 6 months prior to presentation for acute retinopathy. Two HIV-positive patients had a history of zoster dermatitis that occurred 3 and 6 months, respectively, prior to presentation for retinopathy; in the latter case, viral encephalitis was diagnosed, and CSF from this patient was also analyzed.

Of the six patients with AIDS, three had a history of zoster dermatitis during the 8 months prior to presentation for retinopathy; one of these patients had had contralateral zoster keratouveitis 3 days before presentation for bilateral retinopathy. The remaining three patients with AIDS presented without a history of herpetic infection at any site. A subretinal fluid sample was obtained from one of these patients at the time of retinal detachment surgery; this procedure was performed 9 days after the diagnosis of retinopathy at which time foscarnet therapy was started.

ARN. ARN was diagnosed for five patients (two with bilateral involvement) according to the criteria of the American Uveitis Society [4, 10, 21]. In addition to aqueous humor samples, subretinal fluid specimens were also obtained from two patients at the time of retinal detachment surgery. A sixth patient with AIDS presented with bilateral ARN 2 months after stabilization of CMV retinitis. This individual's CD4⁺ cell count spontaneously increased from 50 to 200/ μ L before the actual diagnosis of the disease.

CMV retinitis. On the basis of standard clinical criteria [10, 20], CMV retinitis was diagnosed for 17 patients with AIDS.

Controls. Controls included 30 healthy individuals who had no signs of inflammatory ocular disease and who were undergoing anterior segment surgery (mostly cataract operations).

Methods

Aqueous humor, subretinal fluid, and CSF samples were centrifuged (13,000g for 10 minutes), and the sediments were resuspended in 10 mM Tris buffer (pH 8.3) containing 0.1% Tween 20 and 200 μ g of proteinase K/mL (Sigma, St. Louis). These suspensions were then heated, initially to 56°C for 60 minutes and subsequently to 95°C for 10 minutes. Aliquots were obtained on a routine basis for viral cultures by using human embryonal lung fibroblasts (MRC-5 cells) as the host cell; a culture was considered to be negative if no cytopathic effect was observed after 20 days.

DNA amplification was performed according to conventional protocols; the primers were based on previously reported sequences of the glycoprotein D gene [22] and the thymidine kinase gene [23] of herpes simplex virus type 1 (HSV-1) as well as those of main immediate early genes of varicella-zoster virus (VZV) (*Xba*I M region [24]) and CMV (MIE 6/7 region [25]). The amplification mix (final volume, 50 μ L) contained 5 μ L of resuspended sample pellet or supernatant, 40 pM primer, 200 μ M desoxynucleoside triphosphates, 10 mM Tris (pH 8.3), 50 mM KCl, 2 mM MgCl₂, 0.02% gelatin, and 1 U of *Thermus brockianus* DNA polymerase (Finnzymes, Espoo, Finland).

After initial DNA denaturation at 95°C for 5 minutes, 35 amplification cycles were performed; each cycle consisted of denaturation at 95°C for 30 seconds, primer annealing at 60°C (HSV-1) or 58°C (VZV and CMV) for 30 seconds, and fragment elongation at 72°C for 90 seconds. Final elongation was then done at 72°C for 10 minutes. PCR products were separated on 3% agarose gels, and after the gels were stained with 0.03% ethidium bromide, bands were visualized by scanning at 312 nm.

DNA was then transferred to nylon membranes (Hybond-N⁺, Amersham, Arlington Heights, IL) and hybridized (buffer composition, 5 \times saline sodium citrate, 50% formamide, 0.5% *N*-lauroylsarkosin, 0.02% SDS, and 2% blocking reagent [Boehringer Mannheim, Mannheim, Germany]) with use of oligonucleotides randomly labeled with digoxigenin and the chemoluminescence detection system outlined by the manufacturer (Boehringer Mannheim).

All buffer solutions used in this study were included as negative controls; internal positive controls included lysates of infected MRC-5 cell cultures and aqueous humor samples spiked with small amounts of HSV-1, VZV, and CMV.

Results

Each of the nine patients with necrotizing herpetic retinopathies and the six patients with ARN had serum antibodies to

VZV. In three of the patients with ARN, the titers of VZV in both aqueous and serum samples were sufficiently high as to permit an unequivocal assignment of etiology (data not presented), but none of the MRC-5 cell cultures of the aqueous humor samples yielded viral growth.

Sensitivity of PCR analysis and Southern blotting. PCR analysis of HSV-1 glycoprotein D revealed 10^{-3} pfu per sample after 35 DNA amplification cycles and 2×10^{-4} pfu after Southern blot hybridization. After Southern blot hybridization, 1.5 pg of VZV DNA per sample of cell culture supernatants was detected. After amplification, $<10^{-1}$ pfu of CMV DNA per sample was disclosed. Spiking with small amounts of viral DNA did not result in significant inhibition of amplification in aqueous humor samples, but amplification in subretinal fluid samples was somewhat inhibited after spiking.

Both proteinase K-digested sediments and supernatants from all aqueous humor samples were tested; viral DNA was not detected exclusively in the supernatant in any instance, but in one-third of the positive sediments, DNA was not amplified from the corresponding supernatant. The results of DNA detection in aqueous humor samples are summarized in table 2.

Atypical retinopathies of suspected viral origin. VZV DNA was amplified in aqueous humor samples from seven of the nine patients, including the patient with Hodgkin's disease; two samples contained no target DNA after repeated testing. Neither HSV-1 DNA nor CMV DNA was found in any of the samples from these individuals. VZV DNA was detected in the CSF sample from the patient with viral encephalitis; this result was in accordance with the result for the aqueous humor sample.

ARN. VZV DNA was found in aqueous humor samples from four of six patients with ARN; in one sample, no viral DNA was detected (table 2) (figure 1). Strong signals of amplification for both HSV-1 DNA and CMV DNA were found in the aqueous humor samples from the patient with AIDS and bilateral ARN. VZV DNA was detected in one of the two subretinal fluid samples from two otherwise healthy patients with secondary retinal detachment; the samples were obtained

at the time of surgery, which was performed 8–15 days after the onset of therapy. During the subsequent symptom-free follow-up (3–24 months), no viral DNA was detected in any of seven aqueous humor samples from the patient for whom VZV DNA was found in the aqueous humor sample and the subretinal fluid sample obtained at the time of retinal detachment surgery.

CMV retinitis. CMV DNA was detected in 14 of the 17 aqueous humor samples from patients with AIDS and CMV retinitis. DNA from the thymidine kinase gene, but not from the glycoprotein D gene, of HSV-1 was amplified to a lesser degree in two of the samples from CMV-positive individuals, but in no instance was VZV DNA found (table 2).

Healthy controls. No viral DNA was detected in any of the aqueous humor samples from healthy controls. The likelihood of finding VZV DNA in samples from patients with atypical retinopathies of suspected viral origin is significantly greater than that in samples from patients with CMV retinitis or healthy controls ($P < .0001$; Fisher's exact test) but not than that in samples from patients with ARN ($P = 1.0$; Fisher's exact test).

Discussion

The results of the current investigation reveal a close correlation between the manifestation of atypical necrotizing retinopathies and the presence of VZV DNA, a finding that has not been previously reported. However, living virus was not detected in any of the aqueous humor samples from our patients. With respect to the clinical picture itself, the association between acute necrotizing retinopathies and Herpesviridae [3, 26] has been long debated [27]. It was not until 1976 that the first electron microscopic studies identified HSV [28] and VZV [29] as possible etiologic agents. Using immunocytochemistry and electron microscopy, Culbertson et al. [21] demonstrated the presence of viral particles in the retina of eyes enucleated from patients with ARN, and later they [11] were able to isolate VZV in cell cultures of one of two enucleated eyes. However,

Table 2. Detection of viral DNA in aqueous humor samples from patients with necrotizing retinopathies and healthy controls.

No. of patients	Clinical diagnosis	No. of samples			
		No DNA	HSV-1 DNA	VZV DNA	CMV DNA
9	Atypical retinopathies of suspected viral origin	2	0	7	0
6	Acute retinal necrosis syndrome	1	1	4	1
17	CMV retinitis	3	2*	0	14
30	Healthy	30	0	0	0

NOTE. CMV = cytomegalovirus; HSV-1 = herpes simplex virus type-1; VZV = varicella-zoster virus.
 * DNA from the thymidine kinase gene, but not from the glycoprotein D gene, of HSV-1 was detectable at low copy numbers (only after DNA hybridization) in two of the CMV-positive aqueous humor samples.

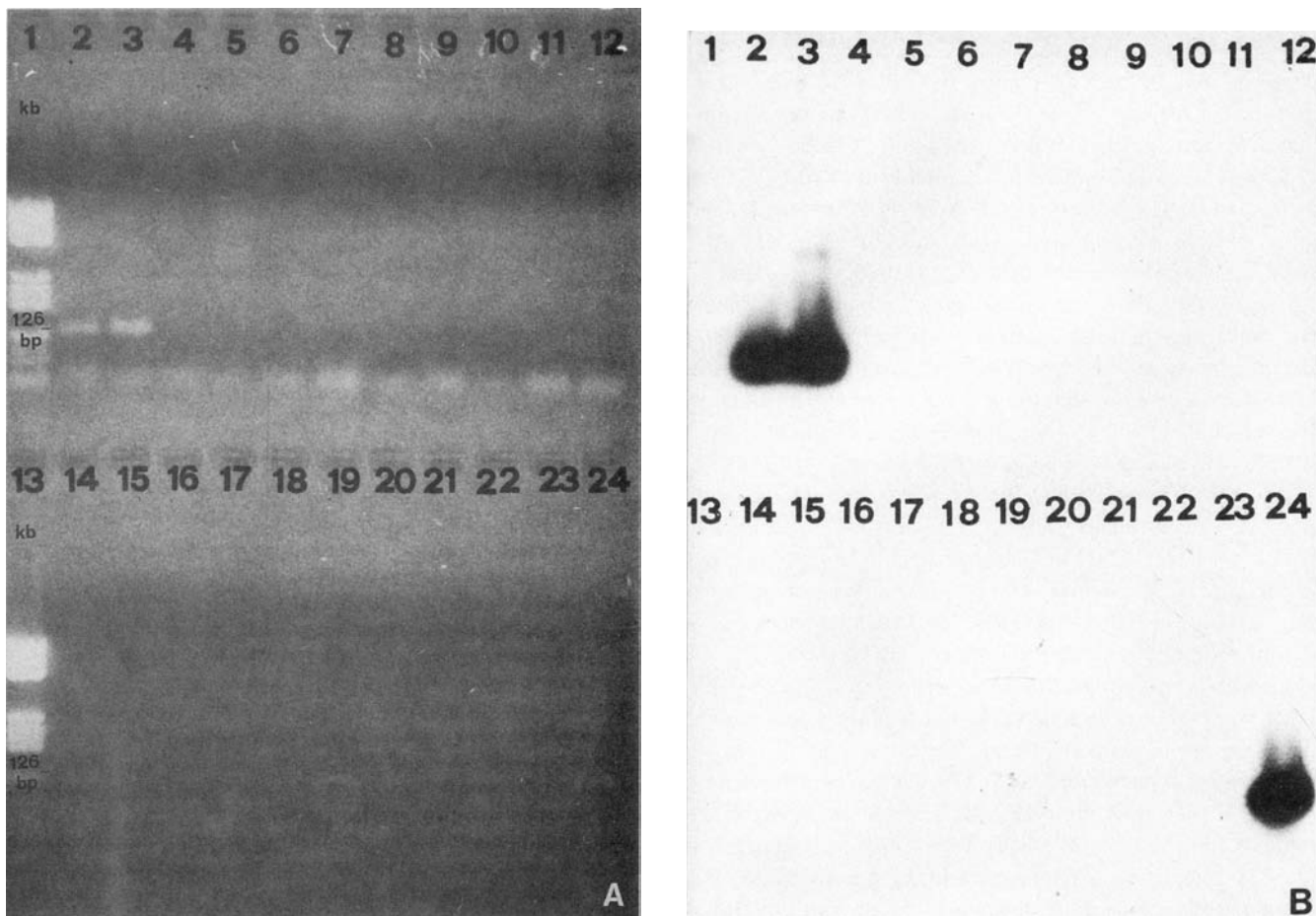


Figure 1. *A.* Varicella-zoster virus (VZV) DNA (126 bp in length) detected in aqueous humor samples from patients with necrotizing retinopathies; band patterns after 35 amplification cycles. PCR products were separated on a 3% agarose gel after staining with 0.01% ethidium bromide (left) and after Southern blot and DNA hybridization with use of a digoxigenin-labeled probe (right). *Lanes 1 and 13*, molecular weight markers; *lanes 2–5*, patient with acute retinal necrosis syndrome (2, aqueous humor sediment; 3, aqueous humor supernatant; 4, peripheral blood monocytes [PBMC]; 5, serum); *lanes 6–8 and 21*, aqueous humor samples from patients with AIDS and cytomegalovirus retinitis; *lanes 9–12 and 14–17*, patient with zoster keratouveitis (9–12, aqueous humor samples at diagnosis [9 and 10] and 2 weeks later [11 and 12]; 14–17, corneal tissue samples); *lanes 18–20 and 22*, immunocompetent, otherwise healthy patient with retinal vasculitis of possible viral origin (18, aqueous humor sediment; 19, aqueous humor supernatant; 20, PBMC; 22, serum); *lane 23*, buffer control; and *lane 24*, positive control (supernatant from VZV-infected cell culture). *B.* Chemoluminescence detection of bound probe after Southern blot and DNA hybridization from the gel in *A*. kb = kilobases.

since that time, only nine cases of viral origin have been proven by cultures of aqueous and vitreous samples collected at the time of diagnosis, and three of these cases occurred in patients with AIDS [30, 31].

Recently, the viral etiology in culture-negative cases of ARN was confirmed by electron microscopic demonstration of viral particles, antigen immunofluorescence testing, and/or immunocytology; infection was found to be attributable to VZV in 80% of these cases [20, 30, 32–34]. These data correspond well with our findings with respect to the presence of VZV DNA in aqueous humor samples from patients with ARN; this agreement is encouraging since it indicates that amplification of DNA in aqueous humor samples represents an appropriate method for detecting the causative agent of acute retinopathies.

Moreover, the fact that aqueous humor samples are suitable for such purposes obviates the necessity of obtaining vitreous or subretinal fluid samples. Indeed, these latter specimens may represent inferior sources of material for DNA amplification from the point of view of sensitivity (and hence of detection limits) since when these samples were spiked with small amounts of target DNA the amplification was somewhat inhibited in comparison with the amplification in aqueous humor samples.

The association found between VZV and atypical necrotizing retinopathies is comparable with those existing between VZV and ARN [19] and between CMV and retinitis [24, 25, 35]. No VZV DNA was detected in 17 aqueous humor samples from patients with AIDS and CMV retinitis, but evidence for

a dual infection with HSV-1 and CMV was found in two of the patients with CMV retinitis and in one patient with ARN; such an association also has been reported in other studies [16, 24, 36].

At present, PCR technology is not generally accepted as a standard laboratory procedure, albeit it has been employed for the diagnosis of well-defined necrotizing retinopathies (such as ARN and CMV retinitis) as well as for the detection of DNA from HSV-1 [12, 19, 37], HSV type 2 [38], VZV [19, 31, 39], CMV [24, 25, 35], Epstein-Barr virus [40], and human herpesvirus 6 [36]. Data derived by such means should therefore always be confirmed by established methods. PCR findings were confirmed by serological investigations of paired samples in 50% of our cases of ARN [16], but such analysis was not undertaken for individuals with atypical necrotizing retinopathies.

In summary, our data, taken together with the findings reported in the literature, indicate that early, reliable identification of the pathogenic agent may be ascertained by PCR analysis in 70%–80% of cases of necrotizing retinopathies of any form at the time of diagnosis, irrespective of the causative agent. Atypical necrotizing retinopathies are most likely caused by an infection of the retina with VZV.

Acknowledgment

The authors thank Dr. T. Fenner (Bernhard Nocht-Institut für Schifffahrts und Tropenmedizin, Hamburg, Germany) for his help in the selection of appropriate primers and for establishing the PCR system for detection of varicella-zoster virus that was used in this study.

References

- Hegner CA. Retinitis exsudativa bei Lymphogranulomatosis. *Klin Monatsbl Augenheilkd* 1916;57:27.
- Marquardt R. Augenveränderungen bei maligner Lymphogranulomatose. *Klin Monatsbl Augenheilkd* 1961;138:535–44.
- Kurz GH. Retinopathy of obscure (toxic?) origin in Hodgkin's disease. *Am J Ophthalmol* 1964;57:205–13.
- Urayama A, Yamada N, Sasaki T, et al. Unilateral acute uveitis with periarteritis and detachment. *Jpn J Clin Ophthalmol* 1971;25:607–19.
- Fisher JP, Lewis ML, Blumenkranz MS, et al. The acute retinal necrosis syndrome. Part I: clinical manifestations. *Ophthalmology* 1982;89:1309–16.
- Palay DA, Sternberg P Jr, Davis J, et al. Decrease in the risk of bilateral acute retinal necrosis by acyclovir therapy. *Am J Ophthalmol* 1991;112:250–5.
- Martinez J, Lambert HM, Capone A, et al. Delayed bilateral involvement in the acute retinal necrosis syndrome [letter]. *Am J Ophthalmol* 1992;113:103–4.
- Yeo JH, Pepose JS, Stewart JA, Sternberg P Jr, Liss RA. Acute retinal necrosis syndrome following herpes zoster dermatitis. *Ophthalmology* 1986;93:1418–22.
- Duker JS, Nielsen JC, Eagle RC Jr, Bosley TM, Granadier R, Benson WE. Rapidly progressive acute retinal necrosis secondary to herpes simplex virus type 1. *Ophthalmology* 1990;97:1638–43.
- Holland GN, the Executive Committee of the American Uveitis Society. Standard diagnostic criteria for the acute retinal necrosis syndrome. *Am J Ophthalmol* 1994;117:663–7.
- Culbertson WW, Blumenkranz MS, Pepose JS, Stewart JA, Curtin VT. Varicella-zoster virus is a cause of the acute retinal necrosis syndrome. *Ophthalmology* 1986;93:559–69.
- Forster DJ, Dugel PU, Frangieh GT, Liggett PE, Rao NA. Rapidly progressive outer retinal necrosis in the acquired immunodeficiency syndrome. *Am J Ophthalmol* 1990;110:341–8.
- Suttorp-Schulten MSA, Zaal MJW, Luyendijk L, Bos PJM, Kijlstra A, Rothova A. Aqueous humor tap and serology in acute retinal necrosis [letter]. *Am J Ophthalmol* 1989;108:327–8.
- Luyendijk L, van der Horn GJ, Visser OHE, et al. Detection of locally produced antibodies to herpes viruses in the aqueous of patients with acquired immune deficiency syndrome (AIDS) or acute retinal necrosis syndrome (ARN). *Curr Eye Res* 1990;9(suppl):7–11.
- de Boer JH, Luyendijk L, Rothova A, et al. Detection of intraocular antibody production to herpesviruses in acute retinal necrosis syndrome. *Am J Ophthalmol* 1994;117:201–10.
- Pepose JS, Flowers B, Stewart JA, et al. Herpesvirus antibody levels in the etiologic diagnosis of the acute retinal necrosis syndrome. *Am J Ophthalmol* 1992;113:248–56.
- Martin DF, Chan C-C, de Smet MD, et al. The role of chorioretinal biopsy in the management of posterior uveitis. *Ophthalmology* 1993;100:705–14.
- Freeman WR, Wiley CA, Gross JG, Thomas EL, Rao NA, Liggett PE. Endoretinal biopsy in immunosuppressed and healthy patients with retinitis: indications, utility, and techniques. *Ophthalmology* 1989;96:1559–65.
- Gerling J, Neumann-Haefelin D, Seuffert HM, Schrader W, Hansen LL. Diagnosis and management of the acute retinal necrosis syndrome. *Ger J Ophthalmol* 1992;1:388–93.
- Culbertson WW. Infections of the retina in AIDS. *Int Ophthalmol Clin* 1989;29:108–18.
- Culbertson WW, Blumenkranz MS, Haines H, Gass DM, Mitchell KB, Norton EWD. The acute retinal necrosis syndrome. Part 2: histopathology and etiology. *Ophthalmology* 1982;89:1317–25.
- Aurelius E, Johansson B, Sköldenberg B, Staland A, Forsgren M. Rapid diagnosis of herpes simplex encephalitis by nested polymerase chain reaction assay of cerebrospinal fluid. *Lancet* 1991;337:189–92.
- Lynas C, Cook SD, Laycock KA, Bradfield JWB, Maitland NJ. Detection of latent virus mRNA in tissues using the polymerase chain reaction. *J Pathol* 1989;157:285–9.
- Garweg J, Fenner T, Böhnke M, Schmitz H. An improved technique for the diagnosis of viral retinitis from samples of aqueous humor and vitreous. *Graefes Arch Clin Exp Ophthalmol* 1993;231:508–13.
- Fenner TE, Garweg J, Hufert FT, Boehnke M, Schmitz H. Diagnosis of human cytomegalovirus-induced retinitis in human immunodeficiency virus type 1-infected subjects by using the polymerase chain reaction. *J Clin Microbiol* 1991;29:2621–2.
- Aaberg TM, Cesarz TJ, Rytel MW. Correlation of virology and clinical course of cytomegalovirus retinitis. *Am J Ophthalmol* 1972;74:407–15.
- Rochat C, Herbort CP. Syndrome de nécrose rétinienne aiguë (ARN/BARN/PORN). Casuistique lausannoise, revue de la littérature et nouvelle hypothèse physiopathogénique. *Klin Monatsbl Augenheilkd* 1994;204:440–9.
- Minkler DS, McLean EB, Shaw CM, Hendrickson A. *Herpesvirus hominis* encephalitis and retinitis. *Arch Ophthalmol* 1976;94:89–95.
- Schwartz JN, Cashwell F, Hawkins HK, Klintworth GK. Necrotizing retinopathy with herpes zoster ophthalmicus: a light and electron microscopic study. *Arch Pathol Lab Med* 1976;100:386–91.
- Margolis TP, Lowder CY, Holland GN, et al. Varicella-zoster virus retinitis in patients with the acquired immunodeficiency syndrome. *Am J Ophthalmol* 1991;112:119–31.

31. Hellinger WC, Bolling JP, Smith TF, Campbell RJ. Varicella-zoster virus retinitis in a patient with AIDS-related complex: case report and brief review of the acute retinal necrosis syndrome. *Clin Infect Dis* **1993**;16:208–12.
32. Friberg TR, Jost BF. Acute retinal necrosis in an immunosuppressed patient [letter]. *Am J Ophthalmol* **1984**;98:515–7.
33. Jabs DA, Schachat AP, Liss R, Knox DL, Michels RG. Presumed varicella zoster retinitis in immunocompromised patients. *Retina* **1987**;7:9–13.
34. Soushi S, Ozawa H, Matsuhashi M, Shimazaki J, Saga U, Kurata T. Demonstration of varicella-zoster virus antigens in the vitreous aspirates of patients with acute retinal necrosis syndrome. *Ophthalmology* **1988**;95:1394–8.
35. Fox GM, Crouse CA, Chuang EL, et al. Detection of herpesvirus DNA in vitreous and aqueous specimens by polymerase chain reaction. *Arch Ophthalmol* **1991**;109:266–71.
36. Quavi HB, Green MT, SeGall GK, Font RL. Demonstration of HIV-1 and HHV-6 in AIDS-associated retinitis. *Curr Eye Res* **1989**;8:379–87.
37. Sado K, Kimura T, Hotta Y, et al. Acute retinal necrosis syndrome associated with herpes simplex keratitis. *Retina* **1994**;14:260–3.
38. Thompson WS, Culbertson WW, Smiddy WE, Robertson JE, Rosenbaum JT. Acute retinal necrosis caused by reactivation of herpes simplex virus type 2. *Am J Ophthalmol* **1994**;118:205–11.
39. Nishi M, Hanashiro R, Mori S, Masuda K, Mochizuki M, Hondo R. Polymerase chain reaction for the detection of the varicella-zoster genome in ocular samples from patients with acute retinal necrosis. *Am J Ophthalmol* **1992**;114:603–9.
40. Grossniklaus HE, Aaberg TM, Purnell EW, Luka J, Seemayer TA. Retinal necrosis in X-linked lymphoproliferative disease. *Ophthalmology* **1994**;101:705–9.