

## References

- [1] Previtali M, Lanzarini L, Fetteveu R *et al.* Comparison of dobutamine stress echocardiography, dipyridamole stress echocardiography and exercise stress testing for diagnosis of coronary artery disease. *Am J Cardiol* 1993; 72: 865-70.
- [2] Smart SC, Sawada S, Ryan T *et al.* Low-dose dobutamine echocardiography detects reversible dysfunction after thrombolytic therapy of acute myocardial infarction. *Circulation* 1993; 88: 405-15.
- [3] Mertes H, Sawada SG, Ryan T *et al.* Symptoms, adverse effects and complications associated with dobutamine stress echocardiography. Experience in 1118 patients. *Circulation* 1993; 88: 15-19.
- [4] Mathias W, Pingitore A, Bigi R *et al.* Safety of dobutamine-atropine echocardiography: preliminary results of a multicenter trial. *Circulation* 1993; 88: 1-404.
- [5] Poldermans D, Fioretti PM, Boersma E *et al.* Safety of dobutamine-atropine stress echocardiography in patients with suspected or proven coronary artery disease. *Am J Cardiol* 1994; 73: 456-9.

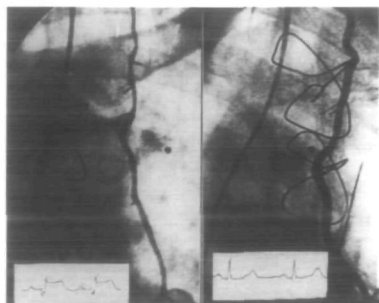
#### Internal mammary artery spasm immediately after grafting to the left anterior descending artery: diagnosis and treatment

Internal mammary artery (IMA) spasm may result in transmural anterior myocardial infarction<sup>[1]</sup>. We report a case of sudden inferior ischaemia 5 h after aorto-coronary bypass. Following emergency angiographic verification of a mammary artery spasm, an additional venous bypass of the distal left anterior descending (LAD) coronary artery was performed which relieved the ischaemia and rescued the myocardium at risk.

The left IMA has become the conduit of choice for bypass grafting of the LAD coronary artery. As perioperative IMA spasm may result in myocardial infarction<sup>[1]</sup>, a number of techniques<sup>[2,3]</sup> are employed intraoperatively to increase the flow in the recently implanted IMA.

We report the case of a patient with inferior ischaemia due to early post-operative IMA spasm. A 63-year-old man had triple vessel disease; the ejection fraction of the left ventricle was 63% and a stress exercise test revealed significant ST segment depression in leads V<sub>4</sub> to V<sub>6</sub>. At surgery, two saphenous vein grafts were used to bypass the right postero-lateral and posterior descending and the left

postero-lateral and intermediate coronary arteries. Following mild hydrostatic dilatation with papaverine in accordance with the technique of Mills and Breau<sup>[4]</sup>, the left IMA was implanted into the LAD. The post-bypass electrocardiogram (ECG) was normal and the cardiac index was 3.7 l . m<sup>-2</sup> . min<sup>-1</sup>. Nifedipine (10 µg . min<sup>-1</sup>) was infused throughout the procedure and continued in the intensive care unit. The mean arterial blood pressure was maintained between 70 and 90 mmHg. The patient did well until 5 h after surgery when he became haemodynamically unstable and low cardiac output was diagnosed. A 12-lead ECG revealed new ST segment elevations in leads II, III and aVF. An emergency cardiac catheterization was performed. Coronary arteriography showed patent grafts, although the IMA was in severe spasm (Fig. 1). While the nifedipine infusion was continued, nitroglycerin was administered directly into the proximal IMA, resulting in an immediate increase in the size of the IMA. This normalized the ECG in leads II, III and aVF (Fig. 1). Several minutes later, the IMA went into spasm again, leading to inferior ischaemia on the ECG. Despite two further intramammary nitroglycerin challenges, the IMA remained in spasm. Whilst haemodynamically stable, the patient underwent an immediate cardiopulmonary bypass and the distal third of the LAD was incised without aortic cross-clamping. The anastomosis between the IMA and the LAD was found to be patent. There was no antegrade flow from the IMA. A saphenous vein graft was implanted into the distal LAD and anastomosed to the ascending aorta. Weaning from



**Figure 1** Left: Early post-operative spasm of the left IMA with electrocardiographic signs of inferior ischaemia. Right: Left IMA with normal ECG following direct infusion of nitroglycerin.

cardiopulmonary bypass was uneventful. Postoperative cardiac enzymes and ECG were normal. Tranoesophageal echocardiography revealed normal left ventricular function with normal segmental wall motions, indicating that permanent myocardial damage had not occurred. The patient was discharged on the 6th postoperative day.

Despite a number of preventive measures, including intraluminal administration of papaverine, continuous infusion of a calcium antagonist and maintenance of aortic pressure, spontaneous IMA spasm may occasionally occur in the early and late postoperative phases<sup>[1,5]</sup>. This may result in haemodynamic instability and possibly trans-myocardial infarction<sup>[1]</sup>. Interestingly, in the current case, the IMA spasm led to inferior ischaemia which was clearly demonstrated by the immediate postoperative bypass angiogram performed under continuous 12-lead electrocardiography. Postoperative ECG, cardiac enzymes and tranoesophageal echocardiography indicated that a distal vein bypass to the LAD, when performed immediately, may result in rescue of the ischaemic myocardium.

P. R. VOGT

O. HESS

M. I. TURINA

*Clinic for Cardiovascular Surgery,  
University Hospital,  
Rämistrasse 100,  
CH-8091 Zurich, Switzerland*

## References

- [1] Stone GW, Hartzler GO. Spontaneous reversible spasm in an internal mammary artery graft causing acute myocardial infarction. *Am J Cardiol* 1989; 64: 822-3.
- [2] Nappi G, Tritto FP, Falco A, Longbardi FF, Cotrufo M. New surgical technique for harvesting the internal mammary artery. *Tex Heart Inst J* 1994; 21: 134-7.
- [3] He GW, Buxton BF, Rosenfeld FL, Angus JA, Tatoulis J. Pharmacologic dilatation of the internal mammary artery during coronary artery bypass grafting. *J Thorac Cardiovasc Surg* 1994; 107: 1440-4.
- [4] Mills NL, Breau JR. Invited comment. *Eur J Cardiothorac Surg* 1993; 7: 163.
- [5] Kong B, Kopleman Harry, Segal BL, Iskandrian Abdulmassih S. Angiographic demonstration of spasm in a left internal mammary artery used as a bypass to the left anterior descending coronary artery. *Am J Cardiol* 1988; 61: 1363.