



ELSEVIER

European Journal of Cardio-thoracic Surgery 21 (2002) 121–123

 EUROPEAN JOURNAL OF
 CARDIO-THORACIC
 SURGERY

www.elsevier.com/locate/ejcts

Case report

Delayed heart perforation after blunt trauma

Thierry Roth^a, Beat Kipfer^b, Jukka Takala^c, Ralph A. Schmid^{a,*}^aDivision of General Thoracic Surgery, University Hospital, 3010 Berne, Switzerland^bDivision of Cardiovascular Surgery, University Hospital, Berne, Switzerland^cDivision of Intensive Care Medicine, University Hospital, Berne, Switzerland

Received 30 April 2001; received in revised form 21 September 2001; accepted 14 October 2001

Abstract

A 33-year-old patient was hospitalized after a blunt chest trauma with a left flail chest. Six hours after admission to the intensive care unit the patient suddenly developed hypotension and tachycardia. His left chest tube drained 1.5 l of blood within minutes. Immediate resuscitation and emergency sternotomy with left anterolateral extension was performed for pericardial tamponade secondary to left ventricular perforation due to a sharp rib fragment. Outcome was favourable and the patient was operated on for his flail chest by internal stabilization the next day. © 2002 Elsevier Science B.V. All rights reserved.

Keywords: Heart perforation; Ventricle laceration; Lung perforation; Blunt chest trauma; Flail chest

1. Introduction

Traumatic injuries, following cardiovascular disease and cancer, are the third most common cause of death in occidental countries. In the United States approximately 90 000 accidental deaths and 9 million disabling injuries are committed annually, and 75% of the casualties from blunt trauma are due to chest injuries [1].

2. Case report

A 33-year-old man was referred from a regional hospital to our centre after a blunt chest trauma. At work, he was crushed between a tractor and a tree. He complained of left thoracic pain without dyspnea. The chest X-ray disclosed multiple rib fractures from the fourth to the eighth rib on the left side, with subcutaneous emphysema (Fig. 1a). The patient's previous medical history was uneventful. On admission, 3 h after the accident, he was conscious and stable with arterial blood pressure of 150/90 mmHg and heart rate of 109/min, saturation was 94% with 6 l/min oxygen. Clinically a paradoxical motion of the left chest wall could be observed. Blood analysis showed a hyperleucocytosis of 20.8 g/l, creatine kinase elevation of 861 IU/l but troponin < 0.6 µg/l. A left lateral chest tube was immediately inserted which drained 150 ml blood. A computed

tomography (CT) scan of the thorax and abdomen was performed confirming a left haemothorax and the rib fractures which were moderately displaced. In addition, a diffuse contralateral lung contusion was present (Fig. 2). An antibiotic prophylaxis with amoxicillin/clavulanic acid was initiated. The operative indication for flail chest stabilization was considered and planned for the next day. A peridural analgesia (with bupivacaine 1 mg/ml, fentanyl 2 µg/ml and adrenaline 2 µg/ml) was initiated and the patient was transferred to the intensive care unit (ICU) with minimal chest pain. Six hours after admission, he turned in his bed and immediately complained of transfixiant chest pain, the arterial blood pressure fell abruptly to non-measurable levels, and the chest tube drained 1500 ml blood within minutes. Immediate resuscitation with volume perfusion, vasoactive drugs (adrenaline) i.v., intubation and heart massage was instituted while the patient was transferred to the adjacent operative room. An emergency sternotomy with left anterolateral extension (hemi-clamshell) was performed. After drainage of a pericardial blood tamponade, systemic blood pressure rose immediately. A left ventricular perforation of 15 mm length close to the apex was quickly discovered and controlled by finger pressure, then closed with non-absorbable monofilament suture reinforced by Teflon felt. The pericardium was partially closed. A lung perforation of the lingula with air leak was resected using an endo-GIA 45-mm stapler. Two sharp, distal, rib fragments were removed, including the one responsible for the heart perforation. A pericardial tube and two thoracic tubes were

* Corresponding author. Tel.: +41-31-632-2330; fax: +41-31-632-2327.
 E-mail address: ralph.schmid@insel.ch (R.A. Schmid).

inserted. After completion of surgery the patient was haemodynamically stable, after receiving 11 blood concentrates, 6 fresh frozen plasmas and 4000 ml colloid.

On the next day the patient showed no neurological deficit and was operated on as planned for his left flail chest stabilization, with reconstruction plates and 4.0-mm cancellous screws. The patient did not develop any post-operative respiratory failure and was immediately extubated. The post-operative chest X-ray disclosed no relevant findings (Fig. 1b), and post-operative echocardiography demonstrated good left ventricle function (ejection fraction 70%) with slight pericardial effusion. After removal of chest drains, the patient was discharged from hospital on the 12th post-operative day.

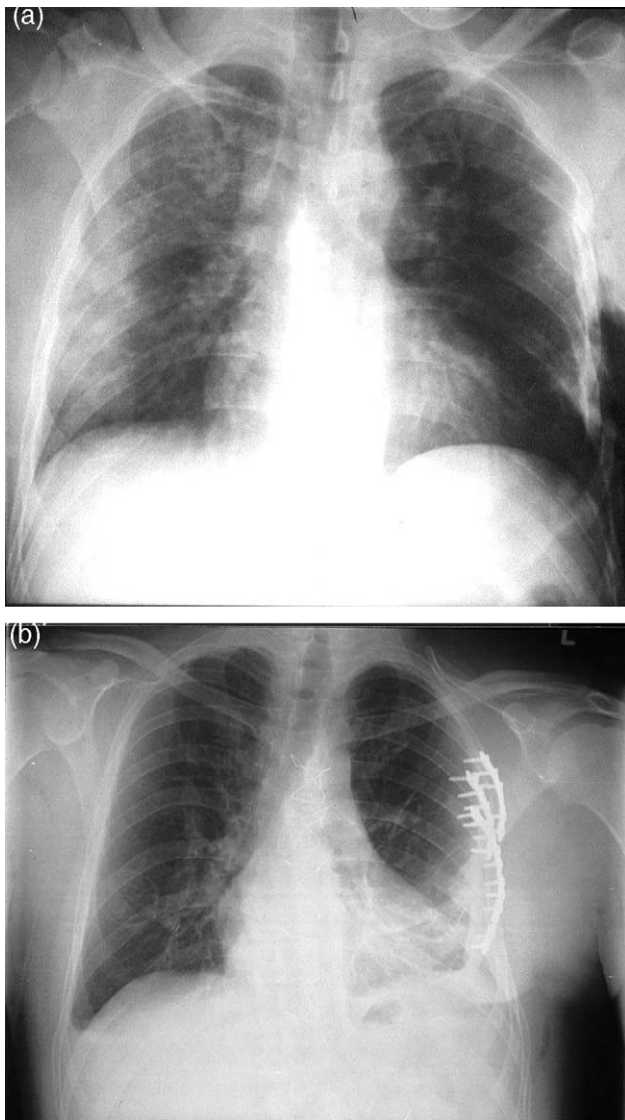


Fig. 1. Chest X-ray on admission (a) and after operative internal fixation with removal of the chest tubes (b).

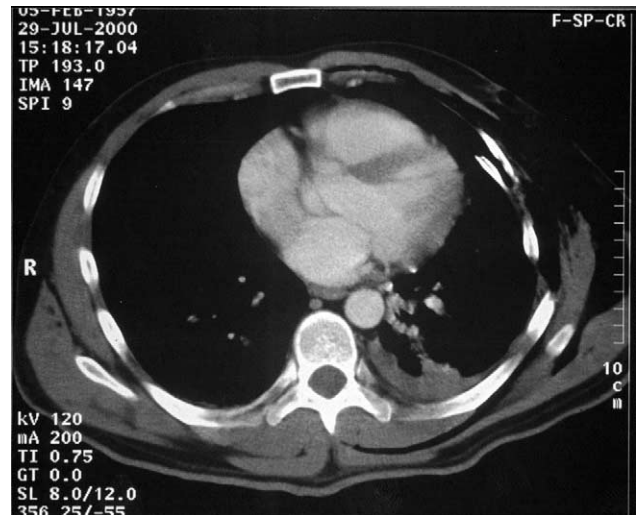


Fig. 2. CT of the thorax on admission with the rib fractures and the chest-wall deformity.

3. Discussion

Rib fractures occur frequently after any chest trauma and are also often disclosed after some abdominal or pelvic major trauma. Surgical treatment is usually not required, merely good analgesia to avoid any occurrence of lung atelectasis or pneumonia. Flail chest with paradoxical respiration or thoracic deformity may be considered for an operative rib stabilization.

Heart perforation occurs very exceptionally after blunt chest trauma. In most cases it results from penetrating injuries such as stab wound (69%), gun shot (26%) or others (5%), but less than 20% of the injured patients reach the hospital alive [1]. Most frequently the right ventricle is penetrated (46%), followed by the left ventricle (30%) and the right atrium (11%). Heart perforation by rib fragments occur in general immediately after the injury, are fatal in most cases, and are hence not documented. Secondary heart perforation should not be misdiagnosed with secondary cardiac rupture (right atrium 41%, right ventricle 31%, left atrium 25% and left ventricle 9%) after heart contusion, which is also a relatively uncommon complication (0.3%), with a consecutive mortality rate as high as 80% [2]. In the literature, heart perforation due to a fractured rib after blunt chest trauma has been reported in only four patients [3–5]. All of these were caused by motor vehicle accidents. Only one patient was haemodynamically stable prior to surgery. These four heart injuries happened with a delay of 3 h to 15 days after the accident. It seems, however, that secondary perforation with haemodynamically unstable patients occurs within the first 24 h (3, 4 and in our case, 6 h). In three cases the left ventricle, and in one case the right ventricle, was injured.

A CT scan of the chest is usually performed in the case of flail chest to demonstrate the chest deformity and the potential underlying visceral lesions [3], but secondary perfora-

tion cannot be definitively precluded by this examination. Only two of the four patients reported in the literature survived after secondary heart lesion [4,5]. This mechanism of heart perforation after blunt trauma should be known, because emergency surgery is life-saving in this condition.

This case demonstrates the potentially fatal complications which may occur in patients after major chest trauma, particularly with flail chest, even if they have been initially haemodynamically stable. This should be considered in post-traumatic care of patients after blunt chest trauma. Therefore we suggest an observation on ICU-setting for 24 h in a centre with cardiothoracic surgery abilities. Early internal rib stabilization of left flail chest might prevent the occurrence of secondary heart perforation.

References

- [1] Calhoun JH, Grover FL, Trinkle JK. Chest trauma, approach and management. *Clin Chest Med* 1992;13:55–67.
- [2] Brathwaite CE, Rodriguez A, Turney SZ, Dunham CM, Cowley R. Blunt traumatic cardiac rupture: a 5-year experience. *Ann Surg* 1990;212:701–704.
- [3] Galvin IF, Costa R, Murton M. Fractured rib with penetrating cardio-pulmonary injury. *Ann Thorac Surg* 1993;56(3):558–559.
- [4] Glock Y, Roux D, Dalous P, Puel P. Left ventricular perforation by rib fracture after closed chest injury. A propos of 2 cases. *Ann Chir* 1986;40(2):98–101.
- [5] Bourguignon N, Godier S, Genevois A, Kaeffer N, Dureuil B. Heart injury following closed thoracic injury. *Ann Fr Anesth Reanim* 1996;15(7):1088–1089.