

the 5-year DFS rate was 74%. Both JCOG0205 [14] and ACTS-CC [2] in which oxaliplatin was not used and D3 lymph node dissection was a standard surgery showed similar or better DFS than that with oxaliplatin in the Western pivotal studies [3–5].

Prolonged peripheral neuropathy and high medical cost are clinically and socially significant problems in oxaliplatin-based adjuvant chemotherapy. We have believed that if radical surgery with sufficient lymph node dissection and anatomically optimal mesocolic excision is carried out, less-toxic and less-expensive oral FUs without oxaliplatin could obtain comparable treatment outcome to oxaliplatin-containing regimens.

However, there is the poor prognostic subgroup in stage III. ACTS-CC02 trial which is a phase III study investigating benefit of adding oxaliplatin to FU under D3 dissection surgery for N2 colon cancer patients is in progress [15].

K. Sugihara^{1*}, M. Yoshida² & M. Ishiguro³

¹Department of Surgical Oncology, Tokyo Medical and Dental University, Graduate School, Tokyo;

²Cancer Chemotherapy Center, Osaka Medical College Hospital, Osaka;

³Department of Translational Oncology, Tokyo Medical and Dental University, Graduate School, Tokyo, Japan

(*E-mail: k-sugi.srg2@tmd.ac.jp)

funding

This work was supported by the Foundation for Biomedical Research and Innovation, Translational Research Informatics Center, under the funding contract with Taiho Pharmaceutical Co. Ltd., Japan.

disclosure

KS has received consulting fees from Taiho Pharmaceutical Co. Ltd, Chugai Pharmaceutical Co. Ltd, Bayer Yakuhin, Ltd, Bristol-Myers Squibb, and Merck Serono Co. Ltd; honoraria from Taiho, Takeda Pharmaceutical Co. Ltd, Chugai, Yakult Honsha Co. Ltd, Bristol-Myers, Merck Serono, and Kyowa Hakko Kirin Co. Ltd; research funding from Taiho, Otsuka Pharmaceutical Factory, Inc., Takeda, Chugai, Yakult Honsha, Daiichi Sankyo Co. Ltd, Bristol-Myers, Merck Serono, Kyowa Hakko Kirin, Ono Pharmaceutical Co. Ltd, Tsumura & Co., Eisai Co. Ltd, Torii Pharmaceutical Co. Ltd, and Kaken Pharmaceutical Co. Ltd.

MY has received honoraria from Taiho, Takeda, Chugai, Bristol-Myers, Merck Serono, Bayer; research funding from Taiho, Takeda, Chugai, Bristol-Myers, Daiichi Sankyo, Sanofi K. K., Kyowa Hakko Kirin, Nippon Kayaku Co. Ltd., Ono, and Jansen Pharmaceutical K. K.

MI has received consulting fees and research funding from Taiho; honoraria from Taiho, Chugai, and Yakult Honsha.

references

1. Huseyin A, Yavuz S, Calkusu Z, Seyrek E. Is fluoropyrimidines without oxaliplatin optimal for the adjuvant treatment of mainstream stage III colon cancer? *Ann Oncol* 2014; 26: 245.

2. Yoshida M, Ishiguro M, Ikejiri K et al. S-1 as adjuvant chemotherapy for stage III colon cancer: a randomized phase III study (ACTS-CC trial). *Ann Oncol* 2014; 25 (9): 1743–1749.
3. André T, Boni C, Navarro M et al. Improved overall survival with oxaliplatin, fluorouracil, and leucovorin as adjuvant treatment in stage II or III colon cancer in the MOSAIC trial. *J Clin Oncol* 2009; 27: 3109–3116.
4. Yothers G, O'Connell MJ, Allegra CJ et al. Oxaliplatin as adjuvant therapy for colon cancer: updated results of NSABP C-07 trial, including survival and subset analyses. *J Clin Oncol* 2011; 29: 3768–3774.
5. Haller DG, Tabernero J, Maroun J et al. Capecitabine plus oxaliplatin compared with fluorouracil and folinic acid as adjuvant therapy for stage III colon cancer. *J Clin Oncol* 2011; 29: 1465–1471.
6. de Gramont A, Chibaudel B, Bachet JB et al. From chemotherapy to targeted therapy in adjuvant treatment for stage III colon cancer. *Semin Oncol* 2011; 38: 521–532.
7. Rousseau B, Chibaudel B, Bachet JB et al. Stage II and stage III colon cancer-treatment advances and future directions. *Cancer J* 2010; 16: 202–209.
8. Watanabe T, Itabashi M, Shimada Y et al. Japanese Society for Cancer of the Colon and Rectum (JSCCR) guidelines 2010 for the treatment of colorectal cancer. *Int J Clin Oncol* 2012; 17: 1–29.
9. Ishiguro M, Watanabe T, Kotake K, Sugihara K. Japanese Society for Cancer of the Colon and Rectum (JSCCR) guidelines 2010 for the treatment of colorectal cancer; comparison with Western guidelines. *Colorect Cancer* 2013; 2: 179–190.
10. Ishiguro M, Higashi T, Watanabe T, Sugihara K. Changes in colorectal cancer care in Japan before and after guideline publication: a nationwide survey about D3 lymph node dissection and adjuvant chemotherapy. *J Am Coll Surg* 2014; 218: 969–977.
11. West NP, Hohenberger W, Weber K et al. Complete mesocolic excision with central vascular ligation produces an oncologically superior specimen compared with standard surgery for carcinoma of the colon. *J Clin Oncol* 2010; 28: 272–278.
12. West NP, Kobayashi H, Takahashi K et al. Understanding optimal colonic cancer surgery. Comparison of Japanese D3 resection and European complete excision with central vascular ligation. *J Clin Oncol* 2012; 30: 1763–1769.
13. Hohenberger W, Werber K, Matzel K et al. Standardized surgery for colonic cancer: complete mesocolic excision and central ligation-technical notes and outcome. *Colorectal Dis* 2009; 11: 354–364.
14. Shimada Y, Hamaguchi T, Mizusawa J et al. Randomised phase III trial of adjuvant chemotherapy with oral uracil and tegafur plus leucovorin versus intravenous fluorouracil and levofoflinate in patients with stage III colorectal cancer who have undergone Japanese D2/D3 lymph node dissection: final results of JCOG0205. *Eur J Cancer* 2014; 50: 2231–2240.
15. Takiuchi H, Tomita N, Boku N et al. Preplanned initial safety analysis of ACTS-CC 02 trial: a large randomized phase III trial of SOX versus UFT/LV as adjuvant chemotherapy for high-risk stage III colon cancer. *J Clin Oncol* 2012; 30: 4s (abstr 572).

doi: 10.1093/annonc/mdu476

Published online 14 October 2014

A novel germline mutation of PDGFR-β might be associated with clinical response of colorectal cancer to regorafenib

We report an extraordinary response to regorafenib in a patient with metastatic adenocarcinoma of the rectum. In order to identify the molecular target of this response, we analyzed 409 cancer genes by next-generation sequencing (NGS) of the genomic DNA (patient tumor and blood) and discovered a germline mutation of the platelet-derived growth factor receptor

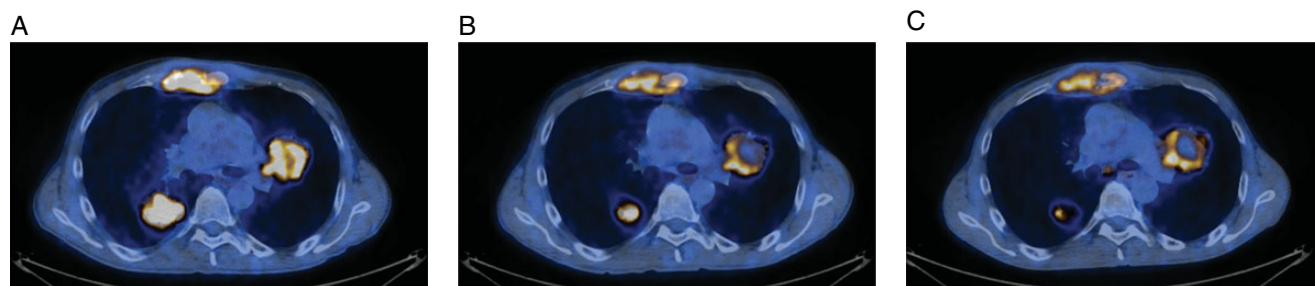


Figure 1. Positron emission tomography/computed tomography scans at baseline (A), after 8 weeks of treatment (B), after 5 months of treatment (C).

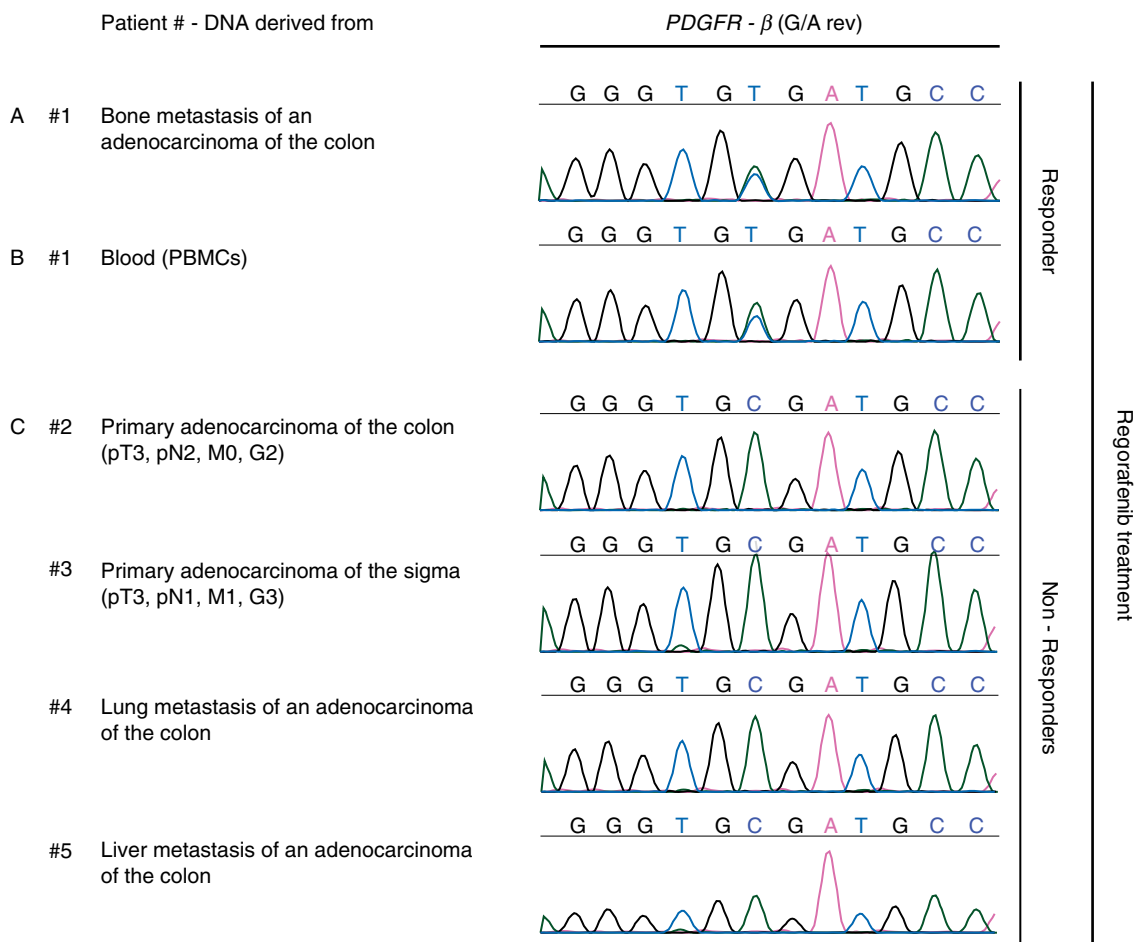


Figure 2. Sanger sequencing of platelet-derived growth factor receptor β (PDGFR- β). (A) To verify the variant in PDGFR- β which was detected by next-generation sequencing (NGS) in the responder to regorafenib, the same DNA derived from tumor tissue as used for NGS was amplified for the region of interest and sequenced by Sanger sequencing. The variant p.A6V was successfully verified. (B) To investigate whether the verified mutation in PDGFR- β is tumor specific, DNA was isolated from peripheral blood mononuclear cells (PBMCs) (blood) from the responder to regorafenib and sequenced by Sanger sequencing. The variant p.A6V was detected in PBMCs as well and thus defined as germline mutation. (C) To analyze whether the germline mutation p.A6V in PDGFR- β may be a private mutation in the responder to regorafenib, tumor samples of four additional colon carcinoma patients which did not respond to regorafenib treatment were sequenced for the specific mutation in PDGFR- β . None of the nonresponders to regorafenib exhibited the mutation p.A6V.

β (PDGFR- β) gene, a target of regorafenib. The patient (male, Caucasian) was diagnosed with rectal cancer at the age of 37 years; the initial stage was pT3pN0cM0. The patient underwent initially a rectal resection and adjuvant chemotherapy. Seven years later, recurrence of disease with metastases was diagnosed. Molecular analysis of the tumor demonstrated a *KRAS* wild-type genotype. The patient underwent multiple systemic treatments

over 5 years. At this time, the patient became symptomatic with pain and cough due to bone and lung metastases (Figure 1A). Treatment with regorafenib was initiated. After 8 weeks, a positron emission tomography/computed tomography scan showed a partial morphological and metabolic response (Figure 1B) according to RECIST criteria. After 9 months from beginning of this therapy, the patient is still in partial remission with

significant improvement of the symptoms (Figure 1C). Regorafenib inhibits the angiogenic and stromal receptor tyrosine kinases, vascular endothelial growth factors receptors, tyrosine kinase endothelial 2 and PDGFR- β . In colorectal cancer patients, objective responses to regorafenib have been rarely observed (1% response rate [1]). As our patient showed a response lasting over 9 months, we analyzed the patient's tumor by NGS using targeted amplification with the AmpliSeq [2] Comprehensive Cancer panel (Ion Torrent, Life Technologies) which includes all exons of 409 cancer genes; the amplified regions were sequenced according to [3]. Alignment, variant calling and filtering were done with Ion Reporter v4.0 (Life Technologies) and are summarized in supplementary Tables S1 and S2, available at *Annals of Oncology* online. We detected a nonsynonymous point mutation of PDGFR- β at codon 6 (p. A6V) which was confirmed by Sanger sequencing (Figure 2A). This mutation has already been described in the COSMIC database (ID = 1435169) as a unique case out of 367 colon carcinomas investigated. As this represents a rare mutation, we sequenced this region in the genomic DNA derived from the patient's peripheral blood mononuclear cells and detected the same strong heterozygous signal, demonstrating this to be a germline mutation (Figure 2B). Moreover, we could exclude the presence of this mutation in the genomic DNA derived from tumor samples of four patients affected by metastatic colorectal cancer not responding to regorafenib (Figure 2C). A strong and homogenous expression of PDGFR- β could be detected in the patient's tumor compared with the nonresponder patients (supplementary Figure S1, available at *Annals of Oncology* online). PDGF and their receptors (PDGFR- α , PDGFR- β and PDGFR- $\alpha\beta$) play a critical role in cancer development [4, 5]. Mutations involving up-regulation of PDGF and/or PDGFR have been documented in a number of solid tumors and hematological malignancies. In colon cancer, previous reports have shown sensitivity of a cell line with mutation (p.T681I) of PDGFR- β , to sorafenib [6] and a recent case report described another germline mutation in exon 19 of PDGFR- β [7] associated with increased pathway activation and survival. To date, mutations of PDGFR- β have not been correlated to response to regorafenib, neither in cell lines nor in patients. Here we describe for the first time the germline mutation c.17C>T (NM_002609.3) of PDGFR- β , a target of regorafenib and hypothesize that this mutation, in the signal peptide of PDGFR- β , might have an oncogenic driver potential [8]. Although objective responders to regorafenib are rare, it would be of major interest to confirm this result in a larger group of patients to define if PDGFR- β is a predictive marker to this treatment.

M. Rechsteiner^{1†}, P. Wild^{1†}, M. K. Kiessling², A. Bohnert¹, Q. Zhong¹, R. A. Stahel², H. Moch¹ & A. Curioni-Fontecedro^{2*}

¹Institute of Surgical Pathology;

²Department of Oncology, University Hospital Zurich, Zurich, Switzerland (*E-mail: alessandra.curioni@usz.ch)

disclosure

The authors have declared no conflicts of interest.

references

1. Grothey A, Van Cutsem E, Sobrero A et al. Regorafenib monotherapy for previously treated metastatic colorectal cancer (CORRECT): an international, multicentre, randomised, placebo-controlled, phase 3 trial. *Lancet* 2013; 381: 303–312.
2. Tsonalis GJ, Peterson JD, de Abreu FB et al. Routine use of the Ion Torrent AmpliSeq™ Cancer Hotspot Panel for identification of clinically actionable somatic mutations. *Clin Chem Lab Med* 2014; 52: 707–714.
3. Boland JF, Chung CC, Roberson D et al. The new sequencer on the block: comparison of Life Technology's Proton sequencer to an Illumina HiSeq for whole-exome sequencing. *Hum Genet* 2013; 132: 1153–1163.
4. Hoch RV, Soriano P. Roles of PDGF in animal development. *Development* 2003; 130: 4769–4784.
5. Yu J, Ustach C, Kim HR. Platelet-derived growth factor signaling and human cancer. *J Biochem Mol Biol* 2003; 36: 49–59.
6. Guida T, Anaganti S, Provitera L et al. Sorafenib inhibits imatinib-resistant KIT and platelet-derived growth factor receptor beta gatekeeper mutants. *Clin Cancer Res* 2007; 13: 3363–3369.
7. Estevez-Garcia P, Castano A, Martin AC et al. PDGFRalpha/beta and VEGFR2 polymorphisms in colorectal cancer: incidence and implications in clinical outcome. *BMC Cancer* 2012; 12: 514.
8. Martoglio B, Dobberstein B. Signal sequences: more than just greasy peptides. *Trends Cell Biol* 1998; 8: 410–415.

doi: 10.1093/annonc/mdu471

Published online 20 October 2014

Pharmacokinetic interaction involving fenofibrate and everolimus

We have read with great attention the recent review by Aapro et al. [1] on the management of adverse events in cancer patients receiving everolimus. Although we agree with the authors that high levels of triglycerids increase the risk of pancreatitis, we question the opportunity of using fibrates in this setting, in view of the following observation.

A 57-year-old patient with a past history of hypertension and smoking (25 pack-years) underwent lumpectomy and axillary dissection (1N+/13) for a 28-mm, grade II, hormone receptor-positive, HER2-negative, invasive ductal breast carcinoma in 2007. She subsequently received adjuvant chemotherapy (5-fluorouracil, epirubicin and cyclophosphamide for three cycles followed by three cycles of docetaxel), radiotherapy, then anastrozole for 5 years. Seventeen months after the end of anastrozole, metastatic bone disease was diagnosed. She was prescribed exemestane 25 mg and everolimus 10 mg daily [2]. At this time, her liver function tests, cholesterolemia and triglyceridemia were normal. Her co-medications were zoledronic acid, bromazepam and losartan.

The combination of exemestane and everolimus was well tolerated, with grade 2 stomatitis being the worse toxicity. After 1 month of treatment, she developed grade 1 hypercholesterolemia (280 mg/dl) and grade 2 hypertriglyceridemia (480 mg/dl), and was therefore started on fenofibrate 160 mg/day by her treating physician. Everolimus trough plasma concentration was 10.1 ng/ml (within the range described in the phase I trial at this dosage [3]) before introduction of fenofibrate. Two weeks later, stomatitis had regressed, but everolimus trough concentration