

LETTER TO THE EDITOR

'The anatomy underlying acute versus chronic spatial neglect' also depends on clinical tests

Arnaud Saj,^{1,2} Vincent Verdon,³ Roland Vocat⁴ and Patrik Vuilleumier^{1,2}

1 Department of Neurology, University Hospital of Geneva, Geneva, Switzerland

2 Department of Neurosciences, Medical School, University of Geneva, Geneva, Switzerland

3 Department of Medicine, Neuropsychology Unit, Hospital of Neuchâtel, Neuchâtel, Switzerland

4 Health Network Valais, St-Maurice, Martigny and Sierre, Switzerland

Correspondence to: Dr Arnaud Saj,
Department of Neurology,
University Hospital of Geneva,
Rue Gabrielle-Perret-Gentil 4,
CH-1211 GENEVA 14,
Switzerland
E-mail: arnaud.saj@unige.ch

Sir,

We would like to make a few comments on the interesting paper recently published in *Brain* by Karnath *et al.* (2011). We were impressed by the careful assessment of spatial neglect during acute and chronic phase, which was combined with a solid voxel-wise lesion symptom mapping technique in a series of 54 patients with right-hemisphere stroke. Anatomical data indicated that lesions in the superior and middle temporal gyri, the basal ganglia, as well as the inferior occipitofrontal fasciculus are responsible for spatial neglect in both acute and chronic phases.

We also had the opportunity to evaluate 69 patients with right brain lesions longitudinally. Our patients were admitted after a first right-hemisphere stroke (mean delay: 7.5 ± 14.6 days), at a mean age of 64.95 ± 14.6 years. Mean delay between the acute and chronic phase was 350.21 ± 184.7 days. These demographic data are comparable with the patients of Karnath *et al.* (2011). Neglect was considered as present when patients failed at least two out of eight tests (Table 1)—unlike diagnoses based on two out three tests in Karnath *et al.* (2011). In the acute phase, 31 patients had neglect (45%). In the chronic phase, 17 of these 31 neglect patients still showed a significant impairment (55%). Using the same voxel-wise lesion mapping as Karnath *et al.* (2011), we found partly different results, particularly in the acute phase (detailed below). However, we believe that major differences in the findings may depend on the clinical measures used to define neglect, since this syndrome may include heterogeneous symptoms.

Bowen *et al.* (1999) reported that the frequency of occurrence of neglect in patients with right brain damage may vary considerably and range from 13% to 82%, due to variations in the assessment method used in different studies. In clinical practice, neglect is typically assessed by a battery of tasks rather than by a single test, reflecting the underlying heterogeneity of deficits. Indeed, patients with normal performance on certain tests may show clinically significant neglect in others (Buxbaum *et al.*, 2004). Furthermore, the most commonly used tests in neuropsychological studies of spatial neglect do not take into account associated disorders, such as personal neglect, representational neglect or motor neglect (Azouvi *et al.*, 2006; Verdon *et al.*, 2010).

To clarify the source of lesion mapping differences across studies and determine the role of different methods for assessing spatial neglect after right hemisphere stroke, in both the acute and chronic phases, we conducted a series of analyses replicating and extending the work of Karnath *et al.* (2011). First, we used similar tests as these authors, consisting of two cancellation tasks with a visuomotor exploratory component (bells, Gauthier *et al.*, 1989; and letters, Mesulam, 1999) and one drawing task with visuoconstructive and object-centred components (scene copy, Gainotti and Tiacci, 1970). Then, we performed another analysis based on a more complete battery of neglect tests (Azouvi *et al.*, 2006), which is commonly used in the clinic and includes several paper-and-pencil tests that were adapted from the neuropsychology literature: line bisection (5, 20 cm), bell cancellation, letter cancellation, scene copy, clock drawing, text reading and writing (last name, first name

and address). All of these tests assess different spatial components that may be disrupted differentially in patients with neglect and have partly distinct anatomical substrates (Verdon *et al.*, 2010). The location and extent of brain damage was delineated in each patient, based on their native 3D MRI scan, and then reconstructed on a standardized brain template with the MRIcro software (Rorden and Brett, 2000), as described elsewhere (Verdon *et al.*, 2010; Vocat *et al.*, 2011). The obtained lesions (regions of interest) were then submitted to voxel-based lesion symptom mapping (Bates *et al.*, 2003; Baldo *et al.*, 2006; Verdon *et al.*, 2010; Karnath *et al.*, 2011; Vocat *et al.*, 2011) in order to determine the critical brain regions implicated in spatial neglect and its underlying components. To this aim, we first performed voxel-wise lesion symptom mapping analysis using a composite score of neglect severity based on a combination of measures (averaged z-scores of total omissions for cancellation tests (bell and letter test) and performance of scene copy from either the three tests of Karnath *et al.* (2011) or from all eight tests of our battery, for both the acute and the chronic phases. We also calculated a 'centre of cancellation' score for the cancellation tests (Karnath *et al.*, 2011), but results were identical when using this measure as it was highly correlated ($r > 0.91$) with the number of left omissions.

Neuropsychology test results are described in Table 1. Figure 1A illustrates the voxel-wise lesion symptom mapping results for the assessment with three tests (composite global score) in the acute phase. The largest areas of lesions affected the superior and inferior parietal gyri, the posterior portion of the superior and middle temporal gyri, as well as the lateral and medial occipital cortex, the frontal operculum and to a lesser degree, the posterior middle frontal gyrus (nearby the frontal eye field). At the subcortical level, lesions also affected the thalamus and anterior basal ganglia. For neglect in the chronic phase, lesions affected partly similar regions but predominantly in the posterior middle temporal gyrus and the inferior parietal lobe, whereas the correlation with occipital damage was reduced.

Figure 1B also shows lesions implicated when the analysis was based on the overall battery of eight tests (global composite score) in the acute phase. The lesion peaks now impacted much more

prominently on the posterior middle temporal gyri, but with an extension to the depth of the temporoparietal junction and paraventricular white matter in the superior parietal lobe, plus to the lateral occipital cortex, and more anterior regions in the depth of the middle and superior frontal gyrus. The insula and subcortical regions in the basal ganglia (putamen, pallidum, caudate) and thalamus were also affected, together with medial and subcortical portions of the temporal lobe in the parahippocampal and amygdalo-hippocampic regions. For neglect in the chronic phase, regions where injury predicted deficits were the temporoparietal junction (mostly extending subcortically in white matter) and the middle temporal gyrus.

These data are therefore partly similar to those found by Karnath *et al.* (2011), in particular for the right middle temporal gyrus; in fact their anatomical results for this region in the acute phase exhibit a striking degree of resemblance with our own data (compare their Fig. 2A with our Fig. 1B). However, in contrast to their findings, we observed a marked involvement of the parietal lobe (particularly superior areas) and of the occipital lobe when neglect diagnosis was based on three tests only. As the latter assessment included two cancellation tasks and one copying task, these anatomical correlates converge with previous studies (Mort *et al.*, 2003) that found lesions in right parietal cortex to be associated with both perceptive and visuomotor spatial symptoms of neglect. These results also accord with functional neuroimaging data in healthy adults showing that activity in both occipital and parietal cortex contribute to efficient visual search performance (Nobre *et al.*, 2003; Mavritsaki *et al.*, 2010). We also found a significant involvement of occipital areas in the acute stage, which is more commonly reported in functional imaging studies of neglect than structural mapping studies (Vuilleumier *et al.*, 2008; Khurshid *et al.*, 2011; Umarova *et al.*, 2011) but seems consistent with a role of occipital cortex and occipital white matter in visual neglect symptoms (Bird *et al.*, 2006; Saj *et al.*, 2010; Vossel *et al.*, 2011). It is unclear why we found different anatomical correlates (in superior parietal and occipital rather than temporal areas) when using three tests similar to those of Karnath *et al.* (2011), but this discrepancy may reflect the existence of

Table 1 Neuropsychological results on paper and pencil tests. All scores were calculated as described in Verdon *et al.* (2010)

	Acute phase			Chronic phase		
	Neglect group		No neglect group	Neglect group		No neglect group
	Acute	Chronic		Acute	Chronic	
Bell cancellation (total omission)	15.7 (9.5)	23.2 (6.6)	2.4 (2.2)	3.3 (2.0)	10.5 (5.5)	1.2 (2.2)
Bell cancellation (centre of cancellation)	0.24 (0.36)	0.52 (0.25)	0.04 (0.08)	−0.01 (0.08)	0.25 (0.17)	−0.02 (0.08)
Letter cancellation (left omission)	12.9 (11.1)	23.5 (7.7)	2.0 (3.3)	1.5 (2.4)	10.4 (6.7)	0.6 (1.4)
Letter cancellation (centre of cancellation)	0.16 (0.43)	0.46 (0.33)	−0.07 (0.09)	0.09 (0.7)	0.21 (0.10)	0.01 (0.05)
Copy of scene (omission)	1.1 (1.2)	2.1 (1.2)	0 (0.4)	0.1 (0.3)	1.3 (0.8)	0 (0.2)
Line bisection (total deviation cm, line 5 cm)	2.4 (1.9)	3.0 (1.5)	1.6 (1.3)	1.0 (0.8)	2.1 (1.3)	1.1 (1.2)
Line bisection (total deviation cm, line 20 cm)	5.2 (3.5)	7.6 (4.4)	3.9 (2.8)	3.6 (3.4)	6.1 (3.2)	3.0 (2.4)
Clock drawing (omission)	1.1 (0.9)	4.2 (5.4)	0.1 (0.3)	0 (0.2)	1.2 (0.9)	0 (0.1)
Text reading (total omission)	1.5 (1.9)	1.9 (1.7)	0 (0.2)	0 (0.3)	1.8 (2.4)	0 (0)
Writing (left margin, cm)	11.3 (6.3)	10.7 (4.5)	4.5 (2.8)	4.9 (3.4)	9.3 (5.3)	3.5 (1.9)

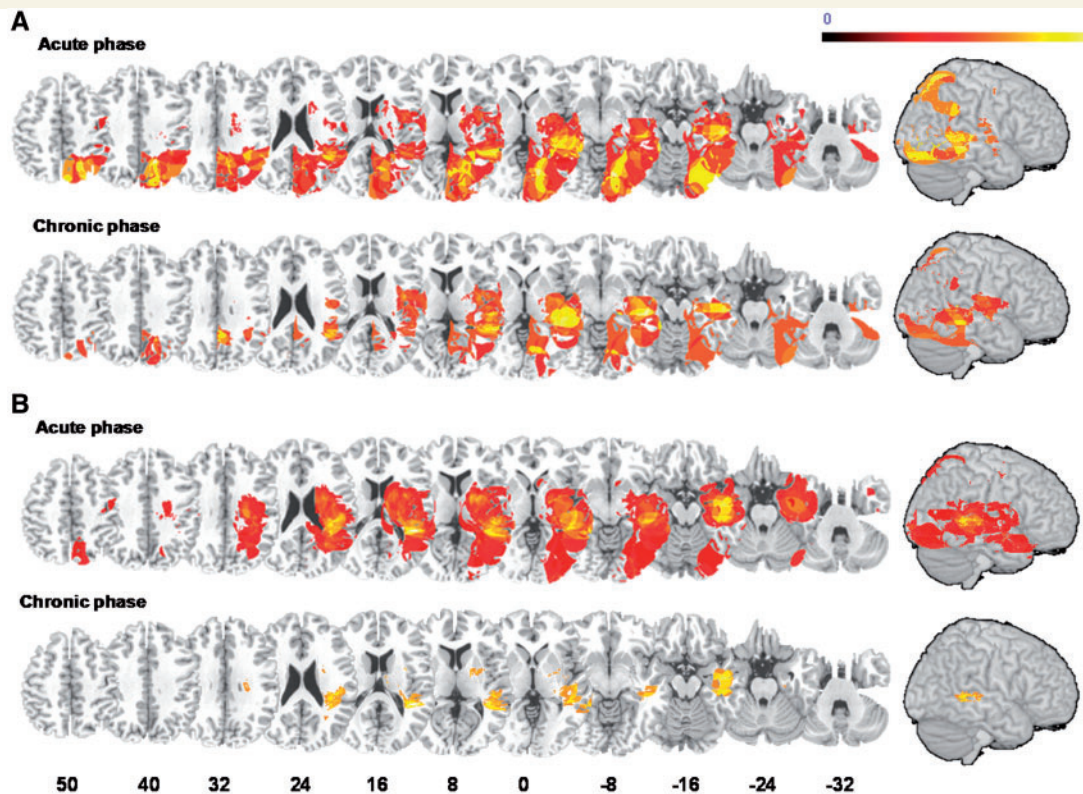


Figure 1 Voxel-based symptom lesion mapping of neglect severity using the t -test statistic. Voxel-wise lesion symptom maps show all voxels surviving a 1% false discovery rate cut-off threshold. Data from all patients were used and yielded a composite neglect score measured in the acute and chronic phase (A) with three tests (bell cancellation, letter cancellation and scene copy), or (B) with a standard battery of eight tests (GEREN). Note that the extent of subcortical damage is not reflected on the cortical surface rendering and lesions in white matter are particularly associated with neglect in the chronic stage.

concomitant deficits in other tests in our patients. Moreover, the drawing task was different in the two studies, with spatially more distant items in ours, which might partly explain a greater correlation with parietal damage. The additional foci observed with three (but not eight) tests are likely to reflect a greater contribution of these regions to performance on these particular tasks, which was not shared with the other five and hence 'diluted' when pooling all tests together.

On the other hand, our data add novel support to an important role of the right temporal cortex in spatial awareness (Karnath, 2001; Luauté *et al.*, 2009), particularly when using a composite measure of neglect derived from different tests. Interestingly, this region was found to correlate with spatial neglect when assessed by a combination of tests including not only cancellation tasks but also manual search and drawing (Karnath *et al.*, 2001), somewhat similar to the 'total' composite score derived from eight tests in our analysis. However, it is intriguing that the acute lesion pattern in temporal lobe obtained with eight tests in our patients most resembled that obtained with three tests in the study of Karnath *et al.* (2011; Fig. 2A) (Fig. 1B). This 'paradoxical' resemblance suggests that temporal regions could actually reflect the most common shared areas of damage (i.e. lowest common denominator) in patients who present with neglect symptoms in several disparate tests. However, such mapping of neglect severity across various tests remains limited by the fact that a similar total score

can be obtained in patients who fail on different tasks. Other recent studies suggested that temporal damage may preferentially be associated with allocentric/object-based components of neglect (Medina *et al.*, 2009; Verdon *et al.*, 2010), a disorder that could contribute to impaired performance on several of our eight tests (e.g. drawing, reading and line bisection).

The importance and originality of the study of Karnath *et al.* (2011) is to highlight the crucial role of cortical and subcortical structures whose lesion may lead to persistent spatial neglect disorder in chronic stage. Their findings also highlight a role for white matter damage to the uncinate fasciculus in the emergence of chronic neglect, whereas our own results (with eight tests) additionally point to a role of subcortical damage around the temporoparietal junction and superior longitudinal fasciculus (Fig. 1B) in accord with other results (Samuelsson *et al.*, 1997; Doricchi *et al.*, 2003; Bartolomeo *et al.*, 2007). However, a major problem for conclusions related to the mechanisms of neglect and underlying anatomical correlates is that their investigation is often limited by the lack of specific tests measuring clearly distinct cognitive components of neglect (Verdon *et al.*, 2010). Because it is recognized that a combination of different tasks (e.g. line bisection, cancellation test and copy of scene) is necessary to detect spatial neglect and its different manifestations (Jehkonen *et al.*, 1998), it is clinically useful to use batteries with several tests to guarantee a reliable sensitivity of the diagnosis (Azouvi *et al.*, 2006).

Table 2 Factorial analysis of neglect performance across all tests

	Acute phase					Chronic phase			
	Factor 1	Factor 2	Factor 3	Factor 4	Factor 5	Factor 1	Factor 2	Factor 3	Factor 4
Variance explained (%)	26.43	18.39	17.25	10.75	7.69	34.23	10.09	19.24	11.25
Eigenvalues	4.229	2.942	2.760	1.720	1.230	6.278	1.625	3.501	1.798
Line bisection									
Line 5 cm				0.68					0.69
Line 20 cm				0.79				0.57	
Bell cancellation									
Left omission	0.65					0.88			
Left–right omission		0.82					0.89		
Time					0.95				0.80
Letter cancellation									
Left omission	0.66					0.89			
Left–right omission		0.89					0.79		
Drawing									
Scene copy			0.80			0.62			
Clock drawing	0.68					0.66			
Text reading									
Left omission			0.78					0.75	
Right omission			0.83					0.91	
Writing									
Left margin (cm)	0.53					0.63			

Each factor is shown with the corresponding amount of variance explained, eigenvalues, and factor loadings for the different test scores (when >0.5).

However, pooling heterogeneous deficits into a single entity might hamper our understanding of the exact cognitive mechanisms and neural circuits involved.

Accordingly, neglect has long been thought to implicate widely distributed brain networks (Mesulam, 1999; Corbetta *et al.*, 2005; Vuilleumier, 2007), encompassing both cortical and subcortical regions as well as white-matter connections between them (Thiebaut de Schotten *et al.*, 2008). The specific functions of each node within this large-scale network still remain to be elucidated. Recent work by our group (Verdon *et al.*, 2010) has attempted to identify distinct spatial components contributing to neglect symptoms in different tests, and suggested that these components may have different neural substrates in parietal, frontal and temporal lobes, related to the egocentric perceptual, exploratory and allocentric object-based deficits, respectively. These results were replicated in the current data set (with different patients) when we applied the same methodology (Verdon *et al.*, 2010) and performed a factorial analysis of 12 behavioural measures derived from our eight tests battery. Furthermore, the components were highly similar for the acute and chronic phases, despite significant changes in neglect severity in several tests battery. Acutely, performance across tests was accounted by five main factors (80.5% of explained variance) that predominantly regrouped (i) contralesional omissions in cancellation tasks plus neglect on clock drawing and writing; (ii) left–right difference in cancellation tasks; (iii) omissions in scene copy and text reading; (iv) short and long line bisection; and (v) temporal slowing on cancellation tasks (in decreasing order of importance, see Table 2 for all factors). Likewise, in the chronic phase, performance was accounted by four factors (74.8% of explained variance) that regrouped (i) contralesional omissions in cancellation, writing and

all drawing tasks; (ii) left–right difference in cancellation tasks; (iii) deviation on line bisection and reading errors; and (iv) deviation on line bisection and temporal slowing (in decreasing importance). These results are remarkably similar for the two phases and agree with our previous findings (Verdon *et al.*, 2010). The very existence of these different factors underscores that neglect behaviour is not unitary, and that different dimensions are shared by some but not all tests. Therefore, rather than mapping the anatomy of different neglect syndromes (e.g. allocentric vs egocentric) or different tests (e.g. line bisection vs cancellation), it seems necessary to better identify component processes which can mediate distinct spatial computations, relying on distinct neural substrates, and potentially contribute to one or more of these clinical manifestations.

In summary, mapping lesions associated with acute and chronic neglect shows both resemblance and divergence between our data and the study of Karnath *et al.* (2011). Other discrepancies have also been noted in previous anatomical studies of neglect (Doricchi and Tomaiuolo, 2003; Mort *et al.*, 2003). The observed differences are likely to reflect the fact that using a small subset of tests (as in Karnath *et al.*, 2011) might overlook the impact of other concomitant deficits, and that relying on a single measure of neglect severity might fail to account for the existence of distinct components underlying neglect behaviour, which can make different contributions (in additive or interactive manner) to allocentric deficits versus egocentric deficits, or perceptual deficits versus exploratory deficits (Committeri *et al.*, 2007; Medina *et al.*, 2009; Verdon *et al.*, 2010). Thus, averaging different kinds of neglect symptoms together into one single measure could potentially highlight the most frequent but least specific sites of damage, as found for the temporal lobe when pooling all different tests used in our

study. Future research investigating the neural substrates of spatial neglect syndrome after brain lesions should pay close attention to the tests employed and the cognitive functions recruited in order to better understand the role of different neural components, and therefore use a comprehensive battery assessing several distinct domains of spatial cognition whenever possible. By doing so, apparent discrepancies between studies might be easier to resolve and efficient rehabilitation approaches targeting specific components more readily designed.

Acknowledgements

The authors report no conflict of interest. All authors have full access to all the data in the study and take responsibility for the integrity of the data and the accuracy of the data analysis. We are grateful to H.O. Karnath and C. Rorden for constructive discussion and help during our own data analyses.

Funding

Swiss National Foundation (#3200B0-114014) and the Geneva Academic Society (Fund Foremane).

References

- Azouvi P, Bartolomeo P, Beis JM, Perennou D, Pradat-Diehl P, Rousseaux M. A battery of tests for the quantitative assessment of unilateral neglect. *Restor Neurol Neurosci* 2006; 24: 273–85.
- Baldo JV, Schwartz S, Wilkins D, Dronkers NF. Role of frontal versus temporal cortex in verbal fluency as revealed by voxel-based lesion symptom mapping. *J Int Neuropsychol Soc* 2006; 12: 896–900.
- Bartolomeo P, Thiebaut de Schotten M, Doricchi F. Left unilateral neglect as a disconnection syndrome. *Cereb Cortex* 2007; 17: 2479–90.
- Bates E, Wilson SM, Saygin AP, Dick F, Sereno MI, Knight RT, et al. Voxel-based lesion-symptom mapping. *Nat Neurosci* 2003; 6: 448–50.
- Bird CM, Malhotra P, Parton A, Coulthard E, Rushworth MF, Husain M. Visual neglect after right posterior cerebral artery infarction. *J Neurol Neurosurg Psychiatry* 2006; 77: 1008–12.
- Bowen A, McKenna K, Tallis RC. Reasons for variability in the reported rate of occurrence of unilateral spatial neglect after stroke. *Stroke* 1999; 30: 1196–202.
- Buxbaum LJ, Ferraro MK, Veramonti T, Farne A, Whyte J, Ladavas E, et al. Hemispatial neglect: Subtypes, neuroanatomy, and disability. *Neurology* 2004; 62: 749–56.
- Committeri G, Pitzalis S, Galati G, Patria F, Pelle G, Sabatini U, et al. Neural bases of personal and extrapersonal neglect in humans. *Brain* 2007; 130: 431–41.
- Corbetta M, Kincade MJ, Lewis C, Snyder AZ, Sapir A. Neural basis and recovery of spatial attention deficits in spatial neglect. *Nat Neurosci* 2005; 8: 1603–10.
- Doricchi F, Tomaiuolo F. The anatomy of neglect without hemianopia: a key role for parietal-frontal disconnection? *Neuroreport* 2003; 14: 2239–43.
- Gainotti G, Tiacci C. Patterns of drawing disability in right and left hemispheric patients. *Neuropsychologia* 1970; 8: 379–84.
- Gauthier L, Dehaut F, Joannette Y. The bells test: a quantitative and qualitative test for visual neglect. *Int J Clin Neuropsychol* 1989; 11: 49–53.
- Jehkonen M, Ahonen JP, Dastidar P, Koivisto AM, Laippala P, Vilkkii J. How to detect visual neglect in acute stroke. *Lancet* 1998; 351: 727–8.
- Karnath HO. New insights into the functions of the superior temporal cortex. *Nat Rev Neurosci* 2001; 2: 568–76.
- Karnath HO, Ferber S, Himmelbach M. Spatial awareness is a function of the temporal not the posterior parietal lobe. *Nature* 2001; 411: 950–3.
- Karnath HO, RENNIG J, Johannsen L, Rorden C. The anatomy underlying acute versus chronic spatial neglect: a longitudinal study. *Brain* 2011; 134: 903–12.
- Khurshid S, Trupe LA, Newhart M, Davis C, Molitoris JJ, Medina J, et al. Reperfusion of specific cortical areas is associated with improvement in distinct forms of hemispatial neglect. *Cortex* 2011. Published online.
- Luaute J, Schwartz S, Rossetti Y, Spiridon M, Rode G, Boisson D, et al. Dynamic changes in brain activity during prism adaptation. *J Neurosci* 2009; 29: 169–78.
- Mavritsaki E, Allen HA, Humphreys GW. Decomposing the neural mechanisms of visual search through model-based analysis of fMRI: top-down excitation, active ignoring and the use of saliency by the right TPJ. *Neuroimage* 2010; 52: 934–46.
- Medina J, Kannan V, Pawlak MA, Kleinman JT, Newhart M, Davis C, et al. Neural substrates of visuospatial processing in distinct reference frames: evidence from unilateral spatial neglect. *J Cogn Neurosci* 2009; 21: 2073–84.
- Mesulam MM. Spatial attention and neglect: parietal, frontal, and cingulate contributions to the mental representation and attentional targeting of salient extrapersonal events. *Philos Trans R Soc Lond B Biol Sci* 1999; 354: 1325–46.
- Mesulam MM. Spatial attention and neglect: parietal, frontal and cingulate contributions to the mental representation and attentional targeting of salient extrapersonal events. *Philos Trans R Soc Lond B Biol Sci* 1999; 354: 1325–46.
- Mort DJ, Malhotra P, Mannan SK, Rorden C, Pambakian A, Kennard C, et al. The anatomy of visual neglect. *Brain* 2003; 126: 1986–97.
- Nobre AC, Coull JT, Walsh V, Frith CD. Brain activations during visual search: contributions of search efficiency versus feature binding. *Neuroimage* 2003; 18: 91–103.
- Rorden C, Brett M. Stereotaxic display of brain lesions. *Behav Neurol* 2000; 12: 191–200.
- Saj A, Honore J, Richard C, Bernati T, Rousseaux M. Hemianopia and neglect influence on straight-ahead perception. *Eur Neurol* 2010; 64: 297–303.
- Samuelsson H, Jensen C, Ekholm S, Naver H, Blomstrand C. Anatomical and neurological correlates of acute and chronic visuospatial neglect following right hemisphere stroke. *Cortex* 1997; 33: 271–85.
- Thiebaut de Schotten M, Kinkingnehun S, Delmaire C, Lehericy S, Duffau H, Thivard L, et al. Visualization of disconnection syndromes in humans. *Cortex* 2008; 44: 1097–103.
- Umarova RM, Saur D, Kaller CP, Vry MS, Glauche V, Mader I, et al. Acute visual neglect and extinction: distinct functional state of the visuospatial attention system. *Brain* 2011. in press.
- Verdon V, Schwartz S, Lovblad KO, Hauert CA, Vuilleumier P. Neuroanatomy of hemispatial neglect and its functional components: a study using voxel-based lesion-symptom mapping. *Brain* 2010; 133: 880–94.
- Vocat R, Staub F, Stroppini T, Vuilleumier P. Anosognosia for hemiplegia: a clinical-anatomical prospective study. *Brain* 2011; 133: 3578–97.
- Vossel S, Eschenbeck P, Weiss PH, Weidner R, Saliger J, Karbe H, et al. Visual extinction in relation to visuospatial neglect after right-hemispheric stroke: quantitative assessment and statistical lesion-symptom mapping. *J Neurol Neurosurg Psychiatry* 2011; 82: 862–8.
- Vuilleumier P. Hemispatial neglect. In: Godefroy O, Bogousslavsky J, editors. *The behavioral and cognitive neurology of stroke*. Cambridge: MIT Press; 2007. p. 148–97.
- Vuilleumier P, Schwartz S, Verdon V, Maravita A, Hutton C, Husain M, et al. Abnormal attentional modulation of retinotopic cortex in parietal patients with spatial neglect. *Curr Biol* 2008; 18: 1525–9.