

Pulmonary malignant peripheral nerve sheath tumour

Ilhan Inci^{a,*}, Alex Soltermann^b, Didier Schneider^a and Walter Weder^a

^a Department of Thoracic Surgery, University Hospital, Zurich, Switzerland

^b Department of Pathology, University Hospital, Zurich, Switzerland

* Corresponding author. Department of Thoracic Surgery, University Hospital, University of Zurich, Raemistrasse 100, 8091 Zurich, Switzerland.
Tel: +41-44-42558802; fax: +41-44-2558805; e-mail: ilhan.inci@usz.ch (I. Inci).

Received 2 September 2013; received in revised form 12 October 2013; accepted 21 October 2013

Abstract

Malignant peripheral nerve sheath tumours (MPNSTs) may occur in any peripheral nerve. They are often found in the chest wall and the posterior mediastinum. On the other hand, primary pulmonary MPNST is extremely rare, and surgically treated cases have been reported. Here, we present 3 cases of primary MPNST originating from the pulmonary parenchyma who underwent surgery in our institution. We discuss the possible clinical and pathological associations in the view of the literature.

Keywords: Lung • Malignant peripheral nerve sheath tumours • Nerve sheath tumour • Malignant schwannoma • Surgery

INTRODUCTION

Malignant peripheral nerve sheath tumours (MPNSTs) are rare soft-tissue sarcomas that develop within the peripheral nerve and are often found in the chest wall and the posterior mediastinum. However, primary pulmonary MPNST is extremely rare with only scattered case reports in the English literature [1, 2]. In this report, we present 3 patients with primary pulmonary MPNST.

CASE REPORTS

Patient 1

A 42-year old woman with a 27 pack-year smoking history was admitted to our clinic with a 3-month history of mild dyspnoea. Chest X-ray and computed tomography (CT) of the thorax revealed a mass measuring 90 × 64 mm in the posterior segment of the right upper lobe. Bronchoscopy was not diagnostic. CT-guided fine-needle biopsy was not diagnostic. Her forced expiratory volume in one second (FEV₁) was 1.6 l (58%). We performed a right upper lobectomy and mediastinal lymph node dissection. The patient recovered uneventfully and did not receive any adjuvant chemoradiotherapy. Microscopic examination revealed a highly vascularized spindle cell tumour, prominent pleomorphism with giant cells and atypical mitosis. Immunohistochemistry was positive staining for S-100 (focal), vimentin and desmin (Fig. 1), but was negative for smooth muscle actin, CD34, BCL-2, EMA, CDK4 and myogenin. The proliferation index of the tumour cells MIB-1 (Ki-67) was 80%. The pathological diagnosis was MPNST. Twenty-five months following the operation, she developed a second tumour in the lingula portion of the left upper lobe. She underwent video-assisted thoracoscopic surgery with wide resection of the lingula due to her limited lung function. The diagnosis revealed adenocarcinoma of the lung. She is alive and tumour free with a follow-up of 55 months.

Patient 2

A 66-year old heavy smoker (38 pack-year) male patient was admitted to our clinic with a 3-week history of dyspnoea. Chest X-ray and thorax CT revealed a huge mass measuring 270 × 220 mm in the right upper lobe (Fig. 2). Positron emission tomography (PET) scan revealed a low standard uptake unit suggestive of a sarcoma or a pleura tumour. Second CT-guided fine-needle biopsy demonstrated spindle cell malignant neoplasm. His FEV₁ was 1.75 l (60%). He underwent extrapleural right pneumonectomy via right hemi-clamshell incision. In the pathology report, the bronchus and vascular structures (pulmonary artery and pulmonary veins) were not invaded with the tumour. The pathological report revealed primary MPNST. The next day following the operation, he transferred to the ward. On the ward, he developed postoperative delirium. Due to infiltration on the left lung and increasing respiratory problems, he transferred to the intensive care unit (ICU). He also developed a fungal pneumonia. He was intubated on the postoperative second day in the ICU and received nitric oxide inhalation as well as Nova-Lung[®] due to unresponsive hypercapnia. The patient died on the 22nd postoperative day.

Patient 3

A 67-year old ex-smoker (8 pack-year) male who had dizziness, neck pain, nausea and vomiting underwent brain magnetic resonance imaging (MRI) to rule out intracranial pathology. Brain MRI showed a mass in cerebellum with compression of the fourth ventricle with hydrocephalus. He underwent craniotomy with the removal of the tumour. The pathological diagnosis of the tumour was malignant high-grade pleomorphic and spindle cell tumour with neurogenic differentiation. Immunohistochemistry was focally positive for protein S-100, but negative for smooth muscle actin and desmin. The proliferation rate MIB-1 was 60%.

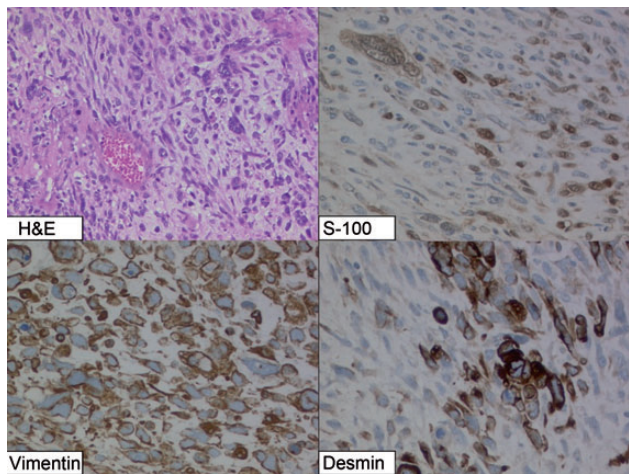


Figure 1: Highly vascularized spindle cell tumour, prominent pleomorphism with giant cells and atypical mitosis. Immunoreactivity for protein S-100 (focal), vimentin and desmin. Original magnifications $\times 100\times$ hematoxylin and eosin stain and $\times 200$ (immunohistochemistry)

After craniotomy, he received cranial radiotherapy (25 Gy). PET scan showed a lesion in the lingula portion of the left upper lobe. He had an FEV₁ of 4.56 l (135%). He underwent video-assisted thoracoscopic surgery left upper lobectomy with mediastinal lymphadenectomy. The lung tumour showed the same morphology as the cerebellum mass, favouring brain metastasis of a lung primary. Immunohistochemistry showed strong S100 positive expression and, focal expression of CKAE1 and CKAE3 (pan CKB). The tumour cells were negative for melanoma markers HMB45, pan-Melan, Melan A and tyrosinase as well as CD34, CD99, Synaptophysin and TTF1. Reverse transcription polymerase chain reaction detected not (12;22) translocation (EWSR1-ATF1 fusion), ruling out clear cell sarcoma. Based on these findings, a diagnosis of MPNST was made. He is alive without any signs of recurrent disease with a follow-up of 4 months.

DISCUSSION

Schwannomas can occur in any region of the thoracic cavity, but are most frequently found in the posterior mediastinum and costo vertebral angle and are almost always associated with neurofibromatosis [2]. In the literature, rare cases with malignant transformation of benign peripheral nerve sheath tumour were reported. However, primary pulmonary schwannomas without associated neurofibromatosis can occur and are predominantly benign with minimal tendency to recur [3]. Primary pulmonary MPNST is uncommon and only 12 surgical case reports of this tumour are available and those patients were treated with pneumonectomy, lobectomy or enucleation [4]. We performed a right upper lobectomy in the first case, a right pneumonectomy in the second case and a left upper lobectomy in the third case in order to achieve a complete resection.

Most peripheral MPNSTs are highly invasive and are associated with a low survival rate; however, aggressive surgery significantly improves disease-free survival [4]. We found no invasion to the thoracic wall in our cases. The first case was free of recurrence 25 months after the operation, and then she developed a second primary lung carcinoma. Currently, after 55 months of follow-up she is alive without any sign of recurrent disease. The second case

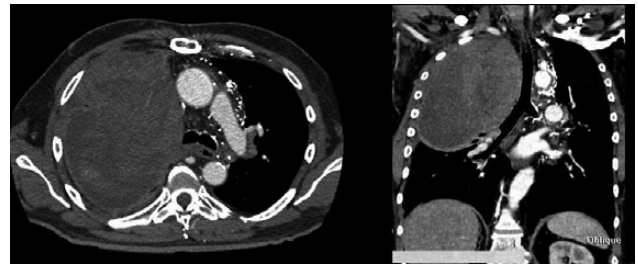


Figure 2: The axial and coronal CT scans of the second case

died on the ICU due to acute respiratory distress following a right pneumonectomy. The third case is alive without recurrence and is under our follow-up. The radiographic feature of the tumour is a round, ovoid or lobulated homogenous mass with sharp borders. When the tumour is located proximal to the large bronchus, atelectasis of the lung may be the only radiological sign and the symptoms are presented as pneumonia cough and dyspnoea [3, 4]. In our cases, there was a big round mass in the right and left upper lobes.

Primary intrapulmonary neurogenic tumours may be divided histologically into neurofibroma and neurilemmoma; neurogenic sarcoma and malignant schwannoma are the malignant equivalents. In general, immunohistochemical staining detects S-100 protein in all schwannomas, but may be absent in malignant nerve sheath tumour [4]. The utility of Ki-67, a tumour cell proliferation marker, has been reported in determining malignant potential. It has been shown that, in malignant nerve sheath tumours, 5–65% of the tumour cell nuclei were immunoreactive for Ki-67, whereas none of the schwannomas had nuclear staining exceeding 5% [1, 4]. In the first case, an immunohistochemical study revealed focal positivity for S-100 protein and proliferation index of the tumour cells was 80%.

The use of neoadjuvant chemoradiotherapy followed by pneumonectomy with a long-term survival has been advocated [5]. These authors have concluded that the use of neoadjuvant chemoradiotherapy to treat primary pulmonary sarcomas has potential benefits over postoperative therapy or neoadjuvant radiation therapy alone [5].

In conclusion, primary MPNSTs of the lungs are extremely rare tumours and they are suitable for primary surgical resection. Complete surgical resection provides both definitive diagnosis and therapeutic option in these unique rare tumours.

Conflict of interest: none declared.

REFERENCES

- [1] Togashi K, Hirahara H, Sugawara M, Oguma F. Primary malignant schwannoma of the lung. *Jpn J Thorac Cardiovasc Surg* 2003;51:692–5.
- [2] La Mantia E, Franco R, Cantile M, Rocco R, De Chiara A, Martucci N et al. Primary intrapulmonary malignant peripheral nerve sheath tumor mimicking lung cancer. *J Thorac Dis* 2013;5:E155–7.
- [3] Woo OH, Yong HS, Shin BK, Oh YW, Kim HK, Kang EY. Wide spectrum of thoracic neurogenic tumours: a pictorial review of CT and pathological findings. *Br J Radiol* 2008;81:668–76.
- [4] Uchiyama M, Shimoyama Y, Usami N, Ito S, Yasuda A, Kawaguchi K et al. Primary pulmonary malignant schwannoma with extension to the tracheal carina. *J Thorac Cardiovasc Surg* 2007;133:265–7.
- [5] Cuneo KC, Riedel RF, Dodd LG, Harpole DH Jr, Kirsch DG. Pathologic complete response of a malignant peripheral nerve sheath tumor in the lung treated with neoadjuvant ifosfamide and radiation therapy. *J Clin Oncol* 2012;30:e291–3.