

Tumor Necrosis Factor- α Contributes to Apoptosis in Hippocampal Neurons during Experimental Group B Streptococcal Meningitis

Inja Bogdan,* Stephen L. Leib,* Marcelle Bergeron,
Lucian Chow, and Martin G. Täuber

Infectious Diseases Division, San Francisco General Hospital,
Department of Neurology, San Francisco VA Medical Center, and
Departments of Medicine and Neurology, University of California San
Francisco, San Francisco, California

To evaluate the role of tumor necrosis factor- α (TNF- α) in neuronal injury in experimental group B streptococcal meningitis, infected neonatal rats were treated with a monoclonal antibody against TNF- α (20 mg/kg intraperitoneally) or saline given at the time of infection. Histopathology after 24 h showed necrosis in the cortex and apoptosis in the hippocampal dentate gyrus. Treated animals had significantly less hippocampal injury than did controls ($P < .001$) but had similar cortical injury and cerebrospinal fluid (CSF) inflammation. The antibody was then administered directly intracisternally (170 μ g) to test whether higher CSF concentrations reduced inflammation or cortical injury. Again, hippocampal apoptosis was significantly reduced ($P < .01$), while cortical injury and inflammation were not. Thus, TNF- α played a critical role in neuronal apoptosis in the hippocampus, while it was not essential for the development of inflammation and cortical injury in this model.

Bacterial meningitis continues to be an important clinical problem, and morbidity and mortality remain unacceptably high. The prognosis is particularly poor in neonates, as reflected by mortality rates of 20%–40% and severe long-term neurologic sequelae in as many as one-third of the survivors [1, 2]. Long-term morbidity caused by meningitis includes hearing loss, hydrocephalus, and sequelae associated with parenchymal damage, including learning disabilities, memory loss, cerebral palsy, and seizure disorders. The mechanisms that lead to neuronal injury in meningitis are under active investigation. We have established an infant rat model of neonatal meningitis due to group B streptococci (GBS) that is well-suited for examining factors that contribute to neuronal injury [3]. Two forms of neuronal injury can be distinguished in the model, cortical neuronal necrosis and apoptosis of neurons in the dentate gyrus of the hippocampus [4].

The importance of tumor necrosis factor- α (TNF- α) in bacterial meningitis has been well-established. Cell wall components of meningeal pathogens induce the release of TNF- α into the cerebrospinal fluid (CSF), and the cytokine plays an important role in the subsequent generation of subarachnoid space inflammation [5, 6]. In patients with bacterial meningitis,

CSF levels of TNF- α are elevated [7, 8]. High levels of TNF- α are of diagnostic value for bacterial meningitis and correlate positively with morbidity and mortality [7, 9, 10]. Furthermore, TNF- α may be involved in causing brain damage in bacterial meningitis. Work in experimental models of meningitis showed that TNF- α induced enhanced blood-brain barrier permeability and brain edema [11, 12]. Whether TNF- α contributes directly to the development of neuronal injury is not known. In the present study, we examined the role of TNF- α on the development of neuronal injury in the infant rat model of GBS meningitis, by use of a monoclonal antibody against TNF- α (TNF MAb). Treatment with antibodies against TNF- α has previously been shown to reduce blood-brain barrier permeability in hematogenous *Haemophilus influenzae* type b meningitis and to enhance survival in gram-negative sepsis and in GBS infection [13–15].

Materials and Methods

Infecting organism. A GBS type III isolate, one of the most common types causing neonatal meningitis (gift of C. Rubens, University of Washington, Seattle), was used as described [3]. The organism was grown on blood agar plates, cultured overnight in 10 mL of Todd-Hewitt broth, diluted in fresh medium, and grown for 3 h to logarithmic phase. The suspension was centrifuged for 10 min at 5000 *g* and resuspended in normal saline to the desired density, and the absorbance was measured. An average inoculum size of 10^4 cfu was used to infect the rats.

Model of meningitis. Nursing Sprague-Dawley rat pups with their dams were purchased and infected on postnatal day 11 by direct intracisternal injection of 10 μ L of a suspension of the infecting organism with a 32-gauge needle. Control animals received an identical injection of sterile saline. Treatment with murine TNF MAb (Bayer, Berkeley, CA) or saline was started at the time of infection. In a first set of experiments, animals randomly received an intraperitoneal injection of 20 mg/kg TNF MAb ($n = 21$) or the same amount of sterile saline ($n = 19$). In a second set

Received 13 November 1996; revised 4 April 1997.

Presented in part: 8th European Congress of Clinical Microbiology and Infectious Diseases, Lausanne, Switzerland, 25–28 May 1997.

This study was approved by the Committee on Animal Research at the University of California, San Francisco, and followed National Institutes of Health guidelines for the performance of animal experiments.

Financial support: NIH (NS-32553, NS-34028), Swiss National Science Foundation (to S.L.L.), Bayer Corp.

Reprints or correspondence (present address): Dr. Martin Täuber, Institute for Medical Microbiology, University of Berne, Friedbühlstrasse 51, 3010 Berne, Switzerland.

* Present affiliations: University Hospital, Basel, Switzerland.

The Journal of Infectious Diseases 1997;176:693–7

© 1997 by The University of Chicago. All rights reserved.
0022-1899/97/7603-0020\$02.00

of experiments, 170 μg (40 μL) of the TNF MAb ($n = 19$) or an equal amount of saline ($n = 17$) was directly administered intracisternally 30 min after infection. Pups were returned to their mothers, and 18 h later, they were weighed and assessed clinically for their ability to ambulate and right themselves. The presence of spontaneously occurring seizures was documented during the following 2 h. A sample of CSF (10–20 μL) was obtained by puncture of the cisterna magna. Bacterial titers in CSF were determined by plating 10-fold dilutions on blood agar plates and incubating the plates overnight at 37°C in room air. CSF lactate and glucose concentrations were determined by use of a two-channel autoanalyzer (YSI model 2300 G/L; Yellow Springs Instrument, Yellow Springs, OH) [16].

Animals were then treated with a single dose of ceftriaxone, 100 mg/kg subcutaneously. Twenty-four hours after infection, animals were sacrificed by intraperitoneal injection of pentobarbital (200 mg/kg). If an animal had to be sacrificed prematurely for ethical reasons or died spontaneously before 24 h, a randomly chosen littermate from the comparison group was sacrificed to assure similar survival times in the experimental groups (intraperitoneal experiments: 23.5 \pm 1.4 h in active group vs. 22.5 \pm 1.9 h in controls [not significant]; intracisternal experiments: 22.4 \pm 2.0 h in both groups). Animals that died unobserved were excluded from the analysis.

Brain preparation. Immediately after sacrifice, brains were removed and postfixed overnight in 4% paraformaldehyde in PBS (pH 7.4) at 4°C and then placed in 30% phosphate-buffered sucrose. Brains were cut at 40–60 μm thickness on a vibratome, and sections were mounted on gelatinized glass slides for staining. After dehydration, sections were stained by Nissl's method with cresyl violet, slides were rehydrated, and coverslips were fixed with Permount.

End points. Animals were weighed at 0 and 18 h after infection to assess weight loss. The degree of inflammation in the subarachnoid space was scored by a predetermined scheme: 0 = no inflammation; 1 = occasional inflammatory cells; 2 = inflammatory cells forming an infiltrate not involving the entire depth of the subarachnoid space; 3 = inflammatory infiltrate involving the entire subarachnoid space. Neuronal injury was scored for the cortex and the hippocampus. Cortical neuronal injury was defined as areas of decreased density of neurons or frank cortical necrosis and was quantitated as previously described [4, 17]. Briefly, 12 cortical sections spanning the middle half of the brain were scored in each animal for the presence or absence of neuronal injury, and the average injury score was used for statistical analysis. The scoring

system for cortical injury had previously been validated in a random set of animals ($n = 8$) by computer-assisted quantitation of injury performed by an independent investigator. The correlation between the two scoring systems was excellent ($r = .98$, $P < .001$). Cortical injury in the present study was scored by a single investigator (M.G.T.) blinded to all experimental data.

Injured neurons in the dentate granule cell layer of the hippocampus were defined as cells showing markedly shrunken, condensed nuclei [4, 18]. Brain sections containing all four blades of the dentate gyrus were scored. Each blade was scored separately as follows: 0 = no injury; 1 = $\leq 25\%$ of neurons abnormal; 2 = 25%–75% of neurons abnormal; 3 = $> 75\%$ of neurons abnormal. Scores for all four blades were added and averaged for all sections. Injury in the hippocampus was scored independently by two investigators (M.G.T. and M.B.) blinded to the clinical, microbiologic, and treatment data of the animals, and the two scores were averaged for data analysis and presentation. The two scores of the two investigators correlated well ($r = .71$; $P < .001$).

Statistics. Weight loss and bacterial titers are presented as mean \pm SD, and differences between groups were analyzed by Student's *t* tests. Scores between groups were compared by the Mann-Whitney rank sum test. Seizure incidence and spontaneous death rates were compared by χ^2 .

Results

Systemic Administration of TNF MAb

Clinical disease. By 18 h after infection, all animals had meningitis, as evidenced by lethargy to obtundation, significantly altered CSF concentrations of lactate and glucose, and positive CSF bacterial titers (table 1). Treatment with TNF MAb had no significant effect on CSF bacterial titers and CSF concentrations of lactate and glucose (table 1). As a result of infection, all animals lost weight, but the weight loss was more pronounced in untreated animals than in animals treated with TNF MAb (3.0 \pm 0.5 g vs. 2.5 \pm 0.5 g; $P < .005$). Treatment with TNF MAb also significantly reduced the incidence of spontaneous death (24% in treated animals vs. 68% in controls; $P < .02$).

Histopathology. Histopathologically, the disease in this model was characterized by an intense granulocytic inflammation in the subarachnoid and ventricular space and by two

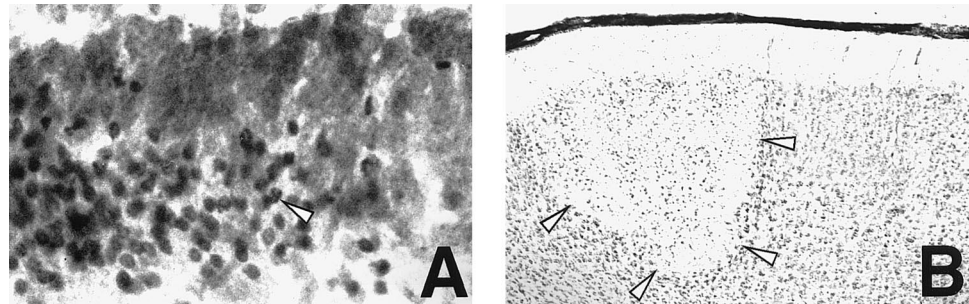
Table 1. Cerebrospinal fluid parameters in infant rats with experimental group B meningitis.

Parameter	Uninfected	Infected (at 18 h)		
		Controls	TNF MAb ip	TNF MAb ic
Bacterial titers				
(log ₁₀ cfu/mL)	NA	9.6 \pm 1.1 (36)	9.1 \pm 1.4 (21)	9.5 \pm 1.4 (19)
Lactate (mEq/L)	1.5 \pm 0.9* (16)	6.8 \pm 1.9 (8)	7.0 \pm 2.0 (7)	7.0 \pm 2.0 (10)
Glucose (mg/dL)	36.9 \pm 12.4* (16)	4.9 \pm 6.6 (8)	5.1 \pm 4.1 (7)	1.2 \pm 2.5 (10)

NOTE. Data are mean \pm SD (*n*). TNF MAb, monoclonal antibody to tumor necrosis factor- α ; ip, intraperitoneally; ic, intracisternally. NA, not applicable.

* $p < .001$ vs. all infected groups.

Figure 1. Pattern of neuronal injury in infant rats with group B streptococcal meningitis. In hippocampus (A), neuronal injury shows characteristics of apoptosis [4, 18], with dense, shrunken nuclei (arrowhead) in dentate gyrus (cresyl violet, $\times 1000$). In cortex (B), injury is of ischemic origin, with wedge-shaped focal areas of reduced neuronal density (arrowheads) (cresyl violet, $\times 200$).



forms of neuronal injury, cortical necrosis and apoptotic injury of the dentate gyrus in the hippocampus (figure 1) [3, 4, 17]. Treatment with TNF MAb had no measurable effect on the histopathologic scoring of inflammation in the subarachnoid space, since all animals showed maximal (grade 3) inflammation. Similarly, there was no significant reduction in cortical injury (median [range] for treated animals: 2.4 [0–4.4]; controls: 2.9 [0–5.8]; $P = .30$) (figure 2A). In contrast, there was a significant beneficial effect of TNF MAb treatment on the extent of apoptosis in the dentate gyrus of the hippocampus (median [range] for treated animals: 2.7 [1.2–4.6]; controls: 4.1 [2.3–5.8]; $P < .001$) (figure 2B). Duration of survival after induction of infection had no detectable influence on the score of both types of injury. Uninfected animals treated with TNF MAb showed none of the above-described changes.

Intracisternal Administration of TNF MAB

Given the lack of a significant effect of systemically administered antibody on CSF inflammation and cortical injury, TNF MAb (170 μg) was injected in a second experiment directly into the cisterna magna to reach higher CSF concentrations.

Clinical disease. As with the systemic administration of antibody, intracisternal administration did not result in significant differences in CSF bacterial titers or CSF concentrations of lactate or glucose (table 1). Also in agreement with the systemic experiments, there was a significant difference in weight loss between intracisternally treated animals and controls ($2.3 \pm 0.4 \text{ g}$ vs. $3.0 \pm 0.4 \text{ g}$; $P < .0001$), but the difference

in spontaneous death rates did not reach statistical significance in this set of experiments (31% vs. 53%; $P = .31$).

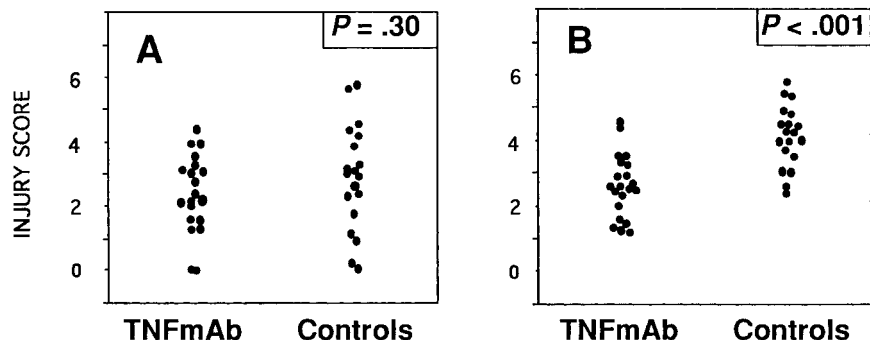
Histopathology. Similar to results with systemic administration of antibody, inflammation in the subarachnoid space showed no significant difference between treated and untreated animals, and there was no significant effect of the antibody on cortical injury (median [range] in treated animals: 1.3 [0–5.6]; controls: 3.5 [0–5.0]; $P = .29$) (figure 3A). The effect of TNF MAb on hippocampal apoptotic injury was confirmed with intracisternal administration (median [range] for treated animals: 1.7 [0.5–3.5]; controls: 3.2 [1–6.2]; $P < .01$) (figure 3B).

Discussion

The present study in a rat model of neonatal meningitis caused by GBS indicates that TNF- α plays a critical role in causing injury in neurons of the dentate gyrus of the hippocampus. Previous studies in the same model and in a rabbit model of pneumococcal meningitis have established that this form of neuronal injury shows the characteristic features of apoptosis [4, 18]. Taken together, these data thus provide a strong link between the action of TNF- α and the induction of apoptosis in a selected neuronal population in vivo during bacterial meningitis.

It has been recognized, largely on the basis of in vitro studies, that TNF- α can induce apoptosis in a number of cell types [19, 20]. Some studies have addressed the role of TNF- α in causing cellular injury in the central nervous system. The cytokine can be toxic to cultured human fetal cortical neurons at physiologi-

Figure 2. Injury scores in cortex (A) and hippocampus (B) of infant rats with group B streptococcal meningitis treated systemically with monoclonal antibody (MAb) against TNF- α or saline (controls). 20 mg/kg TNF MAb or equal volume of saline was administered intraperitoneally at time of infection. Statistics by Mann-Whitney rank sum test.



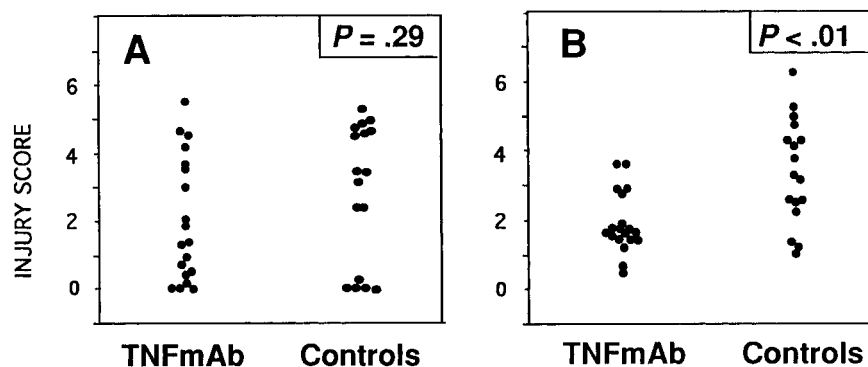


Figure 3. Injury scores in cortex (A) and hippocampus (B) of infant rats with group B streptococcal meningitis treated intracisternally with monoclonal antibody (MAb) against TNF- α or saline (controls). TNF MAb (170 μ g) or equal volume of saline was administered intracisternally 30 min after initiating infection. Statistics by Mann-Whitney rank sum test.

cally relevant concentrations, and a recent study using a human neuroblastoma cell line differentiated to a neuronal phenotype with retinoid acid showed that TNF- α induced apoptosis [21, 22]. There is also good evidence for a toxic effect of TNF- α in oligodendrocytes, the cell population responsible for myelin production in the central nervous system [23]. However, not all studies have found that TNF- α is involved in the development of neurotoxicity. In primary cultures of rat neurons, pretreatment with TNF- α promoted intracellular calcium homeostasis and protected neurons from damage caused by excitatory amino acids or hypoglycemia [24]. Similarly, a study in mice lacking TNF- α receptors found that ischemic and excitotoxic brain injury were increased compared with that in genetically normal control animals, indicating that TNF- α may have protective properties in this model of acute brain injury [25]. Thus, the role of TNF- α in acute neuronal injury is complex and likely influenced by specifics of the experimental system studied. In our rat model of neonatal meningitis, TNF- α appeared to be predominantly harmful, since several experimental end points, including neuronal apoptosis in the dentate gyrus of the hippocampus, were beneficially affected by treatment with TNF- α antibody.

The exact mechanisms by which TNF- α induced hippocampal apoptosis remain to be defined. A wealth of studies have documented that the cytotoxic effects of TNF- α are related to the production of oxidative radicals [26]. This pathway appears to be particularly critical in TNF- α -induced apoptosis, including in neuronal cells [22]. We have previously found in the infant rat model of meningitis that scavenging of reactive oxygen intermediates with the spin trapping agent α -phenyl-tert-butyl nitron (PBN) was highly protective against apoptotic injury in the hippocampus, suggesting that oxygen intermediates play an important role in this form of injury *in vivo* [4]. Other mechanisms, however, could account for the effect of TNF- α . Cytokines may affect excitotoxic neuronal injury caused by glutamate and other excitatory amino acids, either by increasing their release from glial cells or by modulating excitatory amino acid receptors [21]. There is increasing evidence that excitatory amino acids can induce apoptosis in neurons under certain circumstances [27], and we have shown that they contribute to neuronal injury in the hippocampus in the

infant rat model of meningitis [17]. Thus, TNF- α could exert its effect by modulating excitatory amino acid-induced injury. Interestingly, excitatory amino acid receptor stimulation also leads to induction of reactive oxygen intermediates as important mediators of cellular injury [28]. Thus, regardless of whether TNF- α induces apoptosis in the hippocampus by a direct action on neurons or through modulation of the excitatory amino acid pathway, scavenging of oxygen radicals can be expected to be highly protective, as was the case in our study with PBN [4].

TNF- α did not appear to play an essential role in mediating subarachnoid space inflammation or cortical neuronal injury in the present study. These findings were surprising in light of previous studies in similar models of bacterial meningitis, in which TNF- α appeared to play an important role in generating CSF inflammation and in which antibodies to TNF- α were effective in reducing CSF inflammation [5, 11]. Our results are likely not a reflection of a general lack of biologic activity of the TNF MAb used in the study, since the antibody showed significant beneficial effects on hippocampal injury as well as systemic parameters, seizure activity, and mortality. Furthermore, experiments in which the TNF MAb was administered intrathecally indicated that its limited effect was not likely the result of inadequate CSF concentrations. In these studies, ~20% of the systemic dose of the antibody was injected directly into the CSF, resulting in estimated CSF concentrations 10- to 100-fold higher than after systemic administration. An important difference between the present study and previous studies that may explain the discrepancy is the time points of examination. Previous studies focused on early time points up to 6 h after infection, while animals were examined 18–24 h after infection in the present study. It is conceivable that TNF- α is critical early in infection, while other inflammatory mediators may compensate for TNF- α in later stages of the disease.

The differential effect of TNF MAb on hippocampal and cortical injury underlines the possibility that different mechanisms may be involved in these two forms of injury. Previous studies indicated that cortical injury is caused primarily by ischemia, which in turn is likely to be a result of the effect of subarachnoid space inflammation on the cerebral vasculature [4, 17]. Given this causal relationship, it is not surprising that

the failure of TNF MAb to affect CSF inflammation resulted in a corresponding lack of protection against ischemic cortical injury. Hippocampal injury, on the other hand, does not appear to be of ischemic origin, since the ischemia-sensitive structures of the hippocampus (CA1/CA3) are not affected in the meningitis model and since the dentate gyrus is not considered to be particularly ischemia-sensitive. It appears more likely that soluble mediators, such as TNF- α or excitatory amino acids, have direct effects on the neurons in the dentate gyrus, possibly by diffusing from the ventricular space, which is in close proximity to the dentate gyrus and shows uniform inflammation in the model [17].

The clinical significance of the hippocampal injury observed in our model, and thus of the selective beneficial effect of TNF MAb on this form of neuronal injury, needs to be further explored. Neonatal meningitis often results in mental retardation and learning disabilities [2], and the selective injury to the hippocampus in our model is intriguing, since this structure plays a critical role in learning and memory functions. It is unknown whether similar changes can be observed in humans after meningitis, but similar findings in pneumococcal meningitis in rabbits indicate that hippocampal injury is not unique to our infant rat model [18]. Independent of these questions, our study significantly expands the understanding of the molecular mechanisms of brain injury in meningitis by documenting a critical role of TNF- α in causing apoptotic cell death in a selected subpopulation of neurons.

References

- Anderson SG, Giulbert GL. Neonatal gram negative meningitis: a 10-year review, with reference to outcome and relapse of infection. *J Paediatr Child Health* **1990**;1990:212–6.
- Edwards MS, Rench MA, Haffar AAM, Murphy MA, Desmond MM, Baker CJ. Long-term sequelae of group B streptococcal meningitis in infants. *J Pediatr* **1985**;106:717–22.
- Kim YS, Sheldon RA, Elliot BR, Liu Q, Ferriero DM, Täuber MG. Brain damage in neonatal meningitis caused by group B streptococci in rats. *J Neuropathol Exp Neurol* **1995**;54:531–9.
- Leib SL, Kim YS, Chow LL, Sheldon RA, Täuber MG. Reactive oxygen intermediates contribute to necrotic and apoptotic neuronal injury in an infant rat model of bacterial meningitis due to group B streptococci. *J Clin Invest* **1996**;98:2632–9.
- Mustafa MM, Ramilo O, Olsen KD, et al. Tumor necrosis factor α in mediating experimental *Haemophilus influenzae* type b meningitis. *J Clin Invest* **1989**;84:1253–9.
- Ling EWY, Noya FJD, Ricard G, Beharry K, Mills EL, Aranda JV. Biochemical mediators of meningeal inflammatory response to group B streptococcus in the newborn piglet model. *Pediatr Res* **1995**;38:981–7.
- Mustafa MM, Lebel MH, Ramilo O, et al. Correlation of interleukin-1 β and cachectin concentrations in cerebrospinal fluid and outcome from bacterial meningitis. *J Pediatr* **1989**;115:208–13.
- Arditi M, Manogue KR, Caplan M, Yogev R. Cerebrospinal fluid cachectin/tumor necrosis factor- α and platelet-activating factor concentrations and severity of bacterial meningitis in children. *J Infect Dis* **1990**;162:139–47.
- Glimaker M, Kragstjerg P, Forsgren M, Olcen P. Tumor necrosis factor- α (TNF α) in cerebrospinal fluid from patients with meningitis of different etiologies: high levels of TNF α indicate bacterial meningitis. *J Infect Dis* **1993**;167:882–9.
- Dulkerian SJ, Kilpatrick L, Costarino AT, et al. Cytokine elevation in infants with bacterial and aseptic meningitis. *J Pediatr* **1995**;126:872–6.
- Saukkonen K, Sande S, Cioffe C, et al. The role of cytokines in the generation of inflammation and tissue damage in experimental gram-positive meningitis. *J Exp Med* **1990**;171:439–48.
- Quagliarello VJ, Wispelwey B, Long WJ, Scheld WM. Recombinant human interleukin-1 induces meningitis and blood-brain barrier injury in the rat. *J Clin Invest* **1991**;87:1360–6.
- Kim KS, Wass CA, Cross AS, Opal SM. Modulation of blood-brain barrier permeability by tumor necrosis factor and antibody to tumor necrosis factor in the rat. *Lymphokine Cytokine Res* **1992**;11:293–8.
- Silva AT, Baystone KF, Cohen J. Prophylactic and therapeutic effect of a monoclonal antibody to tumor necrosis factor- α in experimental gram-negative shock. *J Infect Dis* **1990**;162:421–7.
- Teti G, Mancuso G, Tomasello F. Cytokine appearance and effect of anti-tumor necrosis factor alpha antibodies in a neonatal rat model of group B streptococcal infection. *Infect Immun* **1993**;61:227–35.
- Täuber MG, Sande E, Fournier MA, Tureen JH, Sande MA. Fluid administration, brain edema, and cerebrospinal fluid lactate and glucose concentrations in experimental *Escherichia coli* meningitis. *J Infect Dis* **1993**;168:473–6.
- Leib SL, Kim SY, Ferriero DM, Täuber MG. Neuroprotective effect of excitatory amino acid antagonist kynurenic acid in experimental bacterial meningitis. *J Infect Dis* **1996**;173:166–71.
- Zysk G, Brück W, Gerber J, Brück Y, Prange HW, Nau R. Anti-inflammatory treatment influences neuronal apoptotic cell death in the dentate gyrus in experimental pneumococcal meningitis. *J Exp Neurol Neuropathol* **1996**;55:722–8.
- Higuchi M, Singh S, Jaffrezou JP, Aggarwal BB. Acidic sphingomyelinase-generated ceramide is needed but not sufficient for TNF-induced apoptosis and nuclear factor- κ B activation. *J Immunol* **1996**;157:297–304.
- Malorni W, Rainaldi G, Tritarelli E, et al. Tumor necrosis factor- α is a powerful apoptotic inducer in lymphoid leukemic cells expressing the P-170 glycoprotein. *Int J Cancer* **1996**;67:238–47.
- Gelbart HAK, Dzenko K, DiLoreto D, del Cerro K, Epstein LG. Neurotoxic effects of tumor necrosis factor in primary human neuronal cultures are mediated by activation of the glutamate AMPA receptor subtype: implications for AIDS neuropathogenesis. *Dev Neurosci* **1993**;15:417–22.
- Talley AK, Dewhurst S, Perry SW, et al. Tumor necrosis factor- α -induced apoptosis in human neuronal cells: protection by the antioxidant *N*-acetylcysteine and the genes *bcl-2* and *crmA*. *Mol Cell Biol* **1995**;15:2359–66.
- D'Souza S, Alinauska K, McCrear E, Goodyer C, Antel JP. Differential susceptibility of human CNS-derived cell populations to TNF-dependent and -independent immune-mediated injury. *J Neurosci* **1995**;15:7293–300.
- Cheng B, Christakos S, Mattson M. Tumor necrosis factors protect neurons against metabolic-excitotoxic insults and promote maintenance of calcium homeostasis. *Neuron* **1994**;12:139–53.
- Bruce AJ, Boling W, Kindy MS, et al. Altered neuronal and microglial response to excitotoxic and ischemic brain injury in mice lacking TNF receptors. *Nature Med* **1996**;2:788–94.
- Larrick JW, Wright SC. Cytotoxic mechanism of tumor necrosis factor- α . *FASEB J* **1990**;4:3215–23.
- Bonfoco E, Krainic D, Ankarcona M, Nicotera P, Lipton ST. Apoptosis and necrosis: two distinct events induced, respectively, by mild and intense insults with *N*-methyl-D-aspartate or nitric oxide/superoxide in cortical cell cultures. *Proc Natl Acad Sci USA* **1995**;92:7162–6.
- Reynolds JJ, Hastings TG. Glutamate induces the production of reactive oxygen species in cultured forebrain neurons following NMDA receptor activation. *J Neurosci* **1995**;15:3318–27.