

BRIEF REPORT

Successful Treatment with Miltefosine of Disseminated Cutaneous Leishmaniasis in a Severely Immunocompromised Patient Infected with HIV-1

Christine Schraner,^{1,a} Barbara Hasse,^{1,a} Urs Hasse,² Doris Baumann,¹ Anja Faeh,³ Günther Burg,² Felix Grimm,⁴ Alex Mathis,⁴ Rainer Weber,¹ and Huldrych F. Günthard¹

¹Division of Infectious Diseases and Hospital Epidemiology, ²Institute of Dermatology, and ³Department of Medicine, University Hospital Zurich, and ⁴Institute of Parasitology, University of Zurich, Zurich, Switzerland

We describe here a case of disseminated cutaneous leishmaniasis due to *Leishmania major* in a severely immunocompromised patient from Burkino Faso, Africa, who is infected with human immunodeficiency virus-1. The skin lesions failed to respond to full treatment courses of amphotericin B, sodium stibogluconate, and liposomal amphotericin B but were successfully treated with miltefosine, an alkylphosphocholine analogue.

Over the past 2 decades, leishmaniasis, in particular visceral leishmaniasis (VL), has been recognized as an opportunistic disease in immunocompromised patients, particularly those infected with HIV. *Leishmania*-HIV coinfection is very common in areas where leishmaniasis is endemic and is identified as the HIV pandemic spreads [1–3]. In contrast to the literature on VL, only scarce data are available on cutaneous leishmaniasis (CL) caused by dermatropic species in HIV-infected patients [4, 5]. However, recent data from French Guiana suggests that even in moderately immunosuppressed HIV-infected individuals, CL is characterized by a higher rate of recurrence and is more difficult to treat than it is in HIV-negative individuals [5].

Treatment of leishmaniasis is difficult because of the limited

number of effective antiparasitic agents available. Currently, daily injections with pentavalent antimony, in the form of meglumine antimonite, for 28 days is the standard treatment. Sodium stibogluconate, another antimonial drug, has shown excellent efficacy at a dose of 20 mg/kg in a large clinical trial that included immunocompetent young soldiers with either CL (treatment course, 20 days) or VL (treatment course, 30 days) [6]. In cases of resistance to antimony, low-dose amphotericin B is administered (14 doses of 0.5 mg/kg, given on alternating days). A more potent but much more expensive alternative is intravenously administered liposomal amphotericin B (5 mg/kg for 5 days). Because of the considerable toxicity of these parenteral agents, alternative drugs are being evaluated, including miltefosine. Miltefosine (hexadecylphosphocholine) is an alkylphosphocholine analogue that was originally developed as an antitumor agent but proved to be clinically ineffective against tumors, with intolerable adverse effects. It interferes with cell signal-transduction pathways and inhibits phospholipid and sterol biosynthesis; although the exact mechanism of action with regard to *Leishmania* has not been fully elucidated [7]. Miltefosine is effective against *Leishmania* species in vitro [8] and in vivo [9] and can be administered orally [10]. Its efficacy and tolerability in immunocompetent individuals have already been proven in earlier studies [11–13]. In a recent phase III clinical trial for the treatment of VL in India, a cure rate of 94% was reported [14]. Furthermore, it was recently shown that among patients coinfecting with *Leishmania* and HIV (almost all of whom were affected with VL) who had experienced failure of standard leishmaniasis treatment, an initial response rate of 64% and a cure rate of 43% was achieved during the first treatment cycle with miltefosine [15]. Thus, miltefosine is the first oral agent that appears to be highly effective and well tolerated for the treatment of VL and CL [16, 17].

We describe an HIV-infected patient with severe disseminated cutaneous *Leishmania* coinfection that did not respond to full courses of conventional treatment but was successfully treated with miltefosine.

Case report. In April 2001, a formerly healthy 43-year-old male immigrant from Burkina Faso, Africa, presented with a 6-month history of maculo-papulo-nodular lesions on his forehead and right leg and behind his left ear (figure 1, left panels). He entered Switzerland in January 2001 and had occasionally visited the Ivory Coast in the past. He reported no fever, malaise, or weight loss (body weight, 60 kg). Except for the skin lesions, the findings of physical examination were unremarkable. Findings of laboratory tests were normal except for mild

Received 13 December 2004; accepted 3 February 2005; electronically published 27 April 2005.

^a C.S. and B.H. contributed equally to this work.

Reprints or correspondence: Dr. Huldrych Günthard, Division of Infectious Diseases and Hospital Epidemiology, University Hospital Zurich, Rämistrasse 100, CH-8091 Zurich, Switzerland (huldrych.guenthard@usz.ch).

Clinical Infectious Diseases 2005;40:e120–4

© 2005 by the Infectious Diseases Society of America. All rights reserved.
1058-4838/2005/4012-00E5\$15.00

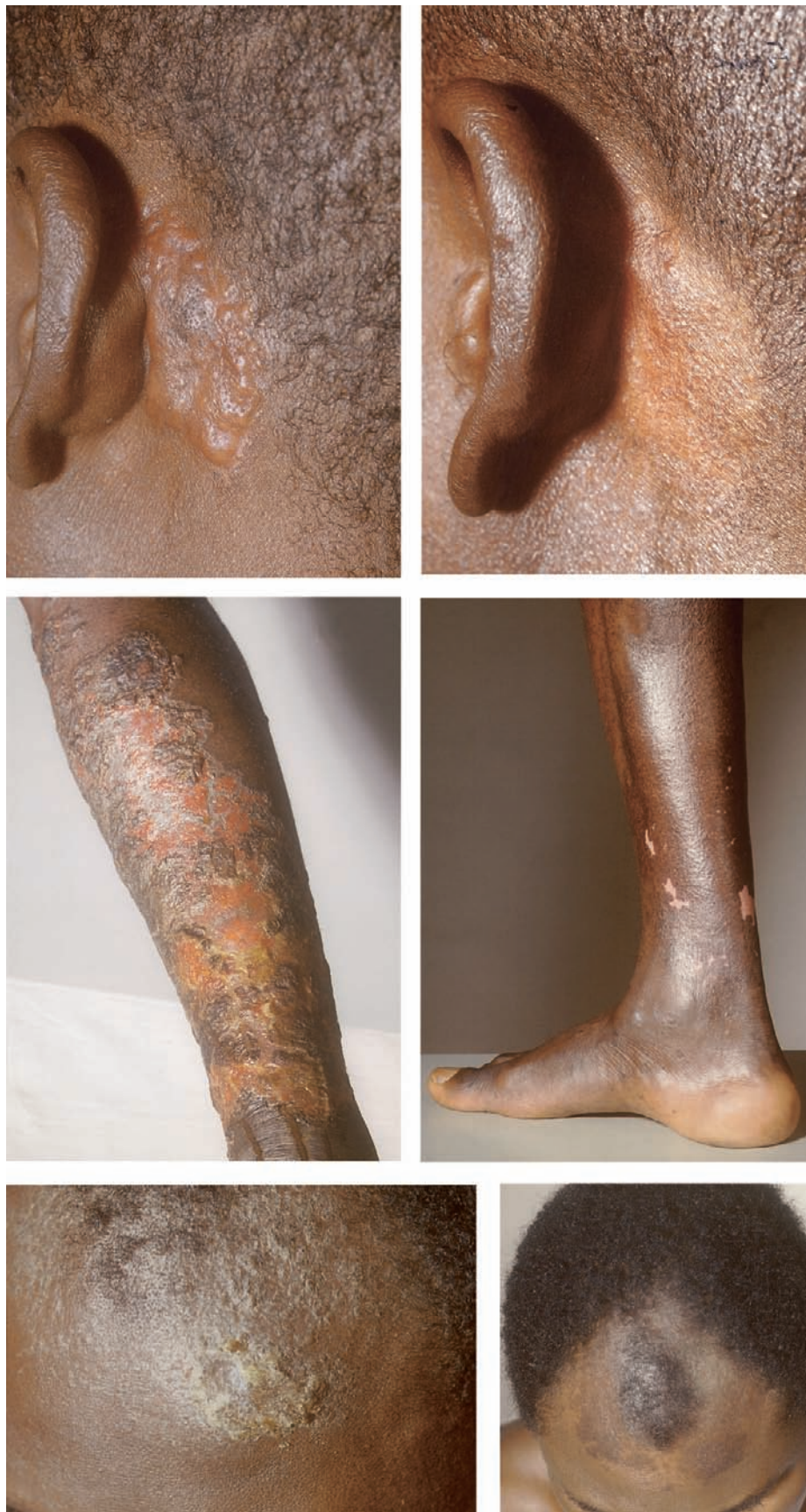

Figure 1. Retroauricular region, right leg, and forehead of the patient before (*left panels*) and after (*right panels*) receiving miltefosine therapy (50 mg twice daily for 3 months).

normochromic, normocytic anemia (hemoglobin level, 11.7 g/dL; normal range, 13.5–17.2 g/dL) and lymphopenia (lymphocyte count, 0.77×10^3 cells/ μ L; normal range, 1.50 – 4.00×10^3 cells/ μ L).

The positive result of a screening test for HIV-1 was confirmed by Western blot analysis. The CD4 cell count was 10 cells/ μ L (CD4 cell percentage, 2%), and the HIV RNA load was 152,428 copies/mL. Combination antiretroviral therapy with lamivudine, zidovudine, and nelfinavir was initiated, as well as primary prophylaxis (with trimethoprim-sulfamethoxazole) against *Pneumocystis jirovecii* (*carinii*) pneumonia.

Histological examination of specimens from skin lesions showed subepidermal infiltrations with lymphocytes, plasma cells, and histiocytes. In the histiocytes, small inclusion bodies representing amastigotes could be seen (figure 2). The presence of *Leishmania* DNA in samples from skin biopsies was repeatedly demonstrated by PCR [6]. In addition, the *Leishmania* miniexon locus was amplified by PCR [18], and sequence analysis revealed 99.4% identity (312 of 314 bp) with *Leishmania major* genomic sequences (e.g., GenBank accession number AC 121230) and the corresponding gene sequence of *Leishmania venezuelensis* (strain MHOM/VE/74/PM-H3 [GenBank accession number AY 155507]); the latter sequence differed by an additional 2-nucleotide deletion. The sequence of the next best match, *Leishmania aethiopsica*, was only 75.5% identical to our sequence. Repeated cultures of samples from skin biopsies were positive; however, zymodeme analysis could not be performed, because the isolates were lost due to microbial contamination. Specific antibodies could be demonstrated by an immunofluorescence antibody test based on intracellular amastigote forms of *Leishmania infantum* (titer, 1:160; normal titer, <1:40), whereas an ELISA based on soluble antigens of promastigote stages of the same species had negative results. A CT scan of the chest and abdomen showed generalized lymphadenopathy. We initially suspected visceral involvement, but various attempts to amplify *Leishmania* DNA from PBMCs, bronchoalveolar lavage fluid, and samples from biopsies of bone marrow and subcarinal enlarged lymph nodes had negative results. In addition, samples from lymph node and bone marrow biopsies revealed negative histological findings, and cultures of those samples were negative for *Leishmania* species. Thus, VL could not be proven.

In addition to the skin lesions, the patient developed fever and malaise. He was hospitalized, and amphotericin B therapy (1 mg/kg/day) administered intravenously was started. Because of nephrotoxicity, the dosage of amphotericin B was reduced to 0.5 mg/kg and was later increased to 0.8 mg/kg subsequently. The patient received therapy for a total of 21 days and received an average dose of 0.64 mg/kg/day.

Two weeks after completion of amphotericin B therapy, the patient developed new nodular lesions on his arms and face,

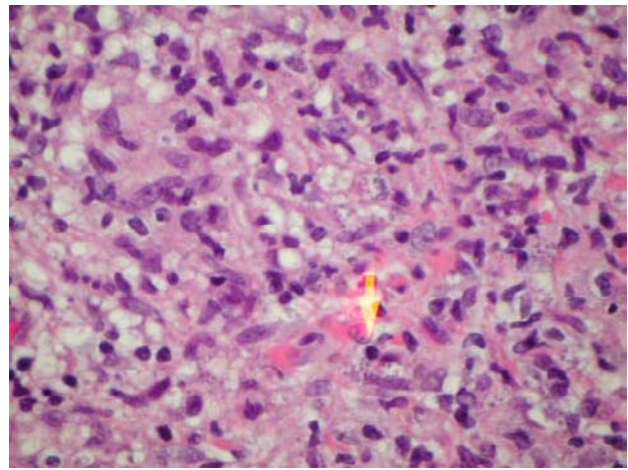


Figure 2. Hematoxylin and eosin–stained sample of a skin lesion showing subepidermal infiltration with lymphocytes, plasma cells, and histiocytes, which contain small inclusion bodies representing amastigotes (arrow).

and the old lesions erupted again. On his right leg, a progressive scaly exanthema appeared. Relapse of leishmaniasis was suspected and then proven by histological analysis. Subsequently, sodium stibogluconate, at a dosage of 20 mg/kg, was administered for 21 days. After a partial and brief improvement of the skin lesions, the patient presented with rapidly progressing lesions on his hands and face. His right lower leg was swollen, and an ulcer developed. A course of liposomal amphotericin B (AmBisome; Fujisawa Healthcare), given on days 1–5, 9, 16, 23, 30, and 37 (dosage, 5 mg/kg), was unsuccessful, and the skin lesions progressed further. The patient had to be readmitted to the hospital for local antiseptic treatment with topical paromomycin (20% ointment for 7 weeks), which showed very limited effect.

Because 3 consecutive “classic” courses of established anti-leishmaniasis treatment had failed, therapy with miltefosine (Zentaris), at 100 mg per day (i.e., 2 capsules of 50 mg daily by mouth), was initiated under a compassionate use protocol, after written informed consent was obtained. After a few days, a clear improvement of the skin lesions was apparent, and after 3 months, the patient experienced complete remission (figure 1, right panels). Apart from a mild elevation of the lactate dehydrogenase level, no other laboratory abnormalities or adverse effects were noted. To prevent relapse, we continued to give the patient miltefosine therapy until his immune system was partly restored. After a total of 18 months, the CD4 cell count was 290 cells/ μ L (CD4 cell percentage, 10%), and miltefosine therapy was stopped. The CD4 cell count was >200 cells/ μ L at 1 year prior to the discontinuation of therapy, and the viral load dropped to <50 copies/mL at 3 months after the initiation of antiretroviral treatment and remained at that level for the entire subsequent observation period. Two years later,

the CD4 cell count was 317 cells/ μ L (CD4 cell percentage, 16%), and no signs of CL or VL were detectable.

Discussion. The geographical origin of the patient, his travel history (which was confined to Africa and Europe), and the DNA sequence data suggest that the infectious agent should be classified as *L. major*. The miniexon locus sequence of *L. venezulensis* showed the same degree of identity, but recent sequence data of the rDNA internal transcribed spacer regions suggested that *L. major* and *L. venezulensis* are indeed very closely related and led to the speculation that the latter species might recently have been introduced into the New World in a manner similar to that of *L. infantum* [19].

The clinical presentation of leishmaniasis varies widely in both HIV-infected and immunocompetent patients [2, 3, 20]. In patients coinfecting with HIV and *Leishmania* species, cutaneous lesions may occur before, after, or at the same time as visceral lesions. However, exclusive cutaneous involvement does occur, although such presentation is rare. The clinical picture ranges from a few spontaneously healing lesions to diffuse external or internal disease, which may be accompanied by severe mucous membrane involvement [21]. Concomitant opportunistic diseases can mask the clinical presentation.

When evaluating a treatment, the natural history of leishmaniasis must be considered. In immunocompetent hosts, cutaneous lesions usually heal spontaneously in 1 month to 3 years, whereas lesions of mucocutaneous leishmaniasis and VL rarely, if ever, heal without treatment. Until now, guidelines for treatment of HIV-*Leishmania* coinfection have followed treatment schemes used for leishmaniasis in immunocompetent patients. Because of high relapse rates, treatment of HIV-*Leishmania* coinfection requires close monitoring of efficacy, and secondary prophylaxis for leishmaniasis should be considered. A recent nonrandomized, retrospective, open-label trial with 37 patients has shown that pentavalent antimony therapy given monthly prevented relapse in 93% of patients during the first year [22]. A close correlation exists between CD4 cell count, clinical presentation, and the evolution of disease. Up to one-fourth of patients coinfecting with HIV and *Leishmania* (manifesting mainly as VL) who remain in a state of severe immunosuppression may die within 1 month after diagnosis [23]. Thus, it is of utmost importance to increase the CD4 cell count by initiating potent antiretroviral therapy and to evaluate alternative first-line treatments. There have been obvious favorable results of miltefosine treatment for CL and VL [11, 12, 14]. However, there is only limited experience with this drug in HIV-infected patients [15], and, to our knowledge, the case reported here is the first documented case of CL caused by *L. major* that was treated with miltefosine. Interestingly, on the basis of in vitro results, one would not have expected such a good outcome, since, of 6 *Leishmania* species tested, *L. major* was the least sensitive to miltefosine [8]. In summary, the pre-

sent case illustrates a spectacular sustained therapeutic response of disseminated CL to miltefosine therapy in a severely immunocompromised patient with leishmaniasis refractory to standard treatments.

Acknowledgments

We thank the patient for his patience and for giving us the opportunity to publish his case. Furthermore, we thank Dr. Kurt Markwalder and Dr. Markus Schneemann, for helpful discussions. We thank Zentaris (formerly ASTA Medica) for providing the miltefosine.

Potential conflicts of interest. All authors: no conflicts.

References

1. Colebunders R, Depraetere K, Verstraeten T, et al. Unusual cutaneous lesions in two patients with visceral leishmaniasis and HIV infection. *J Am Acad Dermatol* **1999**;41:847–50.
2. Alvar J, Canavate C, Gutierrez-Solar B, et al. *Leishmania* and human immunodeficiency virus coinfection: the first 10 years. *Clin Microbiol Rev* **1997**;10:298–319.
3. Puig L, Pradinaud R. *Leishmania* and HIV co-infection: dermatological manifestations. *Ann Trop Med Parasitol* **2003**;97(Suppl 1):107–14.
4. Mattos M, Caiza A, Fernandes O, et al. American cutaneous leishmaniasis associated with HIV infection: report of four cases. *J Eur Acad Dermatol Venereol* **1998**;10:218–25.
5. Couppie P, Clyti E, Sobesky M, et al. Comparative study of cutaneous leishmaniasis in human immunodeficiency virus (HIV)-infected patients and non-HIV-infected patients in French Guiana. *Br J Dermatol* **2004**;151:1165–71.
6. Aronson NE, Wortmann GW, Johnson SC, et al. Safety and efficacy of intravenous sodium stibogluconate in the treatment of leishmaniasis: recent U.S. military experience. *Clin Infect Dis* **1998**;27:1457–64.
7. Sindermann H, Croft SL, Engel KR, et al. Miltefosine (Impavido): the first oral treatment against leishmaniasis. *Med Microbiol Immunol (Berl)* **2004**;193:173–80.
8. Escobar P, Matu S, Marques C, Croft SL. Sensitivities of *Leishmania* species to hexadecylphosphocholine (miltefosine), ET-18-OCH₃ (edelfosine) and amphotericin B. *Acta Trop* **2002**;81:151–7.
9. Schmidt-Ott R, Klenner T, Overath P, Aebischer T. Topical treatment with hexadecylphosphocholine (Miltefosine) efficiently reduces parasite burden in experimental cutaneous leishmaniasis. *Trans R Soc Trop Med Hyg* **1999**;93:85–90.
10. Kuhlencord A, Maniera T, Eibl H, Unger C. Hexadecylphosphocholine: oral treatment of visceral leishmaniasis in mice. *Antimicrob Agents Chemother* **1992**;36:1630–4.
11. Soto J, Toledo J, Gutierrez P, et al. Treatment of American cutaneous leishmaniasis with miltefosine, an oral agent. *Clin Infect Dis* **2001**;33:e57–61.
12. Jha TK, Sundar S, Thakur CP, et al. Miltefosine, an oral agent, for the treatment of Indian visceral leishmaniasis. *N Engl J Med* **1999**;341:1795–800.
13. Sundar S, Rosenkaimer F, Makharia MK, et al. Trial of oral miltefosine for visceral leishmaniasis. *Lancet* **1998**;352:1821–3.
14. Sundar S, Jha TK, Thakur CP, et al. Oral miltefosine for Indian visceral leishmaniasis. *N Engl J Med* **2002**;347:1739–46.
15. Sindermann H, Engel KR, Fischer C, Bommer W. Oral miltefosine for leishmaniasis in immunocompromised patients: compassionate use in 39 patients with HIV infection. *Clin Infect Dis* **2004**;39:1520–3.
16. Herwaldt BL. Leishmaniasis. *Lancet* **1999**;354:1191–9.
17. Murray HW. Clinical and experimental advances in treatment of visceral leishmaniasis. *Antimicrob Agents Chemother* **2001**;45:2185–97.
18. Amato VS, Rabello A, Rotondo-Silva A, et al. Successful treatment of

- cutaneous leishmaniasis with lipid formulations of amphotericin B in two immunocompromised patients. *Acta Trop* **2004**; 92:127–32.
19. Berzunza-Cruz M, Cabrera N, Crippa-Rossi M, Sosa Cabrera T, Perez-Montfort R, Becker I. Polymorphism analysis of the internal transcribed spacer and small subunit of ribosomal RNA genes of *Leishmania mexicana*. *Parasitol Res* **2002**; 88:918–25.
 20. Molina R, Gradoni L, Alvar J. HIV and the transmission of *Leishmania*. *Ann Trop Med Parasitol* **2003**; 97(Suppl 1):29–45.
 21. Choi CM, Lerner EA. Leishmaniasis: recognition and management with a focus on the immunocompromised patient. *Am J Clin Dermatol* **2002**; 3:91–105.
 22. Ribera E, Ocana I, de Otero J, Cortes E, Gasser I, Pahissa A. Prophylaxis of visceral leishmaniasis in human immunodeficiency virus-infected patients. *Am J Med* **1996**; 100:496–501.
 23. Laguna F. Treatment of leishmaniasis in HIV-positive patients. *Ann Trop Med Parasitol* **2003**; 97(Suppl 1):135–42.