

LETTER TO THE EDITOR

Primary retinal pathology in multiple sclerosis as detected by optical coherence tomography

A. U. Brandt,¹ T. Oberwahrenbrock,¹ M. Ringelstein,² K. L. Young,³ M. Tiede,³ H. P. Hartung,² R. Martin,^{3,4} O. Aktas,² F. Paul^{1,*} and S. Schippling^{3,*}

1 NeuroCure Clinical Research Centre and Experimental and Clinical Research Centre, Charité University Medicine Berlin and Max Delbrueck Centre for Molecular Medicine Berlin, 10117 Berlin, Germany

2 Department of Neurology, University Medical Centre Düsseldorf, Heinrich-Heine University Düsseldorf, 40225 Düsseldorf, Germany

3 Institute for Neuroimmunology and Clinical Multiple Sclerosis Research (inims), Department of Neurology, University Medical Centre Hamburg Eppendorf, 20246 Hamburg, Germany

4 Neurology Clinic, Department of Clinical Neuroimmunology and Multiple Sclerosis Research, University Hospital Zürich, CH-8091 Zürich, Switzerland

*These authors contributed equally to this work.

Correspondence to: Dr Sven Schippling,
Institute for Neuroimmunology and Clinical Multiple Sclerosis Research (INIIMS),
Department of Neurology,
University Hospital Hamburg Eppendorf,
Martinistrasse 52,
20246 Hamburg, Germany
E-mail: s.schippling@uke.de

Sir, We read the recent *Brain* publication by Saidha *et al.* (2011) with great interest. In their manuscript, the authors suggested that primary retinal pathology detectable by optical coherence tomography (OCT) defines a subset of patients with multiple sclerosis (Saidha *et al.*, 2011). This subgroup of patients, which they termed 'macular thinning predominant phenotype', was reported to exist in ~10% of the entire multiple sclerosis cohort examined by spectral domain OCT (Cirrus) at the authors' centres. The macular thinning predominant OCT phenotype was defined by a combination of average macular thickness below the 5th percentile, with ipsilateral normal average retinal nerve fibre layer (RNFL) thicknesses (between the 5th and 95th percentiles of RNFL values from the manufacturer's normative database), in one or both eyes, in the absence of a history of acute optic neuritis in affected eyes (Saidha *et al.*, 2011). Sixty-two per cent (31/50) of patients fulfilling the macular thinning predominant OCT criteria had a macular thickness below the 1st percentile. In addition, there was a remarkable male preponderance among patients with the macular thinning predominant phenotype (70% male versus 30% female), a difference that was even more pronounced (77.4% male versus 22.6% female) among those patients with very low macular

thicknesses (<1st percentile). These *in vivo* findings are in line with a recent post-mortem analysis reporting retinal pathology in multiple sclerosis beyond damage to the RNFL and the ganglion cell layer (Green *et al.*, 2010). These data are intriguing in that they point to a novel concept of primary retinal damage in multiple sclerosis. They indicate that retinal pathology might not only develop as a consequence of inflammatory attacks to the anterior optic pathway causing retrograde axonal and neuronal degeneration with RNFL thinning and retinal ganglion cell loss, but that the retina itself may be a primary target of degenerative or inflammatory processes. Together with a more rapid disease progression in the macular thinning predominant group reported by Saidha *et al.* (2011), these findings would have substantial impact not only on our understanding of multiple sclerosis disease pathogenesis and heterogeneity, but also on patient counselling. Therefore, independent confirmation or refutation of these results is warranted.

Against this background, we analysed our datasets from a large cohort of 370 patients with multiple sclerosis [262 relapsing remitting multiple sclerosis, 61 secondary progressive multiple sclerosis, 36 primary progressive multiple sclerosis and 11 patients with

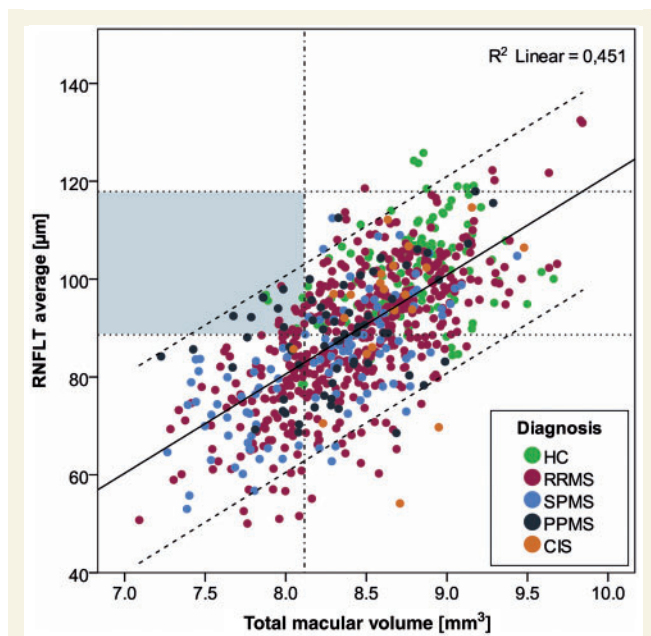


Figure 1 Scatterplot of total macular volume versus average retinal nerve fibre layer thickness (RNFLT) of all eyes. The colour depicts the diagnosis. The grey area represents the proposed macular thinning predominant position. Solid black line = linear regression analysis with $R^2 = 0.451$; slashed lines = 95% confidence intervals; dotted lines: 5th and 95th percentiles of RNFLT; slashed/dotted line = 5th percentile of total macular volume. CIS = clinically isolated syndrome; HC = healthy controls; PPMS = primary progressive multiple sclerosis; RRMS = relapsing remitting multiple sclerosis; SPMS = secondary progressive multiple sclerosis.

clinically isolated syndrome, aged 42 ± 12 years, 68/32% female/male, disease duration 267 ± 188 months, Expanded Disability Status Scale (EDSS) median 2.5 (range 0.0–8.0) and 71 healthy controls (age 33 ± 10 years, 63/37% female/male), investigated with a latest generation spectral domain OCT system (Spectralis OCT) at three large academic multiple sclerosis centres in Germany (Berlin, Düsseldorf, Hamburg) and examined whether the proposed macular thinning predominant phenotype and its frequency were also observed in our cohort. Patients had been investigated by OCT during clinical studies or attended our outpatient clinics for clinical assessment and counselling. When plotting total macular volume against RNFL thickness (Fig. 1), we were initially not able to visually discriminate the phenotype described by Saidha *et al.* (2011) as a distinct subgroup of patients. We would expect a macular thinning predominant phenotype with primary retinal pathology to unmask itself in the scatterplot as a distinct cluster. This was not the case in our data. We did, however, identify 21 multiple sclerosis eyes from 17 patients [4.6% of our cohort, mean age 43 ± 10 years, 10/7 female/male, disease duration 285 ± 152 months, EDSS median 2.5 (range 0.0–7.0)] with an RNFL thickness between the 5th (88.2 μm) and the 95th percentile (118.5 μm) and a total macular volume below the 5th percentile (8.112 mm^3), thus formally fulfilling the macular thinning predominant phenotype definition

given by Saidha *et al.* (2011). Eight patients with relapsing remitting multiple sclerosis were affected with one eye, three patients with both eyes; five patients with primary progressive multiple sclerosis were affected single sided, one patient in both eyes. However, all eyes fulfilling the macular thinning predominant phenotype definition were visually unambiguously located within the general data distribution and did not stand out as outliers (Fig. 1). Interestingly, 35.3% (6/17) of our patients fulfilling the macular thinning predominant criteria were patients with primary progressive multiple sclerosis, in contrast to Saidha *et al.* (2011), who did not find the macular thinning predominant phenotype among their primary progressive multiple sclerosis cohort, which led to an exclusion of this subgroup. Four patients with primary progressive multiple sclerosis also provided the four eyes below the 1st percentile of the healthy control total macular volume. Finally and important to note, our analysis revealed a frequency of the macular thinning predominant phenotype in the control group similar to the one we describe for our multiple sclerosis cohort (five eyes from three control subjects; $3/71 = 4.2\%$).

Therefore, although we also found patients fulfilling the macular thinning predominant phenotype definition, albeit at considerably lower frequency than Saidha *et al.* (2011), our results do not support the conclusion of a distinct macular thinning predominant OCT phenotype in multiple sclerosis. Based on our observations in a similarly sized cohort, which showed that eyes fulfilling macular thinning predominant phenotype criteria are found in relapsing remitting multiple sclerosis at a typical female to male ratio, in primary progressive multiple sclerosis, and in healthy controls, we assume that the respective data points are likely to represent the margins of an otherwise normal distribution.

The results by Saidha *et al.* (2011) might have been influenced by the *a priori* grouping of patients according to their position in relation to an internal Cirrus OCT normative database, consisting of 284 subjects with an age range of 18–84 years (mean age 46.5 years). As a consequence, this might imply distinct subtypes by artificially clustering the outer bounds of normally distributed data, when in reality, no clusters exist. Thus, a comparison of our scatterplot with that of Saidha *et al.* (2011) would be of interest.

On the other hand, technical and methodological differences between our investigations and those of Saidha *et al.* (2011) require a cautious comparison and interpretation of the data. We used a different spectral domain OCT device, Spectralis, which measures macular volume using multiple repeats for single line scans to reduce image noise, thus providing potentially better imaging quality than the Cirrus OCT device used by Saidha *et al.* (2011). Besides this difference in scanning technique, segmentation algorithm differences might further influence results. Patients displaying the macular thinning predominant phenotype, when measured with Cirrus OCT, could be re-evaluated with Spectralis OCT to determine whether differences in instruments and scanning methodologies might be of importance.

Moreover, differences in patient cohorts may play a role. While the study by Saidha *et al.* (2011) included American patients with multiple sclerosis, our study comprised entirely German patients with multiple sclerosis.

An intriguing finding by itself, however, is the retinal pathology in multiple sclerosis, which stands independently of the existence

of the suggested macular thinning predominant phenotype detectable by OCT. For the Spectralis OCT, an intraretinal segmentation algorithm is not yet available, and we were not able to provide segmentation data, which is a clear methodological limitation of our analysis. Thus, it will be of great interest to re-evaluate a possible intraretinal pathology in our data when an algorithm becomes available.

In summary, although the OCT data on primary retinal pathology in multiple sclerosis are compelling, they require further investigation in order to clarify the discrepancies between our study and that of Saidha *et al.* (2011). In particular, prospective studies, which are designed and powered to investigate the existence and the proportion of the postulated macular thinning predominant phenotype in multiple sclerosis cohorts versus controls and a re-consideration of the macular thinning predominant definition itself, are necessary.

Funding

The inims is supported by an unrestricted grant from the “Gemeinnützige Hertie-Stiftung”. This work was supported by the German Research Foundation (DFG exc 257 to FP).

References

- Green AJ, McQuaid S, Hauser SL, Allen IV, Lyness R. Ocular pathology in multiple sclerosis: retinal atrophy and inflammation irrespective of disease duration. *Brain* 2010; 133: 1591–601.
- Saidha S, Syc SB, Ibrahim MA, Eckstein C, Warner CV, Farrell SK, et al. Primary retinal pathology in multiple sclerosis as detected by optical coherence tomography. *Brain* 2011; 134: 518–33.