

Rheumatology 2013;52:954–956
 doi:10.1093/rheumatology/kes276
 Advance Access publication 26 October 2012

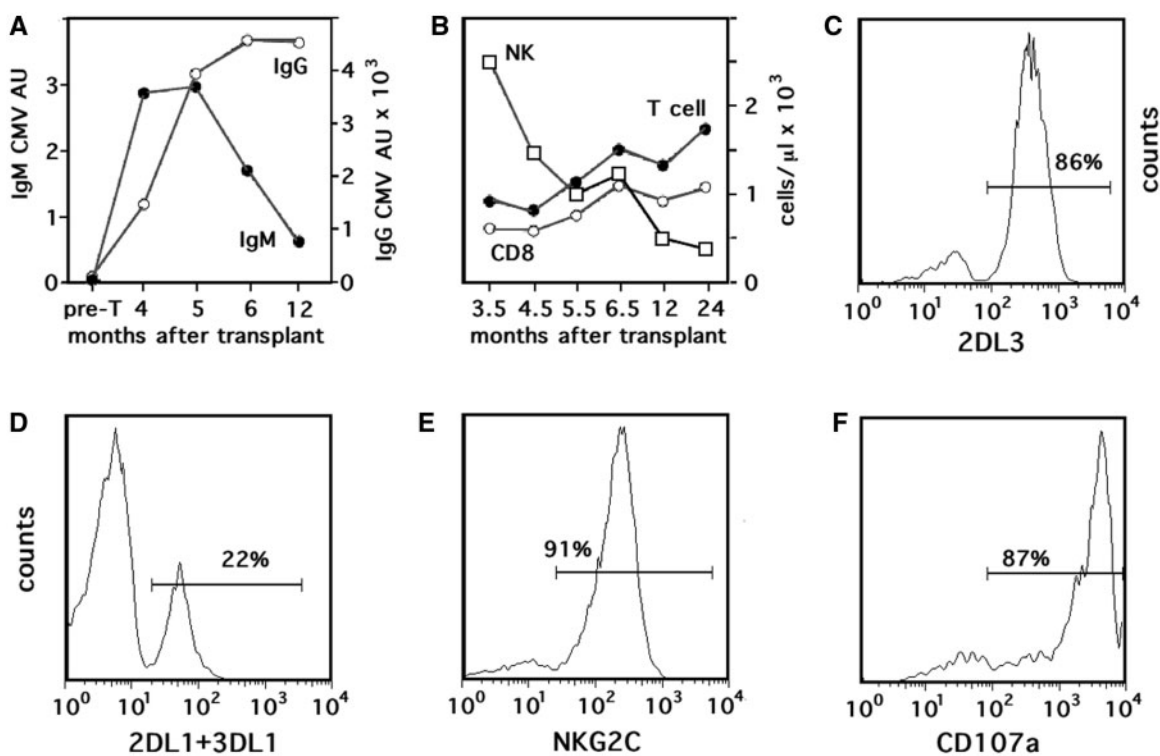
Acute natural killer cell pneumonia in a patient transplanted with autologous haematopoietic stem cells for systemic sclerosis

SIR, We present here a case of a 31-year-old woman referred to us for RP with migratory arthralgias, development of puffy fingers and subsequent fast, progressive centripetal skin thickening. Based on the clinical presentation and the presence of anti-topoisomerase-1 antibodies, she was diagnosed with SSc with diffuse cutaneous involvement reaching a modified Rodnan skin score of 33/51 despite treatment with low-dose prednisone (5 mg/day) and oral methotrexate (17.5 mg/week) followed by three pulses of i.v. cyclophosphamide (15 mg/kg, total dose 3.3 g). Although the high-resolution CT scan of the lung and a cardiac echo Doppler showed no abnormalities, the diffusing capacity of the lung for carbon monoxide (DL_{CO}) was 4.6 mmol/kPa min (54% of the predicted value) and the bronchoalveolar lavage fluid (BALF) contained many inflammatory cells. We enrolled the patient

in a clinical trial organized by the Autologous Stem cell Transplantation International Scleroderma group [1] and she was randomized into the arm of patients receiving high-dose cyclophosphamide followed by autologous haematopoietic stem cell transplantation (aHSCT) for rescue of haematopoiesis. During the first 3 months, the clinical course was uneventful. She then developed a rapidly worsening dyspnoea (upto NYHA class 3), with dry cough, fever and myalgia under CMV prophylaxis with valacyclovir 500 mg/b.i.d. Blood gas analysis demonstrated hypoxaemia and hypercapnia while breathing air. The HRCT scan of the thorax was consistent with diffuse ground-glass attenuation. Although the patient never suffered from CMV viraemia, we did detect CMV in BALF cultures (but no *Mycobacterium tuberculosis*, *Legionella pneumophila*, other Gram-positive or -negative bacteria or sequels of cytopathic viruses by microscopy). The kinetics of CMV-specific antibodies in the patient's serum (Fig. 1A) strongly suggested that the exposure to CMV had occurred not long before the onset of the symptoms.

The BALF contained high numbers of leucocytes (8.6×10^5 cells/ml) comprising predominantly macrophages (40%) and lymphocytes (57%), half of which

Fig. 1 Humoral and cellular immune responses during and after CMV-P.



Anti-CMV antibodies in arbitrary units (A). NK cells ($CD3^-CD56^+$ lymphocytes), T cells and $CD8^+$ T cells in peripheral blood (B). Expression of KIR2DL3 on NK cells (C), expression of KIR2DL1 and/or KIR3DL1 on KIR2DL3⁺ NK cells (D), expression of NKG2C (E) and K562-induced degranulation (CD107a expression) by single KIR2DL3⁺ NK cells during CMV-P (F). FACS data are gated using forward and side scatter gates of viable lymphocytes and gates on either $CD3^-CD56^+$ lymphocytes (C) or on $CD3^-CD56^+KIR2DL3^+$ lymphocytes (D–F). For further methods and reagents, see ref. [9]. Pre T: pre-transplant.

consisted of NK cells. During the first 5 months after pneumonitis, (CD56^{dim}CD16⁺) NK cells were also very abundant in peripheral blood where they outnumbered the (predominantly CD8⁺) T cells (Fig. 1B). Most NK cells expressed the inhibitory KIR2DL3 receptor and were negative for the other two inhibitory killer inhibitory receptors (KIRs) (KIR2DL1, KIR3DL1) (Fig. 1C and D). Virtually all single-KIR2DL3⁺ cells expressed the activating killer cell receptor NKG2C (Fig. 1E) associated with anti-CMV responses [2, 3]. Stimulation with NK cell target cells (K562) induced a strong NK cell degranulation (CD107a-expression, Fig. 1F). Hence, the clinical condition of the patient was associated with the expansion of highly cytotoxic NKG2C⁺ NK cells expressing only the moderately [4] inhibitory KIR2DL3. With time, the patient's clinical condition improved and the number of NK cells normalized. After 2 years, KIR2DL3-single positive represented no more than 35% of total and displayed considerably less cytotoxicity than at the peak of disease (data not shown).

aHSCT may be beneficial to patients suffering from autoimmune diseases such as SSc [1]. CMV-associated pneumonia (CMV-P) is frequent after lung transplantation [5] and in patients suffering from graft-vs-host disease after allogeneic HSCT but less so after aHSCT [6]. It is still under debate whether the pathogenesis of CMV-P is owed to the cytopathic effect of the virus or to the immune response it elicits [6, 7]. The fact that severity of CMV-P is not correlated with the level of viraemia and treatment with anti-viral drugs does not resolve its symptoms [6, 7] or that post-transplant CMV-P occurs mainly during the first 2 months when activated lymphocytes accumulate in the lungs [7] and that symptoms are much more severe when these cells attack patient's tissues during graft-vs-host disease argues for the latter.

However, others stress that T cells are unlikely to be the harmful component of the pathogenesis of CMV-P because T-cell recovery after HSCT is slow and CMV-P is at least as frequent in recipients of T-cell-depleted grafts [6]. Still, this reasoning may not fully acknowledge the role of NK cells in pulmonary infections [8]. NK cells recover very early after transplantation and may recover even faster in patients with low numbers of T cells [9]. Furthermore, NK cells may represent the major lymphocyte population in BALF of patients with CMV-P (reviewed in [6]). Our patient with CMV-P had high numbers of NK cells in BALF as well as in peripheral blood that had expanded just before anti-CMV IgG titres started to rise. We believe that these only moderately inhibited NK cells had responded to CMV because the majority was highly cytotoxic and expressed a single self-specific KIR in combination with NKG2C, which are all typical features of NK cells producing IFN- γ during acute CMV reactivation [2, 3].

Our findings support the immunopathological model and give support to the hypothesis that CMV-P is, at least in part, caused by hyper-reactive NK cells. Furthermore, NK cell abnormalities associated with SSc

interstitial lung disease may play a role in these settings [10]. Our patient may not be an isolated example and may show that patients receiving aHSCT to cure SSc are at risk for NK cell-induced CMV-P.

Rheumatology key message

- CMV-P after aHSCT may be caused by NK cells in patients with SSc interstitial lung disease.

Acknowledgements

We thank Dr J.-M. Tiercy (Transplantation Immunology, Geneva University Hospital, Geneva, Switzerland) for KIR genotyping. E.R. is supported by a grant of the Swiss National Science Foundation (310030-127516) and by the 'Dr Henri Dubois-Ferrière-Dinu Lipatti' Foundation. C.C. is supported by the Swiss National Science Foundation grant (310030-140791).

Disclosure statement: The authors have declared no conflicts of interest.

**Carlo Chizzolini¹, Marija Vukicevic²,
Thierry Rochat³, Alan Tyndall⁴ and Eddy Roosnek²**

¹Immunology and Allergy, ²Hematology, ³Pneumology, University Hospital and School of Medicine, Geneva and ⁴Felix Platter Hospital, Basel University, Basel, Switzerland.

Accepted 11 September 2012

Correspondence to: Carlo Chizzolini, Immunology and Allergy, Geneva University Hospital, 1211 Geneva 14, Switzerland. E-mail: carlo.chizzolini@unige.ch

References

- 1 van Laar JM, Farge D, Tyndall A. Autologous Stem cell Transplantation International Scleroderma (ASTIS) trial: hope on the horizon for patients with severe systemic sclerosis. *Ann Rheum Dis* 2005;64:1515.
- 2 Guma M, Angulo A, Vilches C, Gomez-Lozano N, Malats N, Lopez-Botet M. Imprint of human cytomegalovirus infection on the NK cell receptor repertoire. *Blood* 2004;104:3664.
- 3 Foley B, Cooley S, Verneris MR *et al.* Cytomegalovirus reactivation after allogeneic transplantation promotes a lasting increase in educated NKG2C⁺ natural killer cells with potent function. *Blood* 2011;119:2665.
- 4 Parham P. MHC class I molecules and KIRs in human history, health and survival. *Nat Rev Immunol* 2005;5:201-14.
- 5 Zamora MR. DNA viruses (CMV, EBV, and the herpesviruses). *Semin Respir Crit Care Med* 2011;32:454-70.
- 6 Barry SM, Johnson MA, Janossy G. Cytopathology or immunopathology? The puzzle of cytomegalovirus pneumonitis revisited. *Bone Marrow Transplant* 2000;26:591-7.
- 7 Grundy JE, Shanley JD, Griffiths PD. Is cytomegalovirus interstitial pneumonitis in transplant recipients an immunopathological condition? *Lancet* 1987;2:996-9.
- 8 Culley FJ. Natural killer cells in infection and inflammation of the lung. *Immunology* 2009;128:151-63.

- 9 Vukicevic M, Chalandon Y, Helg C *et al.* CD56-bright NK cells after hematopoietic stem cell transplantation are activated mature NK cells that expand in patients with low numbers of T cells. *Eur J Immunol* 2010;40: 3246–54.
- 10 Horikawa M, Hasegawa M, Komura K *et al.* Abnormal natural killer cell function in systemic sclerosis: altered cytokine production and defective killing activity. *J Invest Dermatol* 2005;125:731–7.

Rheumatology 2013;52:956–958

doi:10.1093/rheumatology/kes299

Advance Access publication 30 October 2012

Remission of juvenile idiopathic arthritis with primary Epstein–Barr virus infection

SIR, JIA is the most common chronic rheumatic inflammatory disorder in children, and causes acquired disability and impairment of quality of life [1]. Previous reports have shown transient or prolonged remission of JIA following viral infections such as measles and varicella zoster virus [2, 3]. Here we report three cases of JIA who experienced remission associated with primary EBV infection. Serum concentrations of cytokines of these patients suggest that the Th1 response induced by EBV might have contributed to their remission.

Case 1, a 3-year-old boy, was diagnosed with RF-negative, ANA-positive oligoarthritis of JIA. He had been treated with flurbiprofen, MTX 10 mg/m²/week and prednisolone (PSL) 0.2 mg/kg/day, but he continued to have mildly active arthritis. Ten months after presentation, he developed fever and tonsillitis. Laboratory studies revealed a white blood count (WBC) of 7840/μl with 8% atypical lymphocytes, and EBV infection was serologically confirmed. With the development of infectious mononucleosis (IM), MTX was discontinued. Symptoms of IM were mild, and he recovered from fever in several days. His left knee joint swelling diminished within several weeks after the onset of IM. During the 2 years of follow-up, he has remained in remission despite withdrawal of MTX and PSL (Fig. 1).

Case 2, a 1-year-old girl, was diagnosed with RF-negative polyarthritis of JIA. She had been treated with flurbiprofen, PSL 0.2 mg/kg/day and MTX 10 mg/m²/week. Arthritis improved with treatment, but recurrent episodes of active arthritis associated with tapering of PSL were observed. At 8 years of age, she developed low-grade fever and tonsillitis. Laboratory studies revealed WBC of 15 800/μl with 4% atypical lymphocytes, and EBV infection was serologically confirmed. High EBV load (>5000 copies/ml) remained detectable until 17 months after EBV infection. MTX was discontinued with the development of IM, but her joint swelling diminished within 3 months after the onset of IM. During the 18 months of follow-up, she has remained in remission (Fig. 1).

Case 3, a 3-year-old girl, was diagnosed with RF-negative, ANA-positive oligoarthritis of JIA. She had

been treated with flurbiprofen, MTX 8 mg/m²/week and PSL 0.3 mg/kg/day, but she continued to have mildly active arthritis for 3 years. At 7 years of age, lymphadenopathy and elevation of aminotransferase levels were discovered during a routine hospital visit. Laboratory studies revealed WBC of 5790/μl without atypical lymphocytes and aspartate aminotransferase of 114 IU/l. EBV infection was serologically confirmed. MTX was discontinued, but her arthritis improved gradually and diminished within 3 months after the onset of EBV infection. She has remained in remission during 3 years of follow-up (Fig. 1).

The serum concentrations of IFN-γ, IL-1β, IL-6, IL-17 and IL-23 were examined by ELISA. In all three patients, concentrations of IFN-γ were elevated in accordance with the onset of IM. In patients 1 and 2, concentrations of IL-17 decreased around the onset of IM and remained in the normal range thereafter. In patient 3, concentrations of IL-17 were not elevated at 2 months prior to EBV infection, but cytokines could not be measured at further time points because serum samples were not available (Fig. 1). IL-1β, IL-6 and IL-23 were not elevated in any serum samples.

Because MTX is widely used for treatment of JIA, it would not be rare for JIA patients receiving MTX to develop primary EBV infection. In our cases, MTX was discontinued when EBV infection was suspected because MTX might aggravate the EBV infection via its immunosuppressive effects [4]. Although these patients had been refractory to MTX, and had mildly active arthritis at the onset of EBV infection, they did not show exacerbation of articular symptoms and attained remission without MTX. Concentrations of MMP-3, which is a useful marker of disease activity in JIA, decreased to normal range at onset of EBV infection or within several months in all patients [5].

It has been previously hypothesized that auto-inflammatory arthritis is associated with a Th1 polarized response at the site of inflammation. However, Th17 cells with pro-inflammatory actions are thought to be critical to the pathogenesis of CIA, as demonstrated in a murine model [6]. Recent evidence suggests that Th17 cells, rather than Th1 cells, may be central to disease pathogenesis of RA and JIA [7]. Differentiation and stabilization of Th17 cells depends on a range of cytokines, including IL-6 and IL-23. On the other hand, IFN-γ produced by Th1 cells inhibits the Th17 pathway [6]. It is possible that the Th1 response induced by EBV infection contributed to the remission of JIA, because primary EBV infection strongly induces IFN-γ production of CD8⁺ T cells [8]. Understanding the immunological effect of remission of JIA with viral infections may provide insights into designing more effective therapies for JIA.

Rheumatology key message

- JIA patients who were refractory to MTX treatment showed remission after primary EBV infection.