

Cite this article as: Shrestha M, Bachet J, Bavaria J, Carrel TP, De Paulis R, Di Bartolomeo R *et al.* Current status and recommendations for use of the frozen elephant trunk technique: a position paper by the Vascular Domain of EACTS. *Eur J Cardiothorac Surg* 2015;47:759–69.



Current status and recommendations for use of the frozen elephant trunk technique: a position paper by the Vascular Domain of EACTS[†]

Malakh Shrestha^a, Jean Bachet^b, Joseph Bavaria^c, Thierry P. Carrel^d, Ruggero De Paulis^e,
Roberto Di Bartolomeo^f, Christian D. Etz^g, Martin Grabenwöger^h, Michael Grimmⁱ, Axel Haverich^a,
Heinz Jakob^j, Andreas Martens^a, Carlos A. Mestres^{k,l}, Davide Paciniⁱ, Tim Resch^m, Marc Schepensⁿ,
Paul P. Urbanski^o and Martin Czerny^{p,q,*}

^a Department of Cardio-thoracic, Transplantation and Vascular Surgery, Hannover Medical School, Hannover, Germany

^b Nogent sur Marne, Paris, France

^c Division of Cardiovascular Surgery, Hospital of the University of Pennsylvania, PA, USA

^d Clinic for Cardiovascular Surgery, University Hospital Berne, Berne, Switzerland

^e Cardiac Surgery Department, European Hospital, Rome, Italy

^f Department of Cardiac Surgery, S. Orsola-Malpighi Hospital, Bologna, Italy

^g Department of Cardiac Surgery, Heart Center Leipzig, Leipzig, Germany

^h Department of Cardiovascular Surgery, Hospital Hietzing, Vienna, Austria

ⁱ Department of Cardiac Surgery, Medical University Innsbruck, Innsbruck, Austria

^j Department of Thoracic & Cardiovascular Surgery, University of Essen West German Heart Center, Essen, Germany

^k Department of Cardiovascular Surgery, Hospital Clinic, Barcelona, Spain

^l Heart and Vascular Institute, Cleveland Clinic, Abu Dhabi, United Arab Emirates

^m Department of Vascular Surgery, Malmö University Hospital, Malmö, Sweden

ⁿ AZ St. Jan, Brugge, Belgium

^o Cardiovascular Clinic, Bad Neustadt, Germany

^p Department of Cardiovascular Surgery, University Hospital Zurich, Zurich, Switzerland

^q University Heart Center Freiburg-Bad Krozingen, Freiburg, Germany

* Corresponding author. Hugstetterstrasse 55, 79106 Freiburg, Germany. Tel: +49-761-27028180; fax: +49-761-27025500; e-mail: martin.czerny@uniklinik-freiburg.de (M. Czerny).

Received 14 December 2014; received in revised form 4 January 2015; accepted 2 February 2015

Abstract

The implementation of new surgical techniques offers chances but carries risks. Usually, several years pass before a critical appraisal and a balanced opinion of a new treatment method are available and rely on the evidence from the literature and expert's opinion. The frozen elephant trunk (FET) technique has been increasingly used to treat complex pathologies of the aortic arch and the descending aorta, but there still is an ongoing discussion within the surgical community about the optimal indications. This paper represents a common effort of the Vascular Domain of EACTS together with several surgeons with particular expertise in aortic surgery, and summarizes the current knowledge and the state of the art about the FET technique. The majority of the information about the FET technique has been extracted from 97 focused publications already available in the PubMed database (cohort studies, case reports, reviews, small series, meta-analyses and best evidence topics) published in English.

Keywords: Frozen elephant trunk technique • Thoracic aortic pathology • Combined treatment

INTRODUCTION

A complex thoracic aortic pathology requires a simplified solution. The conventional elephant trunk technique was introduced in 1983 and thereafter performed in a significant number of patients worldwide (Fig. 1). Later on, thoracic endovascular aortic repair (TEVAR) broadened the armamentarium of the aortic surgeon to treat several acute and chronic thoracic aortic diseases mainly located in the distal aortic arch or in the descending aorta [1–4]. The logical

consequence was to bring both techniques (open surgery and endovascular techniques) closer together to create a common platform for a combined treatment, also called the 'hybrid' approach of complex thoracic aortic pathology. As a step between the conventional elephant trunk (cET) technique and the so-called frozen elephant trunk (FET) technique, the combination of varying extents of aortic arch replacement and antegrade TEVAR was practised until a combined prosthesis became available (Fig. 2) [5, 6].

Following initial reports from Suto and Kato with home-made combined grafts, the FET technique was popularized by Usui and Karck, and is currently used to treat a variety of acute and chronic thoracic pathologies (Fig. 3) [7–11].

[†] Presented at the 28th Annual Meeting of the European Association for Cardio-Thoracic Surgery, Milan, Italy, 11–15 October 2014.

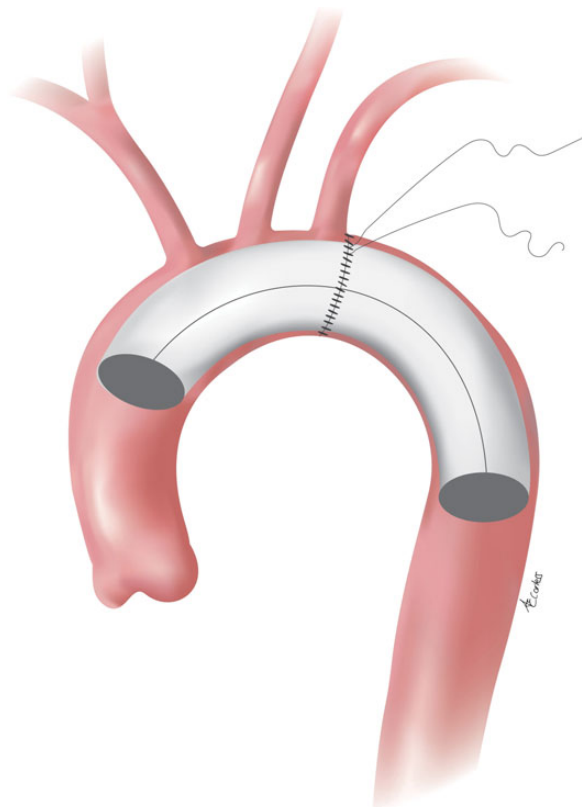


Figure 1: Conventional elephant trunk technique.

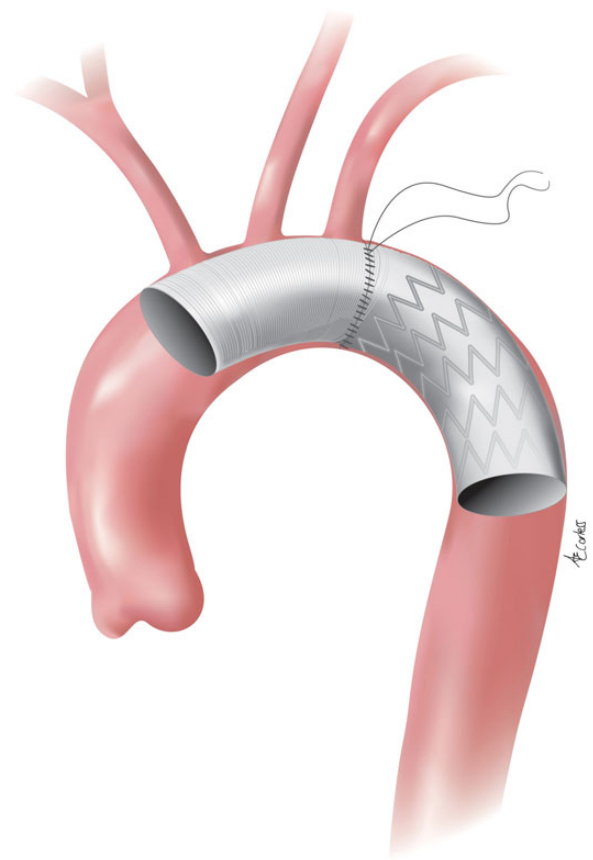


Figure 3: Frozen elephant trunk technique.

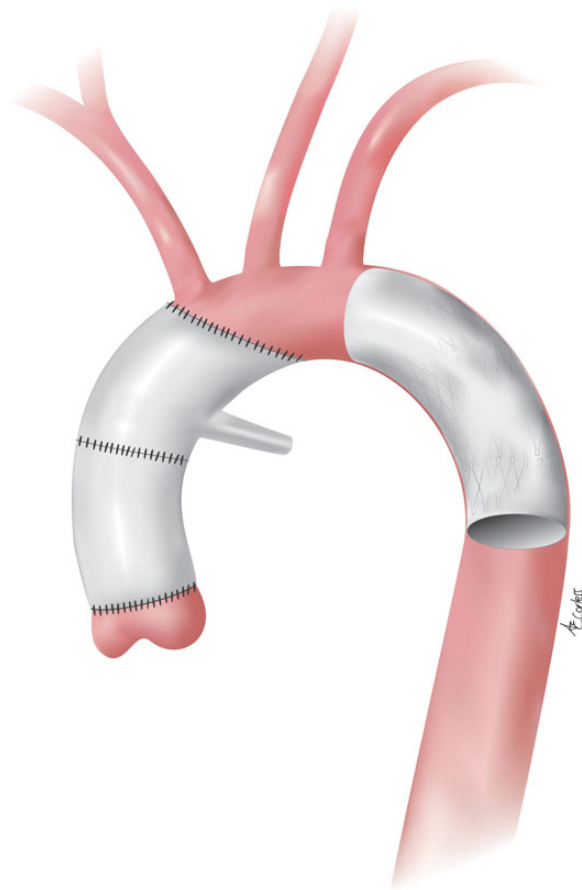


Figure 2: Hemiarch replacement with antegrade TEVAR. TEVAR: thoracic endovascular aortic repair.

METHODS

Sources of information

Information on the FET technique have been extracted from 97 focused publications available in the PubMed database. Some of these are cohort studies ($N = 55$), case reports ($N = 19$), reviews ($N = 10$) and short series ($N = 4$), whereas others are meta-analyses ($N = 2$) and best evidence topics (BET = 2) published in English. Furthermore, four editorial commentaries have been collected as they were requested by the journal Editors with regard to specific submissions on the FET technique. One submission was published as a letter to the Editor. The published articles include the majority of patient cohorts available so far. The two available meta-analyses included 2991 patients [12, 13]. A BET covered two studies that included 230 cases [14]. Case reports, short series and other articles take into account for over 4500 patients operated on using the FET concept. Reports with less than 25 cases have been excluded. Finally, 40 studies include the vast majority of the information published until now. It is to be noted that some of these articles are sequential publications from some centres, and may include patients from different eras [15–53]. We support the recommendations for formulating and issuing Guidelines and Expert Consensus Documents, which can be found on the European Society of Cardiology website (<http://www.escardio.org> and search for recommendations for guidelines production) (Tables 1 and 2).

Table 1: Classes of recommendation

	Definition	Suggested wording to use
Class I	Evidence and/or general agreement that a given treatment or procedure is beneficial, useful and effective	Is recommended/is indicated
Class II	Conflicting evidence and/or a divergence of opinion about the usefulness/efficacy of the given treatment or procedure	
Class IIa	Weight of evidence/opinion is in favour of usefulness/efficacy	Should be considered
Class IIb	Usefulness/efficacy is less well established by evidence/opinion	May be considered
Class III	Evidence or general agreement that the given treatment or procedure is not useful/effective and in some cases may be harmful	Is not recommended

Table 2: Levels of evidence

Level of evidence A	Data derived from multiple randomized clinical trials or meta-analyses
Level of evidence B	Data derived from a single randomized clinical trial or large non-randomized studies
Level of evidence C	Consensus of opinion of the experts and/small studies, retrospective studies, registries

Countries, authors and centres

Several publications have been written by same authors since experience and information on the FET technique have usually been produced by large-volume centres or those centres that pioneered the usage of the FET technique. The countries where information has been collected or drafted are the following: Germany ($N = 24$), Japan ($N = 20$), Italy ($N = 15$), China ($N = 12$), USA ($N = 7$), Austria ($N = 4$), Spain ($N = 4$), Greece ($N = 3$), UK ($N = 3$) and Australia, Belgium, Finland, France and Switzerland ($N = 1$ each).

The International E-Vita Open Registry (IEOR) is coordinated by the West German Heart Center in Essen (Germany) and collected cases from 11 centres of different European countries. It was instituted in 2006, and has produced the bulk of information on one of the devices used up to now. The IEOG Group has published six articles on the FET so far [23, 26, 28, 30, 31, 42]. The Collaborative Research (CORE) Group, coordinated from Sydney, Australia and the Attikon Hospital in Athens, Greece, have organized the two meta-analyses on the FET [12, 13].

Dissemination of information

The appropriately sized case series articles, meta-analyses and BETs have been published by the most prestigious peer-reviewed journals in the field of cardiothoracic surgery as follows: *European Journal of Cardiothoracic Surgery/Interactive Cardiovascular and Thoracic Surgery* (EJCTS/ICVTS— $N = 16$), *The Journal of Thoracic and Cardiovascular Surgery* (JTCVS— $N = 11$), *The Annals of Thoracic Surgery* (ATS— $N = 6$), *Annals of Cardiothoracic Surgery* (ACTS— $N = 6$), *The Journal of Cardiovascular Surgery* (JCVS— $N = 2$), *Annals of Thoracic and Cardiovascular Surgery* and *Multimedia Manual of Cardiothoracic Surgery* ($N = 1$ each).

RESULTS

Preoperative diagnoses

The FET technique has been used in different aortic pathologies, acute aortic dissection (Stanford Type A and B, DeBakey I), atherosclerotic arch, descending or thoraco-abdominal aneurysms and for other pathologies such as penetrating aortic ulcers.

The published contributions do often present a broad mix of diseases and it is not uncommon that authors refer simultaneously to 'aortic dissection' (either acute or chronic) when dealing with Types A and B. Intrathoracic aneurysms are also considered as an isolated condition including boundary territories such as the distal descending and thoraco-abdominal aorta. On the other hand, there were some publications dealing only with 'acute dissection', 'chronic dissection' and 'atherosclerotic aneurysm'.

Analysis of 40 series with more than 25 patients (range 25–803) shows that the diagnosis of chronic dissection was present in 6–73% of the cases in those papers in which all diagnostic categories were mixed. Acute aortic dissection was the initial pathology in 6–100% of the cases in articles dedicated to aortic dissection.

The diagnosis of Type B and retrograde Type A dissection has specifically been addressed in two contributions.

The frozen elephant trunk devices

Since the first conception of FET, a number of devices have been designed and used to achieve this complex procedure in one step. The first ones were home-made devices. Thereafter, several companies have participated to the further technological evolution and the following have been tested:

- (i) Gianturco Z-stent (Cook®, Inc., Bloomington, USA).
- (ii) Chavan-Haverich Prosthesis (Curative GmbH, Dresden, Germany).
- (iii) E-Vita Open and E-Vita Open Plus® (Jotec® GmbH, Hechingen, Germany).
- (iv) Cronus™ (MicroPort Medical Co., Ltd, Shanghai, China).
- (v) Thoraflex™ Hybrid Prosthesis (Vascutek®, Terumo®, Inchinnan, Scotland, UK).

The described clinical outcomes have apparently not been significantly different with regard to the device used.

Intraoperative details: complexity

In general, authors disclosed intraoperative details that are considered to give the reader an idea of the complexity of this type of surgery. It is well agreed that the FET technique is part of a complex and demanding procedure. This becomes evident when the duration of the operation, cardiopulmonary bypass time and the length of the period of cerebral perfusion are considered. Cardiopulmonary bypass and myocardial protection are well-established concepts that do not need further discussion. Hypothermic circulatory arrest together with cerebral protection (in the large majority of cases in an antegrade way) will not be discussed further. Surprisingly, the duration of lower body and abdominal ischaemia is usually not addressed. Rough data from the series published indicate that the following information are welcome:

- (i) Cardiopulmonary bypass.
- (ii) Cardiac ischaemia.
- (iii) Circulatory arrest (with/without antegrade cerebral perfusion).

Early postoperative complications

The most frequent postoperative complications refer to the need for postoperative re-exploration because of bleeding, stroke, spinal cord injury (SCI) and acute kidney injury (AKI) requiring dialysis. For the last three complications, either transient and permanent deficits or requirements are considered. They are summarized in Table 3.

The main problem with the description of postoperative outcomes is the lack of uniformity in reporting and the broad mix of complications. Aggregate outcomes (SCI–AKI) may give a better view of the complexity of the procedure on the general health condition of the patients.

The review of the available publications confirms that the major problem with the FET technique is SCI that includes paraplegia and paraparesis. There is no mention in any of the articles published so far about the diagnosis and evolution of paraparesis, which is supposed to be a less devastating step of SCI. It seems that SCI tends to happen preferentially in patients operated on for chronic dissection, but this finding is not easy to confirm due to the way it is reported in the different articles.

Follow-up

The major interest in reporting of follow-up concerns the evaluation of the patency of the false lumen in the case of dissection and complete exclusion without endoleaks after aneurysm repair. There are large differences in reporting follow-up timings. Other than 1-year survival, different teams report at different intervals

(3-, 4-, 5-, 8- and 10-year) according to the individual team experience. The average reported follow-up in months is 26.3 (range 3–104). There are only few data with a follow-up at 10 post-operative years. The average reported survival rates at 1, 3 and 5 years are 87, 78 and 68%, respectively.

The most beneficial effect of FET is the promotion of early false lumen thrombosis in patients treated because of acute aortic dissection. The average rate of early (<3 months) false lumen thrombosis at the level of the stent-graft as assessed by imaging techniques (computed tomography or magnetic resonance) is 85% (range 69–100%). Moreover, it increases to ~89% within 6–12 months after surgery. These data confirm that aortic remodelling starts immediately after surgery and progresses over time.

Secondary interventions

Since most series dealing with this topic merge open surgical and endovascular completion, it is difficult to extract objective information. On top of that, series encompass mixtures of pathologies (dissection versus non-dissection), variable extends of aneurysms (purely thoracic versus thoraco-abdominal) and mixtures of frozen and free-floating elephant trunks.

Limitations of reporting outcomes in the current literature

There are a number of limitations in reporting outcomes of the FET technique that are summarized as follows:

- (i) Individual institutional experiences.
- (ii) With few exceptions, every single contribution is a retrospective analysis of a departmental database.
- (iii) Retrospective design.
- (iv) Usually small size of the series (corresponds to the rarity of the pathology).
- (v) Lack of uniformity in surgical methodology.
- (vi) Lack of uniformity in reporting.
- (vii) Heterogeneity of populations (mostly based on age groups).
- (viii) Potential differences according to the device used.

DISCUSSION

The FET technique has broadened the armamentarium of surgeons and simplified the treatment of complex thoracic aortic pathologies. The conceptual strategy to obtain the most complete primary repair possible and to provide concomitant circumstances that facilitate any secondary future intervention is effective. However, this procedure may be performed at the cost of a significant adverse event that is a higher rate of SCI. Further

Table 3: Aggregate morbidity and mortality

Reop bleeding	Stroke	SCI (paraplegia + paraparesis)	AKI (aggregate transient + permanent dialysis)	Laryngeal nerve palsy	In-hospital mortality (30 days–no discharge)
2.5–30%	2.5–20%	0–21%	4–34.8%	0–12.8%	1.8–17.2%

SCI: spinal cord injury; AKI: acute kidney injury.

experience and research will better clarify the mechanisms of SCI and help to reduce its incidence.

Indications

It remains challenging to define robust indications for the FET technique and consequently recommendations for use. However, several preoperative diagnoses may apply for the technique.

Acute type A aortic dissection

There are most probably two main issues that should be considered when FET is used in acute type A aortic dissection being (i) FET may be an ideal technique to treat complications due to malperfusion since it helps to expand the true lumen in the proximal part of the descending aorta and thereby to close some of the communications between the lumina at this level and (ii) FET may help to prevent future events (mainly aneurysm formation in the

chronically dissected descending aorta). Visceral and renal malperfusion are frequently associated with an entry tear in the distal aortic arch or the proximal descending aorta [54]. Consequently, replacement of the ascending aorta with a distal anastomosis at the level of the proximal or mid-aortic arch will not re-establish regular antegrade flow conditions to resolve malperfusion due to true lumen compression. To achieve this result, more extensive repair is needed and the FET technique represents an ideal modality to fix the problem [55]. Figure 4 shows morphology in a case in which a primary entry tear in the proximal descending aorta is associated with visceral and renal malperfusion. Preventing post-dissection aneurysm formation is attractive as secondary surgical repair may be challenging and secondary endovascular repair is not always feasible. In acute type A aortic dissection, the indication to proceed with FET has to balance the risk of a more demanding procedure against the mid-term benefits of it. In this emergency situation, survival of the patient is the first and foremost important goal and a later operation under optimal conditions may carry a low risk when performed in an experienced aortic centre [23, 26, 28].

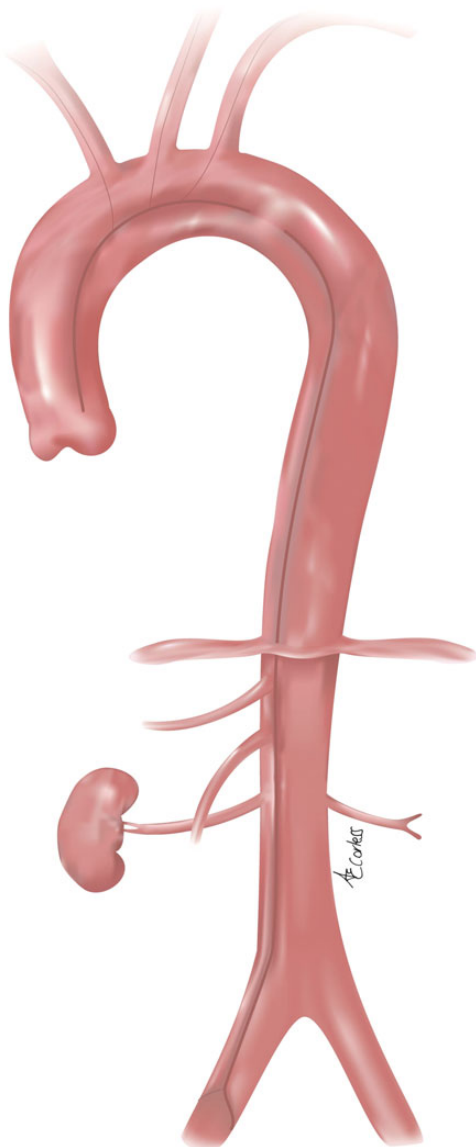


Figure 4: Primary entry tear in the proximal descending aorta associated with visceral and renal malperfusion.

Post-dissection aneurysmal formation after type A repair

The use of the FET technique is reported for the treatment of post-dissection aneurysmal formation after type A repair [21, 24, 30, 31]. In this case, the following aspects must be considered (i) the location of the segment with the maximal diameter—the more proximal, the higher the likelihood of effectiveness (ii) the size of the true lumen, which is often very narrowed because there is still a risk for pseudocoarctation after FET implantation. It should be the aim of future investigations to define the minimal size for the true lumen to avoid this complication. Furthermore, similar challenges may arise as in TEVAR for aneurysmal formation after type B aortic dissection, which is an incomplete expansion of the true lumen due to the rigidity of the dissection membrane, reperfusion of the false lumen from any distal communication between both lumina and membrane rupture at the distal end of the stent-graft due to counteracting forces between the self-expanding characteristic of the stent-graft and the relatively rigid chronic dissection membrane [56–58]. Figure 5 shows a scenario after ascending/hemiarch replacement where aneurysm formation occurred due to a persistently patent primary entry tear in the distal aortic arch amenable to the FET technique.

Acute type B aortic dissection

TEVAR is the treatment of first choice in patients with complicated acute type B aortic dissection, and recently has been recommended for patients with uncomplicated type B aortic dissection as well because TEVAR is associated with improved 5-year aortic-specific survival and delayed disease progression [59, 60]. However, the issue of retrograde type A aortic dissection remains unsolved and patients undergoing TEVAR for type B aortic dissection remain at a substantially increased risk. Factors associated with retrograde type A aortic dissection after TEVAR have been identified, but there is still a grey zone [61, 62]. Consequently, the FET technique represents an alternative to primary TEVAR and its effectiveness has already been reported [50]. Figure 6 shows morphology of a complicated type B aortic dissection where the FET technique

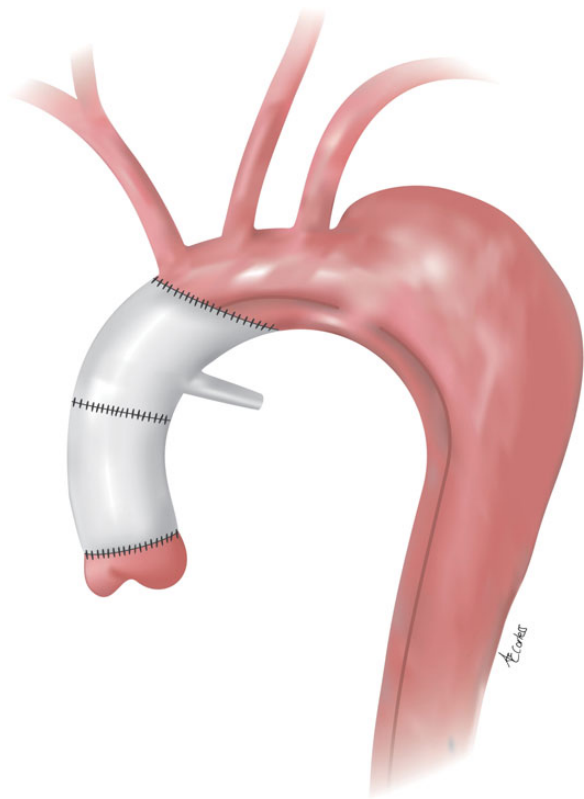


Figure 5: Scenario after ascending/hemiarch replacement with aneurysm formation due to a persistently patent primary entry tear in the distal aortic arch amendable to the FET technique.

should be considered when there is no landing zone for TEVAR, the aortic arch is dilated or the arch angulation is steep.

Post-dissection aneurysmal formation after chronic type B aortic dissection

In this category, similar principles apply as in acute type B aortic dissection where the challenges regarding long-term durability are similar to those after FET implantation for post-dissection aneurysmal formation after type A repair.

Thoracic aortic aneurysms

Any type of thoracic aortic aneurysm that otherwise would require a surgical two-step approach may qualify for the FET technique, but it remains a strategic choice if primary distal seal is intended or secondary retrograde TEVAR for completion is chosen in order to reduce the potential risk of symptomatic SCI by priming the collateral network [63]. FET qualifies for both, secondary open and endovascular repair because the nitinol frame of the stent-graft well tolerates clamping and resumes its natural configuration after declamping due to the inherent memory effect of the alloy [64].

Penetrating atherosclerotic ulcers/intramural haematomas

Also here the extent of the disease indicates the choice of the procedure. In particular, in patients with penetrating atherosclerotic

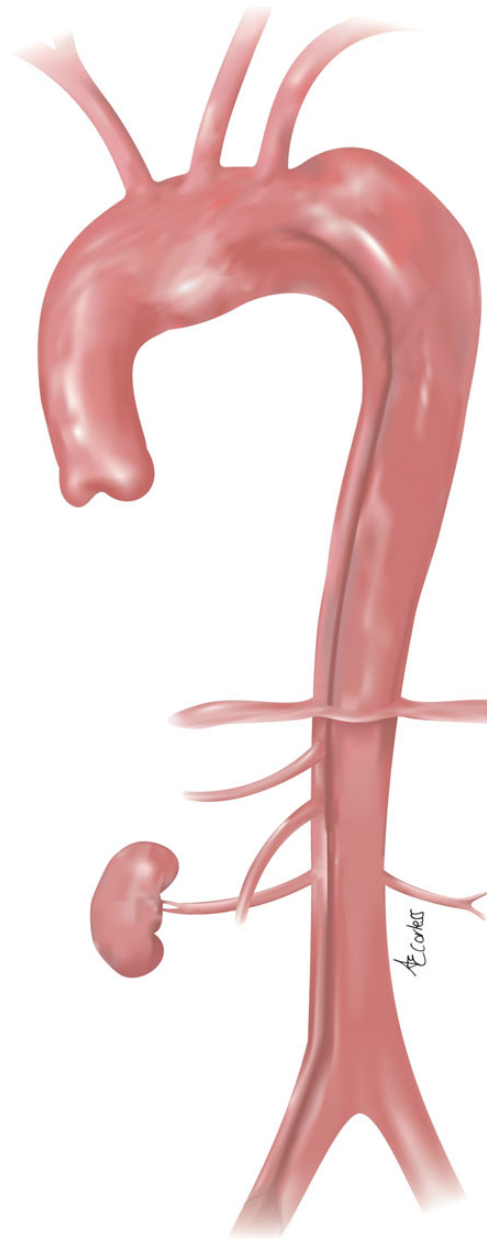


Figure 6: Complicated type B aortic dissection without a landing zone for TEVAR, due to an ectatic aortic arch suitable for the FET technique.

ulcers (PAUs) as an aggressive underlying obliterative disease process, have an increased risk of stroke and embolism and may be candidates for the FET procedure [65]. In patients with intramural haematoma of the entire thoracic aorta where an entry tear in the distal aortic arch or the descending aorta can be localized, the FET technique may serve as an ideal procedure to fix the entire thoracic aortic pathology [66]. Figure 7 shows a clinical case where multiple PAUs affect the entire thoracic aorta where the FET technique is applicable.

Devices currently used in Europe

Two devices are widely used in Europe: E-Vita Open and E-Vita Open Plus® (Jotec® GmbH, Hechingen, Germany) and the Thoraflex™

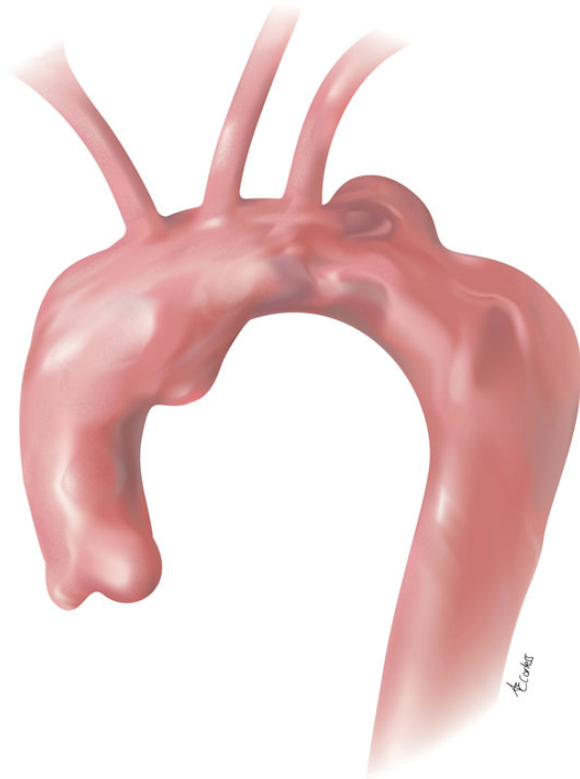

Figure 7: Multiple penetrating atherosclerotic ulcers (PAUs) affecting the entire thoracic aorta where the FET technique is applicable.

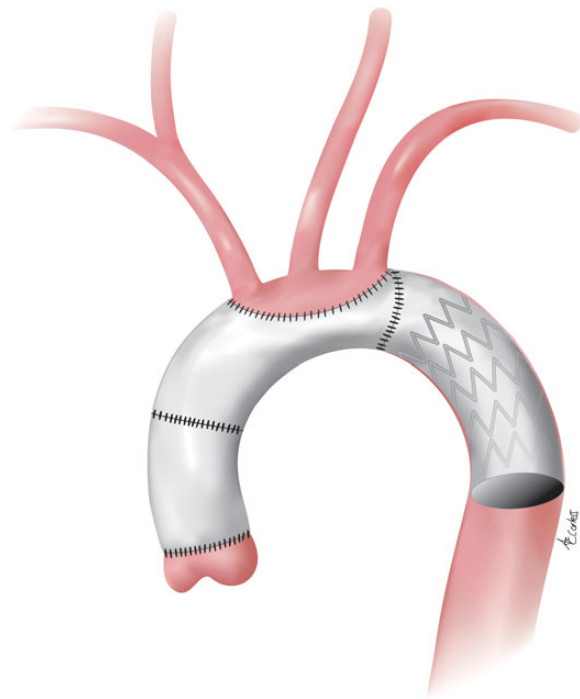


Figure 8: Scheme of frozen elephant trunk (FET) implantation with the Jotec device using an island technique when reimplanting the supra-aortic vessels.

Hybrid Prosthesis (Vascutek®, Terumo®, Inchinnan, Scotland, UK). Both techniques are shown in Figs 8 and 9. In the literature, there are no major differences between the two systems regarding the primary outcome parameters. However, because of their different

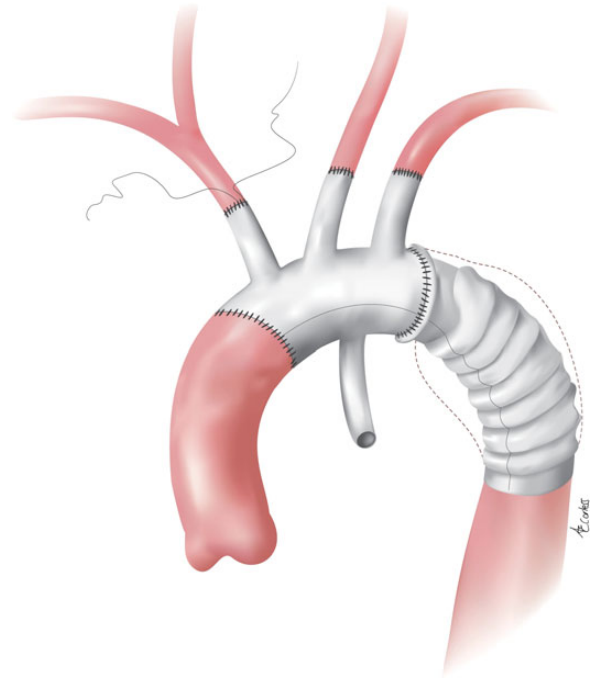


Figure 9: Scheme of FET implantation with the Vascutek device using a separated reimplantation of the supra-aortic vessels.

designs, the choice of the device may differ according to the individual strategy required in each specific case. The main difference is the provision of a quadruple branched Dacron® part with the Vascutek® system when compared with a straight Dacron® part with the Jotec® device. Both prostheses currently are distributed with a sewing cuff at the transition between the Dacron® part and the stent-graft to facilitate the descending aortic anastomosis. The quadruple branched design of the Vascutek® prosthesis enables a more proximal descending aortic anastomosis (between the left common carotid and the left subclavian arteries) since the left subclavian artery can be re-attached to the prosthesis using the most distal branch of the device. Regarding long-term performance of the stent-graft portion, there is no information available so far.

Hypothermic circulatory arrest and cerebral protection strategy

Cerebral protection strategies have been continuously modified during the last decade and the routine use of deep hypothermic circulatory arrest as isolated protection strategy is no more routinely used in Europe. Several publications including a recent survey upon the current trends of neuroprotection during surgery for acute type A aortic dissection in Europe show safety, efficacy as well as the broad implementation of milder hypothermic circulatory arrest temperatures in combination with the routine application of selective antegrade cerebral perfusion as an increasingly used strategy to optimize brain and end-organ protection [67, 68]. Consequently, the 2014 ESC guidelines on the diagnosis and treatment of aortic diseases recommend antegrade selective cerebral perfusion during hypothermic circulatory arrest to reduce the stroke risk during aortic arch surgery (Class IIa, Level B) [60]. In addition, some degree of spinal cord blood supply is provided as well by antegrade selective cerebral perfusion.

Neurological injury: paraplegia after conventional and frozen ET (cET versus FET)

SCI is one of the most devastating complications after extensive thoraco-abdominal aortic surgery, but particularly shattering after primary aortic arch repair. Paraplegia has been rarely reported after cET surgery. The reported incidence rate of permanent or transient ischaemic SCI after cET implantation ranges between 0.4 and 2.8% [69–71]. In contrast, the reported incidence rate of SCI in patients undergoing FET appears to be significantly higher. Data from the IEOR on 274 FET patients revealed an 8% rate of SCI, and a recent multicentre study reported a 9% incidence rate of this dreaded complication [28, 31].

Single-centre studies have reported incidences as high as 21–24% after FET implantation and hypothesized various mechanisms to explain SCI [16, 72, 73]. Miyairi *et al.* [72] attributed their observed episodes of post-FET paraplegia to spinal cord ischaemic times longer than 60 min in 3 of 4 cases, and unstable haemodynamics after cardiopulmonary bypass may have played an aggravating role. Mizuno *et al.* [73] reported 2 cases of paraplegia in their series of 9 FET patients without any identifiable risk factor, but their average lower body arrest time was long (54 ± 10 min). In both cases of paraplegia, the distal circulatory arrest time was longer than 40 min. One of the factors that may have an impact on SCI is the level of the distal landing zone of the stent-graft: the more distally the FET is deployed, the higher the number of occluded intercostal arteries. Flores *et al.* [16] demonstrated that a distal landing zone beyond T7 is associated with a significantly higher incidence of SCI. He reported a 24% incidence (6 of 25 patients) of ischaemic SCI in their series and distal deployment of the stent-graft was a significant risk factor in multivariate analysis. Similarly, Mizuno *et al.* [73] reported that the distal landing zone was at the T8 level in both patients suffering postoperative paraplegia. Thromboembolism to the spinal cord in the presence of severe atherosclerosis at the distal landing zone of the stent-graft is another potential mechanism of SCI [16].

Interestingly, the combination of a distal landing zone of T7 or lower and a history of previous abdominal aortic aneurysm repair was the strongest predictor for SCI in the Flores series [16]. This observation suggests an important role of distal inflow to the paraspinal arterial collateral network via the hypogastric arteries. Recent experimental studies on spinal cord blood flow, however, suggest that spinal perfusion is not acutely compromised by serial segmental artery sacrifice in a cranio-caudal direction down to a level of T11/12. Such findings are supported by the reasonably low paraparesis or paraplegia rates of 3.8% in clinical series of descending thoracic and Crawford type I thoraco-abdominal aortic aneurysm repairs [74].

The collateral network concept by Etz and Grieppe has been used to explain this phenomenon [63, 71, 75]. FET procedures, however, have the potential to impact on both inflow pathways simultaneously: segmental artery perfusion and upper inflow to the collateral network via the vertebral artery. This might be one reason for the increased occurrence of paraplegia and the significantly higher incidence when compared with cET procedures.

Follow-up and secondary interventions

It is obvious that patients after FET implantation warrant a similar follow-up protocol as patients after TEVAR do. Similarly to what may happen following primary TEVAR, there may be need for planned or unplanned secondary intervention, open or

endovascular. A comparison between open surgical completion and endovascular completion after cET has been reported by the Cleveland Clinic [76]. Open surgical completion is more demanding and represents a major intervention for the patient but is more durable [76]. In summary, there is a greater need for transfusion (red blood cells, plasma and platelets), an increased need for prolonged ventilation (requiring tracheostomy in certain patients) and an overall longer duration of hospital stay in the open completion group compared with the endovascular group. No difference was found between renal failure and neurological complications between both groups. Endoleaks occurred in 35% of the endovascular completion group. This becomes also obvious from the series of Greenberg *et al.* [77]. The 30-day mortality rate did not differ between the open surgical completion and the endovascular completion: 6 vs 6.5%, respectively.

Future developments

It is obvious that currently available devices have certain limitations and need continuing modifications. It is likely that, in the near future, simplified devices will be available making deployment and fixation comparable with a simple hemiarth replacement. Current modifications may include shorter versions of original devices. These developments may help to broaden the applicability and the acceptance of the method. In December 2013, the National Institute for Health and Care Excellence in the United Kingdom (NICE) has accredited the use of the FET concept for the treatment of complex aneurysms and dissections of the aorta by approving the use of a specific commercially available device (www.guidance.nice.org.uk/mtg16). This may help in enhancing applicability as mentioned. In any case, future intensive research will induce broader implementation of this technique or put it into question.

Data collection and reporting standards

We strongly support broad data collection, in particular, as substantial need for increased knowledge concerning several aspects of the procedure such as SCI remains. There is one registry reporting the results after FET using the E-Vita Open[®] prosthesis (IEOR). To date, there is no registry reporting the results after FET using the Thoraflex[™] prosthesis.

Reporting standards create a common language and a platform for knowledge exchange and are therefore strongly needed. The following suggestions are made addressing intraoperative parameters during the FET procedure: arterial cannulation site, core temperature during hypothermic circulatory arrest, type of cerebral perfusion, perfusate temperature and flow, cerebral perfusion time and hypothermic circulatory arrest time. In addition, the modality of cerebral monitoring, cardiopulmonary bypass time and myocardial ischaemic time should be reported.

A clear separation between lower body hypothermic circulatory arrest and cerebral hypothermic circulatory arrest should be made. In case of lower body perfusion, type and cannulation site, perfusate temperature as well as flow should be reported. Regarding the prosthesis, length and diameter of the stented portion should be reported.

Regarding procedure-related outcome, stroke and SCI as well as their suspected pathophysiological mechanisms should be reported in detail. Regarding reporting of follow-up parameters, we suggest adhering to recent EACTS/ESC recommendations [78]. Secondary

interventions, open or endovascular, should be reported. Finally, survival and aortic-related survival should be clearly differentiated.

Recommendation for use

Based on the available literature and on the expert consensus opinion of the authors, the following recommendations can be made:

- (i) The FET technique or an alternative method to close the primary entry tear should be considered in patients with acute type A aortic dissection with a primary entry in the distal aortic arch or in the proximal half of the descending aorta to treat associated malperfusion syndrome or to avoid its postoperative development. Class of recommendation IIa –Level of evidence C [23, 55]
- (ii) The FET technique may be considered for use in patients undergoing surgery for acute type A aortic dissection to prevent mid-term aneurysmal formation in the downstream aorta. Class of recommendation IIb–Level of evidence C [19, 47–49]
- (iii) The FET technique should be considered in patients with complicated acute type B aortic dissection when primary TEVAR is not feasible or the risk of retrograde type A aortic dissection is high. Class of recommendation IIa–Level of evidence C [50]
- (iv) The FET technique should be considered in patients with extensive thoracic or thoraco-abdominal aortic disease when a second procedure, either open surgical or endovascular in downstream aortic segments, can be anticipated. Class of recommendation IIa–Level of evidence C [42, 64]

Summary

The FET technique has broadened the armamentarium of surgeons and simplified the treatment of complex thoracic aortic pathology. The concept of obtaining the most possible complete primary repair and facilitating any secondary future intervention is effective. However, a trade-off regarding a higher rate of SCI is a serious problem. Further research will hopefully clarify the mechanisms of symptomatic SCI, and help to reduce its incidence.

Conflict of interest: Heinz Jakob is a consultant with Jotec.

REFERENCES

- [1] Borst HG, Walterbusch G, Schaps D. Extensive aortic replacement using 'elephant trunk' prosthesis. *Thorac Cardiovasc Surg* 1983;31:37–40.
- [2] Nienaber CA, Fattori R, Lund G, Dieckmann C, Wolf W, von Kodolitsch Y *et al.* Nonsurgical reconstruction of thoracic aortic dissection by stent-graft placement. *N Engl J Med* 1999;340:1539–45.
- [3] Dake MD, Miller DC, Mitchell RS, Semba CP, Moore KA, Sakai T. The 'first generation' of endovascular stent-grafts for patients with aneurysms of the descending thoracic aorta. *J Thorac Cardiovasc Surg* 1998;116:689–703.
- [4] Schoder M, Grabenwöger M, Hölzenbein T, Domanovits H, Fleischmann DWolf F *et al.* Endovascular stent-graft repair of complicated penetrating atherosclerotic ulcers of the descending thoracic aorta. *J Vasc Surg* 2002; 36:720–6.
- [5] Fleck T, Hutschala D, Czerny M, Ehrlich MP, Kasimir MT, Cejna M *et al.* Combined surgical and endovascular treatment of acute aortic dissection type A: preliminary results. *Ann Thorac Surg* 2002;74:761–5.
- [6] Bavaria J, Vallabhajosyula P, Moeller P, Szeto W, Desai N, Pochettino A. Hybrid approaches in the treatment of aortic arch aneurysms: postoperative and midterm outcomes. *J Thorac Cardiovasc Surg* 2013;145 (3 Suppl):S85–90.
- [7] Suto Y, Yasuda K, Shiiya N, Murashita T, Kawasaki M, Imamura M *et al.* Stented elephant trunk procedure for an extensive aneurysm involving distal aortic arch and descending aorta. *J Thorac Cardiovasc Surg* 1996; 112:1389–90.
- [8] Kato M, Ohnishi K, Kaneko M, Ueda T, Kishi D, Mizushima T *et al.* New graft-implanting method for thoracic aortic aneurysm or dissection with a stented graft. *Circulation* 1996;94(9 Suppl):II188–93.
- [9] Usui A, Fujimoto K, Ishiguchi T, Yoshikawa M, Akita T, Ueda Y. Cerebrospinal dysfunction after endovascular stent-grafting via a median sternotomy: the frozen elephant trunk. *Ann Thorac Surg* 2002;74:S1821–32.
- [10] Karck M, Chavan A, Hagl C, Friedrich H, Galanski M, Haverich A. The frozen elephant trunk: a new treatment for thoracic aortic aneurysms. *J Thorac Cardiovasc Surg* 2003;125:1550–3.
- [11] Karck M, Chavan A, Khaladj N, Friedrich H, Hagl C, Haverich A. The frozen elephant trunk technique for the treatment of extensive thoracic aortic aneurysms: operative results and follow-up. *Eur J Cardiothorac Surg* 2005; 28:286–90.
- [12] Tian DH, Wan B, Di Eusano M, Black D, Yan TD. A systematic review and meta-analysis on the safety and efficacy of the frozen elephant trunk technique in aortic arch surgery. *Ann Cardiothorac Surg* 2013;2: 581–91.
- [13] Moulakakis KG, Mylonas SN, Markatis F, Kotsis T, Kakisis J, Liapis CD. A systematic review and meta-analysis of hybrid aortic arch replacement. *Ann Cardiothorac Surg* 2013;2:247–60.
- [14] Murzi M, Tiwari KK, Farneti PA, Glauber M. Might type A acute dissection repair with the addition of a frozen elephant trunk improve long-term survival compared to standard repair? *Interact CardioVasc Thorac Surg* 2010; 11:98–102.
- [15] Baraki H, Hagl C, Khaladj N, Kallenbach K, Weidemann J, Haverich A *et al.* The frozen elephant trunk technique for treatment of thoracic aortic aneurysms. *Ann Thorac Surg* 2007;83:S819–23.
- [16] Flores J, Kunihara T, Shiiya N, Yoshimoto K, Matsuzaki K, Yasuda K. Extensive deployment of the stented elephant trunk is associated with an increased risk of spinal cord injury. *J Thorac Cardiovasc Surg* 2006;131: 336–42.
- [17] Pichlmaier MA, Teebken OE, Baraki H, Haverich A. The frozen elephant trunk technique. *Multimed Man Cardiothorac Surg* 2007; doi:10.1510/ mmcts.2006.001990.
- [18] Shimamura K, Kuratani T, Matsumiya G, Kato M, Shirakawa Y, Takano H *et al.* Long-term results of the open stent-grafting technique for extended aortic arch disease. *J Thorac Cardiovasc Surg* 2008;135:1261–9.
- [19] Uchida N, Shibamura H, Katayama A, Shimada N, Sutoh M, Ishihara H. Operative strategy for acute type A aortic dissection: ascending aortic or hemiarch versus total arch replacement with frozen elephant trunk. *Ann Thorac Surg* 2009;87:773–7.
- [20] Pochettino A, Brinkman WT, Moeller P, Szeto WY, Moser W, Cornelius K *et al.* Antegrade thoracic stent grafting during repair of acute DeBakey I dissection prevents development of thoracoabdominal aortic aneurysms. *Ann Thorac Surg* 2009;88:482–9.
- [21] Di Bartolomeo R, Di Marco L, Armaro A, Marsilli D, Leone A, Pilato E *et al.* Treatment of complex disease of the thoracic aorta: the frozen elephant trunk technique with the E-Vita open prosthesis. *Eur J Cardiothorac Surg* 2009;35:671–5.
- [22] Uchida N, Katayama A, Tamura K, Sutoh M, Kuraoka M, Murao N *et al.* Long-term results of the frozen elephant trunk technique for extended aortic arch disease. *Eur J Cardiothorac Surg* 2010;37:1338–45.
- [23] Tsagakis K, Pacini D, Di Bartolomeo R, Gorlitzer M, Weiss G, Grabenwöger M *et al.* Multicenter early experience with extended aortic repair in acute aortic dissection: is simultaneous descending stent grafting justified? *J Thorac Cardiovasc Surg* 2010;140:S116–20.
- [24] Di Bartolomeo R, Pacini D, Savini C, Pilato E, Martin-Suárez S, Di Marco L *et al.* Complex thoracic aortic disease: single-stage procedure with the frozen elephant trunk technique. *J Thorac Cardiovasc Surg* 2010;140: S81–5.
- [25] Uchida N, Shibamura H, Katayama A, Sutoh M, Kuraoka M, Ishihara H. Long-term results of the frozen elephant trunk technique for the extensive arteriosclerotic aneurysm. *J Thorac Cardiovasc Surg* 2010;139:913–7.
- [26] Jakob H, Tsagakis K. DeBakey type I dissection: when hybrid stent-grafting is indicated? *J Cardiovasc Surg* 2010;51:633–40.
- [27] Chen X, Huang F, Xu M, Wang L, Jiang Y, Xiao L *et al.* The stented elephant trunk procedure combined total arch replacement for Debakey I aortic dissection: operative result and follow-up. *Interact CardioVasc Thorac Surg* 2010;11:594–8.

- [28] Jakob H, Tsagakis K, Pacini D, Di Bartolomeo R, Mestres CA, Mohr FW *et al.* The International E-vita Open Registry: data sets of 274 patients. *J Cardiovasc Surg (Torino)* 2011;52:717–23.
- [29] Sun L, Qi R, Zhu J, Liu Y, Chang Q, Zheng J. Repair of acute type A dissection: our experiences and results. *Ann Thorac Surg* 2011;91:1147–52.
- [30] Tsagakis K, Pacini D, Di Bartolomeo R, Benedik J, Cerny S, Grolitzer M *et al.* Arch replacement and downstream stent grafting in complex aortic dissection: firsts results of an international registry. *Eur J Cardiothorac Surg* 2011;39:87–93.
- [31] Pacini D, Tsagakis K, Jakob H, Mestres CA, Armario A, Weiss G *et al.* The frozen elephant trunk for the treatment of chronic dissection of the thoracic aorta: a multicenter experience. *Ann Thorac Surg* 2011;92:1663–70.
- [32] Uchida N, Katayama A, Tamura K, Sutoh M, Kuraoka M, Ishihara H. Frozen elephant trunk technique and partial remodeling for acute type A aortic dissection. *Eur J Cardiothorac Surg* 2011;40:1066–71.
- [33] Di Eusanio M, Armario A, Di Marco L, Pacini D, Savini C, Suarez SM *et al.* Short- and midterm results after hybrid treatment of chronic aortic dissection with the frozen elephant trunk technique. *Eur J Cardiothorac Surg* 2011;40:875–80.
- [34] Shi E, Gu T, Yu L, Xiu Z, Zhang Z, Wang C *et al.* Repair of Stanford type A aortic dissection with ascending aorta and hemiarch replacement combined with stent-graft elephant trunk technique by using innominate cannulation. *J Thorac Cardiovasc Surg* 2011;142:1458–63.
- [35] Lima B, Roselli EE, Soltesz EG, Johnston DR, Pujara AC, Idrees J *et al.* Modified and 'reverse' frozen elephant trunk repairs for extensive disease and complications after stent grafting. *Ann Thorac Surg* 2012;93:103–9.
- [36] Ma WG, Zheng J, Dong SB, Lu W, Sun K, Qi RD *et al.* Sun's procedure of total arch replacement using a tetrafurcated graft with stented elephant trunk implantation: analysis of early outcome in 398 patients with acute type A aortic dissection. *Ann Cardiothorac Surg* 2013;2:621–8.
- [37] Uchida N, Kodama H, Katayama K, Takasaki T, Katayama A, Takahashi S *et al.* Endovascular aortic repair as second-stage surgery after hybrid open arch repair by the frozen elephant trunk technique for extended thoracic aneurysm. *Ann Thorac Cardiovasc Surg* 2013;19:257–61.
- [38] Shi EY, Gu TX, Yu Y, Yu L, Wang C, Fang Q *et al.* Early and midterm outcomes of hemiarch replacement combined with stented elephant trunk in the management of acute DeBakey type I aortic dissection: comparison with total arch replacement. *J Thorac Cardiovasc Surg* 2014;148:2125–31.
- [39] Tsagakis K, Dohle D, Benedik J, Lieder H, Jakob H. Overall Essen's experience with the E-Vita open hybrid stent graft system and evolution of the surgical technique. *Ann Cardiothorac Surg* 2013;2:612–20.
- [40] Ius F, Fleissner F, Pichlmaier M, Karck M, Martens A, Haverich A *et al.* Total arch replacement with the frozen elephant trunk technique: 10-year follow-up single-center experience. *Eur J Cardiothorac Surg* 2013;44:949–57.
- [41] Di Eusanio M, Pantaleo A, Murana G, Pellicciari G, Castrovinci S, Berretta P *et al.* Frozen elephant trunk surgery—the Bologna's experience. *Ann Cardiothorac Surg* 2013;2:597–605.
- [42] Mestres CA, Tsagakis K, Pacini D, Di Bartolomeo R, Grabenwöger M, Borger MA *et al.* One-stage repair in complex multisegmental thoracic aneurysmal disease: results of a multicenter study. *Eur J Cardiothorac Surg* 2013;44:e325–31.
- [43] Leontyev S, Misfeld M, Davierwala P, Borger MA, Etz CD, Belaev S *et al.* Early- and medium-term results after aortic arch replacement with frozen elephant trunk techniques—a single center study. *Ann Cardiothorac Surg* 2013;2:606–11.
- [44] Leontyev S, Borger MA, Etz CD, Moz M, Seeburger J, Bakhtiary F *et al.* Experience with the conventional and frozen elephant trunk techniques: a single-center study. *Eur J Cardiothorac Surg* 2013;44:1076–82.
- [45] Shrestha M, Pichlmaier M, Martens A, Hagl C, Khaladj N, Haverich A. Total aortic arch replacement with a novel four-branched frozen elephant trunk graft: First-in-man results. *Eur J Cardiothorac Surg* 2013;43:406–10.
- [46] Hoffman A, Damberg AL, Schälte G, Mahnken AH, Raweh A, Autschbach R. Thoracic stent graft sizing for frozen elephant trunk repair in acute type A dissection. *J Thorac Cardiovasc Surg* 2013;145:964–9.
- [47] Ma WG, Zhu JM, Zheng J, Liu YM, Ziganshin BA, Eleftheriades JA *et al.* Sun's procedure for complex aortic arch repair: total arch replacement using a tetrafurcate graft with stented elephant trunk implantation. *Ann Cardiothorac Surg* 2013;2:642–8.
- [48] Katayama A, Uchida N, Katayama K, Arakawa M, Sueda T. The frozen elephant trunk technique for acute type A aortic dissection: results from 15 years of experience. *Eur J Cardiothorac Surg* 2015;47:355–60.
- [49] Katayama K, Uchida N, Katayama A, Takahashi S, Takasaki T, Kurosaki T *et al.* Multiple factors predict the risk of spinal cord injury after the frozen elephant trunk technique for extended thoracic aortic disease. *Eur J Cardiothorac Surg* 2015;47:616–20.
- [50] Weiss G, Tsagakis K, Jakob H, DiBartolomeo R, Pacini D, Barberio G *et al.* The frozen elephant trunk technique for the treatment of complicated type B aortic dissection with involvement of the aortic arch: multicenter early experience. *Eur J Cardiothorac Surg* 2015;47:106–14.
- [51] Shrestha M, Fleissner F, Ius F, Koigeldiyev N, Kaufeld T, Beckmann F *et al.* Total arch replacement with frozen elephant trunk in acute type A aortic dissections: are we pushing the limits too far? *Eur J Cardiothorac Surg* 2015;47:361–6.
- [52] Xiao Z, Meng W, Zhu D, Guo Y, Zhang E. Treatment strategies for left subclavian artery during total arch replacement combined with stented elephant trunk implantation. *Thorac Cardiovasc Surg* 2014;147:639–43.
- [53] Tamura K, Uchida N, Katayama A, Sutoh M, Kuraoka M, Sueda T. The frozen elephant trunk technique or retrograde acute type A aortic dissection. *J Thorac Cardiovasc Surg* 2014;148:561–5.
- [54] Bonser RS, Ranasinghe AM, Loubani M, Evans JD, Thalji NM, Bachet JE *et al.* Evidence, lack of evidence, controversy and debate in the provision and performance of the surgery of acute type A aortic dissection. *J Am Coll Cardiol* 2011;58:2455–74.
- [55] Li B, Ma WG, Liu YM, Sun LZ. Is extended arch replacement justified for acute type A aortic dissection? *Interact CardioVasc Thorac Surg* 2015;20:120–7.
- [56] Czerny M, Roedler S, Fakhimi S, Sodeck G, Funovics M, Dumfarth J *et al.* Midterm results of thoracic endovascular aortic repair in patients with aneurysms involving the descending aorta originating from chronic type B dissections. *Ann Thorac Surg* 2010;90:90–4.
- [57] Dumfarth J, Michel M, Schmidli J, Sodeck G, Ehrlich M, Grimm M *et al.* Mechanisms of failure and outcome of secondary surgical interventions after thoracic endovascular aortic repair (TEVAR). *Ann Thorac Surg* 2011;91:1141–6.
- [58] Jánosi RA, Tsagakis K, Bettin M, Kahlert P, Horacek M, Al-Rashid F *et al.* Thoracic aortic aneurysm expansion due to late distal stent-graft-induced new entry. *Catheter Cardiovasc Interv* 2015;85:E43–53.
- [59] Nienaber CA, Kische S, Rousseau H, Eggebrecht H, Rehders TC, Kundt G *et al.* Endovascular repair of type B aortic dissection: long-term results of the randomized investigation of stent grafts in aortic dissection trial. *Circ Cardiovasc Interv* 2013;6:407–16.
- [60] Erbel R, Aboyans V, Boileau C, Bossone E, Bartolomeo RD, Eggebrecht H *et al.* 2014 guidelines on the diagnosis and treatment of aortic diseases: document covering acute and chronic aortic diseases of the thoracic and abdominal aorta of the adult: task force for the diagnosis and treatment of aortic diseases of the European society of Cardiology (ESC). *Eur Heart J* 2014;35:2873–926.
- [61] Eggebrecht H, Thompson M, Rousseau H, Czerny M, Lönn L, Mehta RH *et al.* Retrograde ascending aortic dissection during or after thoracic aortic stent graft placement: insights from the European registry on endovascular aortic repair complications. *Circulation* 2009;120:S276–81.
- [62] Czerny M, Rieger M, Schmidli J. Incidence, risk factors and outcome of retrograde type A aortic dissection after TEVAR— a systematic review. *Gefäßchirurgie* 2015;20:25–31.
- [63] Etz CD, Kari FA, Mueller CS, Silovitz D, Brenner RM, Lin HM *et al.* The collateral network concept: a reassessment of the anatomy of spinal cord perfusion. *J Thorac Cardiovasc Surg* 2011;141:1020–8.
- [64] Folkmann S, Weiss G, Pisarik H, Czerny M, Grabenwöger M. Thoracoabdominal aortic aneurysm repair after frozen elephant trunk procedure. *Eur J Cardiothorac Surg* 2015;47:115–9.
- [65] Evangelista A, Czerny M, Nienaber C, Schepens M, Rousseau H, Cao P *et al.* Interdisciplinary expert consensus on management of type B intramural hematoma and penetrating aortic ulcer. *Eur J Cardiothorac Surg* 2015;47:209–17.
- [66] Grimm M, Loewe C, Gottardi R, Funovics M, Zimpfer D, Rodler S *et al.* Novel insights into the mechanisms and treatment of intramural hematoma affecting the entire thoracic aorta. *Ann Thorac Surg* 2008;86:453–6.
- [67] Czerny M, Krähenbühl E, Reineke D, Sodeck G, Englberger L, Weber A *et al.* Mortality and neurologic injury after surgical repair with hypothermic circulatory arrest in acute and chronic proximal thoracic aortic pathology: effect of age on outcome. *Circulation* 2011;124:1407–13. Erratum in 2014 Feb 25;129(8):e357.
- [68] De Paulis R, Czerny M, Weltert L, Bavaria J, Borger MA, Carrel TP *et al.* Current trends in cannulation and neuroprotection during

- surgery of the aortic arch in Europe. *Eur J Cardiothorac Surg* 2015;47:917-23.
- [69] Safi HJ, Miller CC III, Estrera AL, Villa MA, Goodrick JS, Porat E *et al.* Optimization of aortic arch replacement: two-stage approach. *Ann Thorac Surg* 2007;83:S815-8.
- [70] Palma JH, Almeida DR, Carvalho AC, Andrade JC, Buffolo E. Surgical treatment of acute type b aortic dissection using an endoprosthesis (elephant trunk). *Ann Thorac Surg* 1997;63:1081-4.
- [71] Etz CD, Plestis KA, Kari FA, Luehr M, Bodian CA, Spielvogel D *et al.* Staged repair of thoracic and thoracoabdominal aortic aneurysms using the elephant trunk technique: a consecutive series of 215 first stage and 120 complete repairs. *Eur J Cardiothorac Surg* 2008;34:605-14.
- [72] Miyairi T, Kotsuka Y, Ezure M, Ono M, Morota T, Kubota H *et al.* Open stent-grafting for aortic arch aneurysm is associated with increased risk of paraplegia. *Ann Thorac Surg* 2002;74:83-9.
- [73] Mizuno T, Toyama M, Tabuchi N, Wu H, Sunamori M. Stented elephant trunk procedure combined with ascending aorta and arch replacement for acute type A aortic dissection. *Eur J Cardiothorac Surg* 2002;22:504-9.
- [74] Coselli JS, Bozinovski J, LeMaire SA. Open surgical repair of 2286 thoracoabdominal aortic aneurysms. *Ann Thorac Surg* 2007;83:S862-4.
- [75] Etz CD, Kari FA, Mueller CS, Brenner RM, Lin HM, Griep RB. The collateral network concept: remodeling of the arterial collateral network after experimental segmental artery sacrifice. *J Thorac Cardiovasc Surg* 2011;141:1029-36.
- [76] Roselli EE, Subramanian S, Sun Z, Idrees J, Nowicki E, Blackstone EH *et al.* Endovascular versus open elephant trunk completion for extensive aortic disease. *J Thorac Cardiovasc Surg* 2013;146:1408-16.
- [77] Greenberg RK, Haddad F, Svensson L, O'Neill S, Walker E, Lyden SP *et al.* Hybrid approaches to thoracic aortic aneurysms: the role of endovascular elephant trunk completion. *Circulation* 2005;112:2619-26.
- [78] Grabenwöger M, Alfonso F, Bachet J, Bonser R, Czerny M, Eggebrecht H *et al.* Thoracic Endovascular Aortic Repair (TEVAR) for the treatment of aortic diseases: a position statement from the European Association for Cardio-Thoracic Surgery (EACTS) and the European Society of Cardiology (ESC), in collaboration with the European Association of Percutaneous Cardiovascular Interventions (EAPCI). *Eur J Cardiothorac Surg* 2012;42:17-24.