

*Case Report*

## **Intrarenal arterial aneurysms with haematuria in a patient with tuberous sclerosis complex**

Thomas Künzi<sup>1</sup>, Frank Walther<sup>2</sup>, Hans-Peter Marti<sup>1</sup>, Felix J. Frey<sup>1</sup> and Bruno Vogt<sup>1</sup>

<sup>1</sup>Nephrology/Hypertension and <sup>2</sup>Diagnostic Radiology, University Hospital of Berne, Switzerland

**Keywords:** aneurysm; embolization; haematuria; tuberous sclerosis

### **Introduction**

Tuberous sclerosis complex (TSC) is an autosomal dominant disease with a wide spectrum of pathological lesions [1,2]. Almost half of the patients with TSC have an underlying renal pathology, mainly angiomyolipomas, cysts and/or renal cell carcinoma [3,4]. TSC rarely involves medium size and large vessels, including the renal arteries. Arterial aneurysms have been reported for intracranial arteries, for the aorta and for the kidneys in patients with TSC [5]. The clinical management of the two main complications, fever and haematuria, in these patients is uncertain. Here we report on a patient with two large intrarenal arterial aneurysms who presented with macroscopic haematuria and fever successfully treated by intra-arterial embolization.

### **Case**

A 31-year-old male patient was referred to our department because of fever up to 39.4°C, weight loss and macroscopic haematuria with anaemia.

At the age of 9 months, the diagnosis of TSC was established because of facial angiofibroma and multiple unguinal fibromas. Four years before admission, both kidneys were found to be increased in size with extensive angiomyolipomas and in the brain multiple calcified subependymal nodules and cortical tuber were documented.

Two weeks before admission, the patient was hospitalized in another hospital because of fever and macroscopic haematuria of sudden onset, without a history of trauma. Repeated urinary cultures for

bacteria remained negative. Transoesophageal echography and multiple blood cultures to exclude infective endocarditis were negative. MRI scan of the abdomen revealed enlarged kidneys with multiple bilateral angiomyolipomas and two large intrarenal arterial aneurysms in the right kidney (Figure 1).

On admission to our department, body temperature was 39.6°C, blood pressure 120/60 mmHg and pulse rate 96/min. The physical examination revealed a pale patient with two large kidneys with irregular surface and a painful right flank. A general neurological examination was normal.

Blood haemoglobin was 79 g/l; leukocyte count increased to 15.4 (10<sup>9</sup>/l) and thrombocytosis of 546 (10<sup>9</sup>/l) was present. C-reactive protein (CRP) was 42 mg/l (normal range <5 mg/l). Renal function was normal (serum creatinine, 87 µmol/l). Macroscopic haematuria was present (Table 1).

The patient received blood transfusions to treat the anaemia. During 7 days of observation macro-haematuria with anaemia and fever up to 40°C persisted. Despite fever, increased leukocytes count and increased CRP (up to 170 mg/l), repeated blood and urine cultures remained negative and so no antibiotic therapy was given.

On the seventh day after admission, haematuria increased with deterioration of anaemia despite blood transfusions (serum haemoglobin 69 g/l, haematocrit 0.20) (Table 1). The control MRI scan revealed an increase in diameter of both aneurysms. Selective embolization of both aneurysms was performed by direct angiography (digital subtraction angiography) with application of multiple coils (Vort X, Boston Scientific; 2–3/4/5 mm) in the aneurysms. The coils were applied through a microcatheter system (5F Cobra with Tracker catheter). Initially, the macroscopic haematuria disappeared, but reappeared on the second day after the intervention. Duplex sonography of the aneurysms revealed still partial blood flow in the larger aneurysm. A second selective embolization of this aneurysm was performed. Thereafter, haematuria disappeared and anaemia resolved. During the two following weeks, fever and inflammatory signs

*Correspondence and offprint requests to:* Bruno Vogt, Division of Nephrology and Hypertension, Inselspital, University of Berne, Freiburgstrasse 10, 3010 Berne, Switzerland. Email: bvogt@gmx.ch

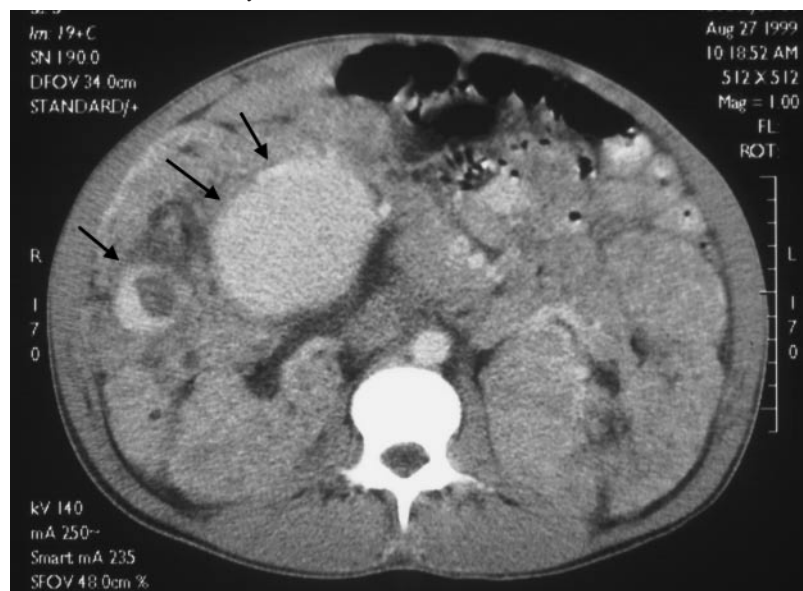


Fig. 1. MRI scan of the abdomen shows large kidneys with multiple angiomyolipomas and two intrarenal aneurysms (black arrows).

Table 1. Laboratory parameters and body temperatures

	Before treatment	Peak value	After treatment
Body temperature (°C)	39.5	40.4	38.6
Haemoglobin (g/l)	79	69	92
Leukocyte count (10 <sup>9</sup> /l)	15.4	18.8	12.3
Thrombocyte count (10 <sup>9</sup> /l)	546	611	395
Serum creatinine (µmol/l)	99	152	94
CRP (U/l)	42	170	24
LDH (U/l)	944	5330	640
Haematuria	Macroscopic	Macroscopic	0–4 Ec

disappeared without antibiotic therapy. Renal function declined immediately after the radiologic interventions (peak serum creatinine 152 µmol/l) and returned to normal values within 1 week (Table 1). During the following 2 years, haematuria did not recur and renal function remained normal. No recurrence of aneurysms was detected in subsequent MRI scans.

## Discussion

The main renal manifestations of TSC are angiomyolipomas, cysts and renal cell carcinomas. The important complications of renal angiomyolipomas are haemorrhage (haematuria, intratumoral and retroperitoneal haemorrhage) and mass effects with abdominal tenderness [1–7]. Our patient presented with both haematuria and pain in the left flank. Diagnostic imaging of the kidneys revealed two large intrarenal aneurysms. Abundant and altered blood vessels with abnormal elastin-poor structures are present in angiomyolipomas

and are probably at the origin of the formation of these aneurysms [8].

Nephrectomy was discussed repeatedly to stop the heavy haematuria presented by our patient. We did not perform nephrectomy for several reasons. First, nephrectomy would have reduced renal mass and eventually impaired renal function and second, we had no radiologic evidence for a renal cell carcinoma. The presence of fever with leucocytosis and increased serum CRP levels might be another reason for nephrectomy. Since in multiple cultures of blood and urine no bacteria were cultivated and the removal of one kidney is usually followed by the removal of the second one, because of persistence of fever and inflammatory signs, we preferred embolization to nephrectomy. Angiomyolipoma *per se* can cause fever in TSC patients by an unknown mechanism [9–11]. Since renal angiomyolipomas are frequently bilateral and end-stage renal failure is rare in patients with TSC [12], every effort should be made to avoid nephrectomy.

The clinical course of renal angiomyolipoma can be complicated by pain, gross haematuria, retroperitoneal haemorrhage and even death [1,2]. TSC-associated angiomyolipoma tends to be larger, multiple and more likely to cause spontaneous haemorrhage than sporadic forms of angiomyolipoma [13]. As a benign lesion that is usually asymptomatic, angiomyolipoma may often not require intervention [13]. Indications for intervention include suspicion of malignancy, spontaneous haemorrhage causing significant symptoms, pain, haematuria and risk of rupture or other complication as the formation of an intrarenal aneurysm [7]. The indications for treating asymptomatic angiomyolipoma in TSC are controversial. Limited prospective data suggest that larger lesions may become symptomatic with time [14–17]. Most of symptomatic angiomyolipoma can be managed by nephron-sparing approaches,

including angiographic embolization or partial nephrectomy; nevertheless some selected patients may require complete nephrectomy [13,18]. Some renal angiomyolipoma present with aneurysma formation that may be a predictor of rupture. Yakamado *et al.* [7] demonstrated that significant relationships exist between tumour size, aneurysm formation and rupture in angiomyolipomas. The presence of intratumoral aneurysms appears to be a predictor of spontaneous rupture, and detection of such aneurysms may help to determine the timing of treatment. If it is obvious that symptomatic intrarenal aneurysms presented by the mentioned patient should be treated, the question is open whether asymptomatic intrarenal aneurysms should be treated or not [7].

Selective embolization of intrarenal artery aneurysm in patients with TSC can stop acute haemorrhage and prevent further bleeding with preservation of renal mass and eventually renal function as shown in the present patient.

*Acknowledgements.* This work was supported a grant from the Swiss National Foundation for Scientific Research (Nr 32-57205.99).

*Conflict of interest statement.* None declared.

## References

1. Milliner DS, Torres VE. Renal manifestation of neurofibromatosis and tuberous sclerosis. In: Morgan SH, Grünfeld J-P eds. *Inherited Disorders of the Kidney*, 1st edn. Oxford University Press, Oxford, UK: 1998
2. Neumann HPH, Petri Henske E, Iliopoulos O, Glaesker S. Renal involvement in tuberous sclerosis and von Hippel-Lindau disease. In: Davison AM, Cameron JS, Grünfeld J-P *et al.* eds. *Oxford Textbook of Clinical Nephrology*, 3rd edn. Oxford University Press, Oxford, 2005
3. Torres VE, King BF, Holley KE, Blute ML, Gomez MR. The kidney in the tuberous sclerosis complex. *Adv Nephrol Necker Hosp* 1994; 23: 43–70
4. Smith DC. Treatment of renal angiomyolipoma. *N Engl J Med* 1998; 339: 1400
5. Lie JT. Cardiac, pulmonary, and vascular involvements in tuberous sclerosis. *Ann NY Acad Sci* 1991; 615: 58–70
6. Oesterling JE, Fishman EK, Goldman SM, Marshall FF. The management of renal angiomyolipoma. *J Urol* 1986; 135: 1121–1124
7. Yamakado K, Tanaka N, Nakagawa T, Kobayashi S, Yanagawa M, Takeda K. Renal angiomyolipoma: relationships between tumor size, aneurysm formation, and rupture. *Radiology* 2002; 225: 78–82
8. Eble JN. Angiomyolipoma of kidney. *Semin Diagn Pathol* 1998; 15: 21–40
9. Vekemans K, Van Oyen P, Denys H, Vergison R. Renal angiomyolipoma as a cause of fever of unknown origin. *Br J Urol* 1987; 60: 271
10. Campbell EW, Brantley R, Harrold M, Simson LR. Angiomyolipoma presenting as fever of unknown origin. *Am J Med* 1974; 57: 843–846
11. Sukenik S, Kaneti J, Zirkin HJ, Buskila D. Angiomyolipoma presenting as fever of unknown origin. *Isr J Med Sci* 1985; 21: 860–861
12. Clarke A, Hancock E, Kingswood C, Osborne JP. End-stage renal failure in adults with the tuberous sclerosis complex. *Nephrol Dial Transplant* 1999; 14: 988–991
13. Nelson CP, Sanda MG. Contemporary diagnosis and management of renal angiomyolipoma. *J Urol* 2002; 168: 1315–1325
14. Steiner MS, Goldman SM, Fishman EK, Marshall FF. The natural history of renal angiomyolipoma. *J Urol* 1993; 150: 1782–1786
15. van Baal JG, Smits NJ, Keeman JN, Lindhout D, Verhoef S. The evolution of renal angiomyolipomas in patients with tuberous sclerosis. *J Urol* 1994; 152: 35–38
16. Ewalt DH, Sheffield E, Sparagana SP, Delgado MR, Roach ES. Renal lesion growth in children with tuberous sclerosis complex. *J Urol* 1998; 160: 141–145
17. Kennelly MJ, Grossman HB, Cho KJ. Outcome analysis of 42 cases of renal angiomyolipoma. *J Urol* 1994; 152: 1988–1991
18. Fazeli-Matin S, Novick AC. Nephron-sparing surgery for renal angiomyolipoma. *Urology* 1998; 52: 577–583

*Received for publication: 22.8.04*

*Accepted in revised form: 10.5.05*