

---

## REGIONAL ANAESTHESIA

---

# Ultrasound-guided blocks of the ilioinguinal and iliohypogastric nerve: accuracy of a selective new technique confirmed by anatomical dissection

U. Eichenberger<sup>1\*</sup>, M. Greher<sup>1</sup>, L. Kirchmair<sup>2</sup>, M. Curatolo<sup>4</sup> and B. Moriggl<sup>3</sup>

<sup>1</sup>Department of Anaesthesia and General Intensive Care (B), Medical University of Vienna, A-1090 Vienna, Austria. <sup>2</sup>Department of Anaesthesia and Intensive Care and <sup>3</sup>Department of Anatomy, Histology and Embryology, Innsbruck Medical University, A-6020 Innsbruck, Austria. <sup>4</sup>Department of Anaesthesiology, University Hospital of Berne, CH-3010 Bern, Switzerland

\*Corresponding author: Department of Anaesthesiology, University Hospital of Berne, Inselspital, CH-3010 Bern, Switzerland. E-mail: [urs.eichenberger@insel.ch](mailto:urs.eichenberger@insel.ch)

**Background.** Ilioinguinal and iliohypogastric nerve blocks may be used in the diagnosis of chronic groin pain or for analgesia for hernia repair. This study describes a new ultrasound-guided approach to these nerves and determines its accuracy using anatomical dissection control.

**Methods.** After having tested the new method in a pilot cadaver, 10 additional embalmed cadavers were used to perform 37 ultrasound-guided blocks of the ilioinguinal and iliohypogastric nerve. After injection of 0.1 ml of dye the cadavers were dissected to evaluate needle position and colouring of the nerves.

**Results.** Thirty-three of the thirty-seven needle tips were located at the exact target point, in or directly at the ilioinguinal or iliohypogastric nerve. In all these cases the targeted nerve was coloured entirely. In two of the remaining four cases parts of the nerves were coloured. This corresponds to a simulated block success rate of 95%. In contrast to the standard 'blind' techniques of inguinal nerve blocks we visualized and targeted the nerves 5 cm cranial and posterior to the anterior superior iliac spine. The median diameters of the nerves measured by ultrasound were: ilioinguinal 3.0×1.6 mm, and iliohypogastric 2.9×1.6 mm. The median distance of the ilioinguinal nerve to the iliac bone was 6.0 mm and the distance between the two nerves was 10.4 mm.

**Conclusions.** The anatomical dissections confirmed that our new ultrasound-guided approach to the ilioinguinal and iliohypogastric nerve is accurate. Ultrasound could become an attractive alternative to the 'blind' standard techniques of ilioinguinal and iliohypogastric nerve block in pain medicine and anaesthetic practice.

*Br J Anaesth* 2006; **97**: 238–43

**Keywords:** anaesthesia, regional; measurement techniques, ultrasonography; nerve block, ilioinguinal/iliohypogastric; pain, chronic

Accepted for publication: March 15, 2006

Ilioinguinal (II) and iliohypogastric (IH) nerve blocks are often performed to provide intra- and postoperative analgesia for hernia repair especially in children.<sup>1,2</sup> Several techniques are described in the literature.<sup>3–6</sup> All these techniques use high amounts of local anaesthetic and are relatively unselective, which may lead to blocks of other adjacent nerves such as the femoral nerve.<sup>1</sup> Recently, an ultrasound-guided technique for II and IH nerve blocks in children was

described for the first time.<sup>7</sup> The method, however, is unselective because the two nerves were targeted and blocked using a single injection technique.

An additional indication of II and IH nerve blocks is to evaluate whether peripheral nociceptive or neuropathic components are present in chronic pain patients after inguinal hernia repair. Chronic pain after inguinal hernia repair has recently been recognized as an important

problem. A review found its incidence to be as high as 54%, with about one-third of these patients reporting moderate to unbearable pain.<sup>8</sup> Considering the very high number of operations performed, for example 800 000 in the USA in 2003,<sup>9</sup> this pain syndrome affects the quality of life of many patients and results in high social costs. The 'blind' techniques are not suitable for a selective block of the II and IH nerves, which would be needed to diagnose peripherally mediated pain in these chronic pain patients.

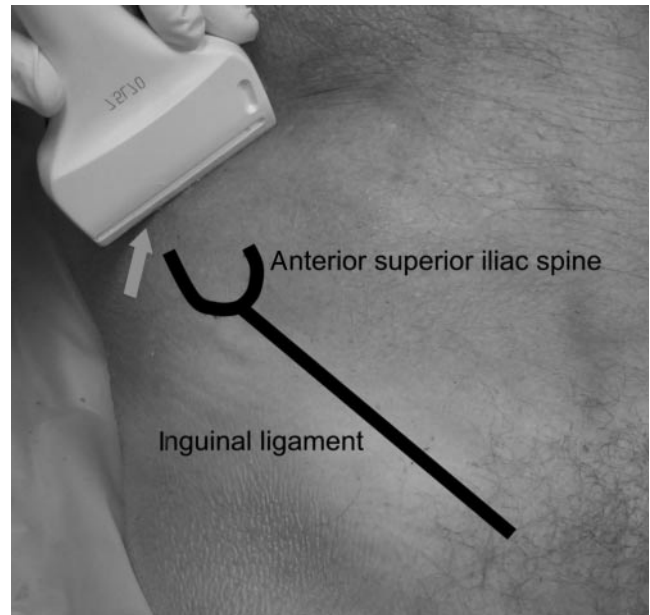
The technical development of ultrasound devices and of high frequency high-resolution transducers in recent years made a direct visualization of small nerves by ultrasound possible. In regional anaesthesia, ultrasound guidance for nerve blocks is being used with increased frequency<sup>10</sup> and ultrasound has been shown to offer guidance for selective nerve block techniques for invasive pain therapy.<sup>11 12</sup> We developed an ultrasound-guided double injection approach to the II and IH nerve in adults to be used to block these nerves in daily practice.

In this study, we tested the accuracy and the selectivity of our ultrasound-guided technique for II and IH nerve block by injection of a very small amount of dye in human cadavers and verification of the selective colouring of the nerves by anatomical dissection.

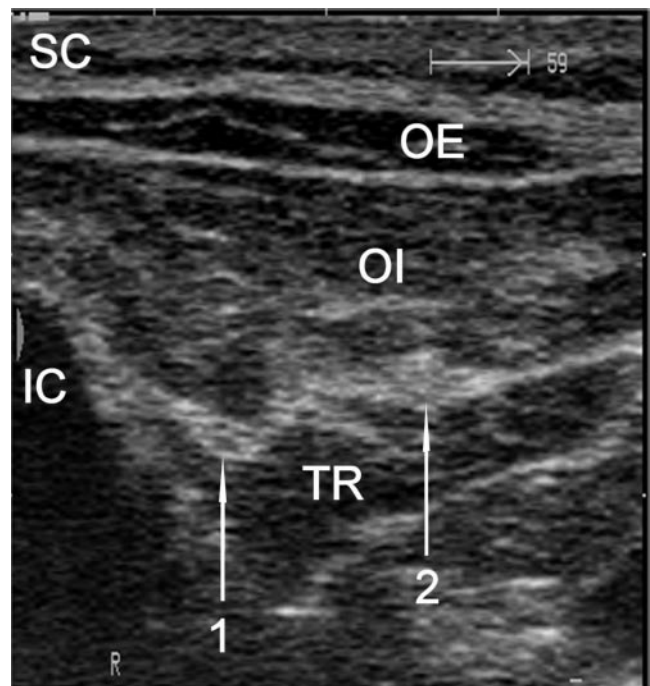
## Materials and methods

The cadavers had been embalmed in a traditional manner as done for usage of donors within (postgraduate) operating courses at the Department of Anatomy, Histology and Embryology of the Innsbruck Medical University, Innsbruck, Austria. The embalming fluid is mainly composed of ethanol and glycerol with a little amount of phenol added. All cadavers were in legal custody of the Department and Institutional approval for the procedure was obtained. The embalming process cannot stop gas formation in the tissue in all cadavers. If gas is present, artifacts markedly limit the ultrasound examination and from other studies in the past we knew that it is not possible to distinguish the different tissues in some cadavers. Therefore, the supraclavicular region of the cadaver's neck was scanned by an independent examiner using a standard ultrasound device (Sonoline VersaPlus; Siemens Medical Solutions, Erlangen, Germany) and a 10 MHz linear array transducer (10L50). Cadavers showing a lot of artifacts and bad recognition quality of the tissue were not enrolled in the study. Out of 20 scanned cadavers 17 with acceptable ultrasound imaging quality of the neck were initially enrolled in the study. From these 17 subjects another 6 had to be excluded later because of gas in the abdominal wall and therefore air-artifacts and impossible recognition of the underlying tissue during ultrasound examination.

The first cadaver was used as pilot case to determine the volume of the dye for the injections. The abdominal wall was scanned about 5 cm cranial to the anterior superior iliac spine (Fig. 1). This region was chosen because the II nerve



**Fig 1** Transducer position for the ultrasound-guided II and IH nerve blocks. The arrow indicates the contact point of the transducer with the iliac crest.



**Fig 2** Ultrasound image obtained by the transducer position showed in Figure 1. 1, II nerve; 2, IH nerve; IC, iliac crest; SC, subcutaneous tissue; OE, external oblique muscle; OI, internal oblique muscle; TR, transversal abdominal muscle.

had penetrated the transversal abdominal muscle at this location with a probability of 90% and the IH nerve with a probability of 95%.<sup>13</sup> Both nerves may be found there with 90% probability between the transversal abdominal and internal oblique muscle<sup>13</sup> (Fig. 2). At this location,

all three muscles forming the abdominal wall, the third one being the external oblique muscle, can be seen by ultrasound. More distally the external oblique muscle forms its aponeurosis and is therefore thinner and more difficult to distinguish. We tested two linear array transducers with 10 and 7.5 MHz working frequencies, respectively (10L50 and 7.5L70). The transducers were positioned slightly rotated from a transversal to an oblique plane to be perpendicular to the anatomical course of both nerves and the lateral-caudal part of the transducers were brought into contact with the iliac crest (Fig. 1). The 7.5 MHz transducer provided a better result than the 10 MHz transducer because of the wider field of view and a better ultrasound picture, probably as a result of a better technical adjustment to the ultrasound device. It was therefore chosen for all further examinations. The II and IH nerve were seen and the transducer was slightly rotated until both nerves were scanned in a real cross-section view (Fig. 2). The nerves appeared as oval hypoechoic (dark) areas with hyperechoic (white) spots and were encircled by a hyperechoic horizon corresponding to the typical sonographic appearance of peripheral nerves.<sup>14–16</sup> Under real-time ultrasound guidance two 21 gauge, 8 cm, short bevel needles (0.80×80 mm, 21 G×3-1/8', ROSE GmbH, Trier, Germany) were inserted from slightly below the plane of view (caudal to the transducer in the short axis) directly over the II and IH nerve and were advanced directly to each nerve. The needle tips were brought in direct contact or into the nerves and either 0.3 or 0.1 ml of either indocyanine green (ICG) (ICG- Pulsion, Pulsion Medical Systems AG, Munich, Germany) or methylene blue (Methylene blue 1%, Mayrhofer Pharmazeutika GmbH, Linz, Austria) was injected. Thereafter, the cadaver was carefully dissected under manual fixation of the needles to show the actual position of the needle tips and the spread of the dye. ICG with a volume of 0.1 ml coloured the tissue around the needle tip in a very small area of about 1–2 mm whereas the higher volume and methylene blue with both volumes coloured less selectively. Therefore we used 0.1 ml of ICG for the remaining injections.

The remaining 10 cadavers were positioned supine and bilateral ultrasound examination of the inguinal region was performed by two examiners (U.E. and M.G.). The II and the IH nerve were seen and the pictures were saved. We recorded in or between which muscles the nerves were found. The dimensions of the nerves, the horizontal distance of the II nerve to the ultrasonographic reflex of the iliac crest and the distance between the two nerves were measured. Then, the

21 gauge needles were placed under real-time ultrasound guidance close or into each nerve on both sides as described above by one of the two examiners (U.E. and M.G.) and 0.1 ml of ICG were slowly injected through each needle. The needles were left in place and each cadaver was carefully dissected with manual fixation of the needles immediately after the injections by the independent anatomical specialist (B.M.). The needle position was defined as correct if the needle tip was in contact or into the targeted nerve, the green dye coloured the targeted nerve and this nerve corresponded anatomically to the II or the IH nerve, respectively.

## Results

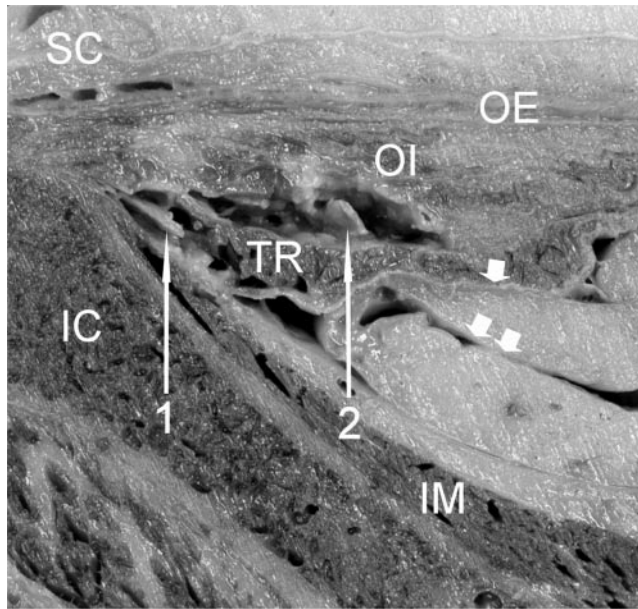
Of the 11 examined cadavers, the first one was categorized as pilot case to identify the type and volume of the dye. Data of this case are not included.

Characteristics of the remaining 10 corpses were: sex: 5 male, 5 female; median age at death 77.6 (range 62–90) yr; median height 165.1 (SD 7.2) cm and median BMI 20.6 (SD 2.9) kg m<sup>-2</sup>. In one cadaver it was not possible to get an accurate ultrasound image of the left side as a result of the gas between the muscles of the abdominal wall only at this side. In another one, the IH nerve on the left side could not be found either by ultrasound or by the subsequent dissection.

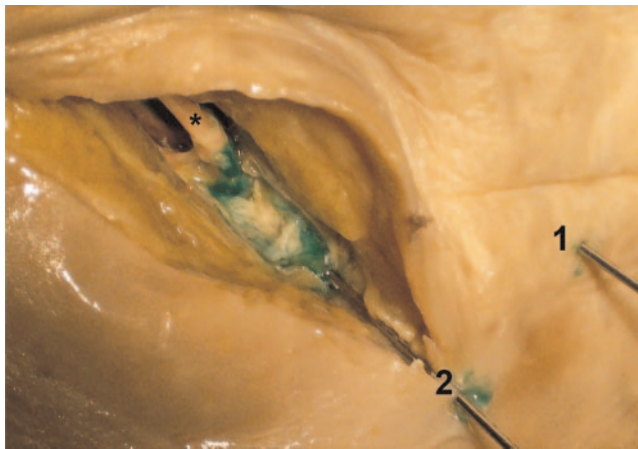
We targeted 37 nerves (19 II, 18 IH) in 10 cadavers. Results of the ultrasound measurements are shown in Table 1. We found all 37 nerves lying between the internal oblique and transverse abdominal muscles at the injection point described above. Figure 2 shows a typical ultrasound image of the abdominal wall and the two nerves. Figure 3 shows the corresponding anatomical cross-section through the region in the plane of the ultrasound image. Anatomical dissection after the injection showed the needle in or just on the targeted nerve in 33 cases (16 II, 17 IH) and the nerves were coloured green in all these cases (example: Fig. 4). In two cases the II nerve was divided into several branches and the needle tip was situated just next to one of these branches, which was coloured green whereas the main branch was not reached by the dye. In two cases (1 II, 1 IH) the nerves were missed by the needle tip and by the injected dye. The position of the dye was 5 mm medial and 2 mm superficial to the II nerve in the internal oblique muscle in one case. In the second case the dye was found 5 mm medial and cranial to the IH nerve colouring a branch of the subcostal nerve. In summary, 35

**Table 1** Ultrasound measurements of the II and IH nerve in 10 cadavers expressed as median and (range) in mm. The measurements of the nerves without verified correct needle placement by the following anatomical dissection were excluded. TD, transverse diameter; VD, vertical diameter; NBD, nerve bone distance, horizontal distance of the II nerve to the iliac bone reflex; NND, nerve to nerve distance between the II and IH nerve. The IH nerve always lay medial of the II nerve

	<i>n</i>	TD	VD	NBD	NND	Depth of nerve
II nerve	18	3.0 (2.0–4.0)	1.6 (0.7–2.1)	6.0 (4.0–11.0)		12.5 (8.2–19.0)
IH nerve	17	2. (1.8–3.5)	1.6 (0.5–3.0)		10.4 (7.0–14.3)	12.2 (8.6–19.4)



**Fig 3** Anatomical cross-section through the region in the plane of the obtained ultrasound image. IC, iliac crest; SC, subcutaneous tissue; OE, external oblique muscle; OI, internal oblique muscle; TR, transversal abdominal muscle; 1, II nerve; 2, IH nerve; IM, iliac muscle; single arrowhead, transversalis fascia; double arrowhead, peritoneum.



**Fig 4** A typical example of the injection site after the anatomical dissection. The nerve and the partial opened surrounding connective tissue and fat are coloured green. The needle tip is located directly on the II nerve. Asterisk, II nerve; 1, needle targeting the IH nerve; 2, needle targeting the II nerve.

of 37 targeted nerves were coloured by the injected dye. Thus, the success rate of needle placement and nerve colouring was 95% (95% confidence interval: 84–98%).

## Discussion

This investigation is the first description of an ultrasound-guided approach to the II and IH nerve in adults. This

method is the first one with the potential to block the two nerves selectively and separately. We demonstrated the accuracy of our ultrasound-guided approach: the success rate of needle placement and nerve colouring of our new technique was 95%.

We suggest using our new injection point about 5 cm cranial and posterior to the anterior superior iliac spine for ultrasound-guided or ‘blind’ blocks of the II and IH nerves. At this point all three muscle layers of the abdominal wall can easily be identified by ultrasound and facilitate orientation (Fig. 2). We found all 37 nerves lying between the internal oblique and transversal abdominal muscle. This is in accordance with the anatomical findings of Jamieson and colleagues.<sup>13</sup> They dissected 244 human body halves and found both nerves in more than 90% of cases between these two muscles in the region above and posterior to the anterior superior iliac spine. They postulated this region as ideal injection point for performing anaesthetic blocks of the nerves as early as 1952 but their suggestion was not followed by the anaesthetic literature. In all descriptions of the technique that we know, the recommended injection site is situated medial of the anterior superior iliac spine.<sup>3–6</sup> At this place, both nerves, the II nerve with a higher frequency, are often penetrating the internal oblique muscle.<sup>13</sup> Performing a ‘blind’ technique it may be difficult for the injected local anaesthetic, in adults up to 20 ml, to reach both nerves if they are not lying in the same compartment. This is a possible explanation for the high failure rates of 20–30% reported in the literature<sup>2</sup> for this technique. It is more likely to reach both nerves with the local anaesthetic using an injection point where the nerves are lying in the same layer of the abdominal wall with a high probability.

Because our study was performed on cadavers of low BMI, we cannot say whether the results are applicable to the general population because of the more difficult nerve visualization in overweight patients. However, in our daily practice the muscle layers are seen consistently also in overweight patients, which makes this method most likely more reliable and safe than the traditional blind technique.

Recently, an unselective ultrasound-guided technique for II and IH nerve blocks in children just medial to the anterior superior iliac spine was described by Willschke and colleagues.<sup>7</sup> The authors could significantly reduce the volume of local anaesthetic to achieve an appropriate block and the intra- and postoperative requirements for additional analgesics was significantly lower in the ultrasound-guided nerve block group compared with the traditional ‘blind’ fascia click method. The advantage of performing an ultrasound-guided injection at our injection point cranial and posterior of the anterior superior iliac spine is the better visibility of the nerves at this point. Both nerves are usually not yet divided and therefore greater in diameter. In our study, we could not see all nerves medial or caudal to the anterior superior iliac spine. In the only case we could not

find the IH nerve on the left side either by ultrasound or by dissection, we assume that the two nerves (II and IH) existed as a common trunk at the investigated location. This is a known anatomic variation and was found by Papadopoulos and Katritsis<sup>17</sup> in 12.6% of 348 investigated specimens. By using an ultrasound-guided block technique such anatomical variations can be detected and this may be one reason for the increase of success rate of the block compared with the blind method.

Our technique may open new possibilities in pain medicine. Considering the high incidence of chronic pain after inguinal herniorrhaphy<sup>8</sup> and the high number of operations performed,<sup>9</sup> more effective treatment of patients suffering from chronic pain after inguinal hernia repair is highly needed. The mechanisms of the development of this pain state are still unclear. Entrapment neuralgia or injury of the nerves crossing the inguinal region followed by neuroma formation are possible explanations. Anatomical variability of the course of these nerves<sup>13,17</sup> and the distribution of the sensory innervated skin area are very high.<sup>18</sup> Therefore it is impossible to find out which nerve is involved in pain generation just by performing sensory tests or mapping the painful skin area. Regional local anaesthetic blocks may be performed as diagnostic tools to distinguish whether nerves or the tissues that are supplied by them are involved in pain generation, before surgical revision<sup>19</sup> or neurodestructive procedures are performed.<sup>20,21</sup> With this study we cannot prove that we are able to block the II and the IH nerve separately using ultrasound guidance in pain patients. Because there is a high variability of the skin innervation,<sup>18</sup> no accurate clinical test exists to evaluate which nerve is blocked. Therefore it is very difficult to prove that only one nerve is blocked after the injection of a small amount of local anaesthetic and this topic has to be the subject of further studies. Nevertheless we suggest using the ultrasound-guided approach, which may allow blocking the II and IH nerve selectively and may lead to a more accurate pre-selection of chronic pain patients after inguinal hernia repair for invasive pain treatment. In patients it is very important to avoid nerve injury and therefore we advance the needle ultrasound-guided just beside the nerves and do not directly target them in contrast to our cadaver study. For physicians with only limited experience in ultrasound-guided nerve blocks we furthermore recommend to combine the technique with a nerve stimulator to ensure the needle is not put too close to or into the nerve. To block the II nerve we place the needle lateral to it to enlarge the distance from the injection point to the IH nerve. In this way, we reduce the chance that the second nerve is reached by the injected local anaesthetic too. For the same reason, to block the IH nerve the needle is placed medial to it. The injection of 1–2 ml of local anaesthetic under direct ultrasound visualization is usually enough to surround only the targeted nerve by the solution.

In conclusion, the results of this study are an encouraging first step that others might care to follow and evaluate. The

ultrasound approach has the potential to replace the ‘blind’ standard techniques of II and IH nerve block in pain medicine and anaesthetic practice where ultrasound facilities and expertise are available. In facilities without ultrasound equipment using a ‘blind’ technique, a new injection point cranial and posterior of the anterior superior iliac spine may be advantageous and may reduce the failure rates. One caution, however, remains. This study was conducted on cadavers of average size and normal or lower weight. Whether or not the method is applicable to larger individuals is still uncertain. Moreover, whether the two nerves can be blocked separately for diagnostic reasons has still to be determined by future studies.

## References

- Lipp AK, Woodcock J, Hensman B, Wilkinson K. Leg weakness is a complication of ilio-inguinal nerve block in children. *Br J Anaesth* 2004; **92**: 273–4
- Lim SL, Ng Sb A, Tan GM. Ilioinguinal and iliohypogastric nerve block revisited: single shot versus double shot technique for hernia repair in children. *Paediatr Anaesth* 2002; **12**: 255–60
- Ecoffey C. Regional anesthesia in children. In: Raj PP, ed. *Textbook of Regional Anesthesia*. Philadelphia: Churchill Livingstone, 2002; 379–93
- Kopacz DL, Thompson GE. Celiac and hypogastric plexus, intercostal, interpleural and peripheral neural blockade of the thorax and abdomen. In: Cousins MJ, Bridenbaugh PO, eds. *Neural Blockade in Clinical Anesthesia and Management of Pain*. Philadelphia: Lipincott, 1998; 451–85
- Reynolds L, Kedlaya D. Ilioinguinal-iliohypogastric and genitofemoral nerve blocks. In: Waldman SD, ed. *Interventional Pain Management*. Philadelphia: WB Saunders, 2001; 508–11
- Waldman SD. Ilioinguinal and iliohypogastric nerve block. In: Waldman SD, ed. *Atlas of Interventional Pain Management*. Philadelphia: Saunders, 2004; 294–301
- Willschke H, Marhofer P, Bosenberg A, *et al.* Ultrasonography for ilioinguinal/iliohypogastric nerve blocks in children. *Br J Anaesth* 2005; **95**: 226–30
- Poobalan AS, Bruce J, Smith WC, King PM, Krukowski ZH, Chambers WA. A review of chronic pain after inguinal herniorrhaphy. *Clin J Pain* 2003; **19**: 48–54
- Rutkow IM. Demographic and socioeconomic aspects of hernia repair in the United States in 2003. *Surg Clin North Am* 2003; **83**: 1045–51, v–vi
- Marhofer P, Greher M, Kapral S. Ultrasound guidance in regional anaesthesia. *Br J Anaesth* 2005; **94**: 7–17
- Greher M, Kirchmair L, Enna B, Kovacs P, Gustorff B, Kapral S, Moriggl B. Ultrasound-guided lumbar facet nerve block: accuracy of a new technique confirmed by computed tomography. *Anesthesiology* 2004; **101**: 1195–200
- Greher M, Scharbert G, Kamolz LP, Beck H, Gustorff B, Kirchmair L, Kapral S. Ultrasound-guided lumbar facet nerve block: a sonoanatomic study of a new methodologic approach. *Anesthesiology* 2004; **100**: 1242–8
- Jamieson RW, Swigart LL, Anson BJ. Points of parietal perforation of the ilioinguinal and iliohypogastric nerves in relation to optimal sites for local anaesthesia. *Q Bull Northwest Univ Med Sch* 1952; **26**: 22–6

- 14** Fornage BD. Peripheral nerves of the extremities: imaging with US. *Radiology* 1988; **167**: 179–82
- 15** Silvestri E, Martinoli C, Derchi LE, Bertolotto M, Chiaramondia M, Rosenberg I. Echotexture of peripheral nerves: correlation between US and histologic findings and criteria to differentiate tendons. *Radiology* 1995; **197**: 291–6
- 16** Martinoli C, Bianchi S, Dahmane M, Pugliese F, Bianchi-Zamorani P, Valle M. Ultrasound of tendons and nerves. *Eur Radiol* 2002; **12**: 44–55
- 17** Papadopoulos NJ, Katritsis ED. Some observations on the course and relations of the iliohypogastric and ilioinguinal nerves (based on 348 specimens). *Anat Anz* 1981; **149**: 357–64
- 18** Rab M, Ebmer Dellon AL. Anatomic variability of the ilioinguinal and genitofemoral nerve: implications for the treatment of groin pain. *Plast Reconstr Surg* 2001; **108**: 1618–23
- 19** Starling JR, Harms BA, Schroeder ME, Eichman PL. Diagnosis and treatment of genitofemoral and ilioinguinal entrapment neuralgia. *Surgery* 1987; **102**: 581–6
- 20** Krahenbuhl L, Striffeler H, Baer HU, Buchler MW. Retroperitoneal endoscopic neurectomy for nerve entrapment after hernia repair. *Br J Surg* 1997; **84**: 216–19
- 21** Fanelli RD, DiSiena MR, Lui FY, Gersin KS. Cryoanalgesic ablation for the treatment of chronic postherniorrhaphy neuropathic pain. *Surg Endosc* 2003; **17**: 196–200