

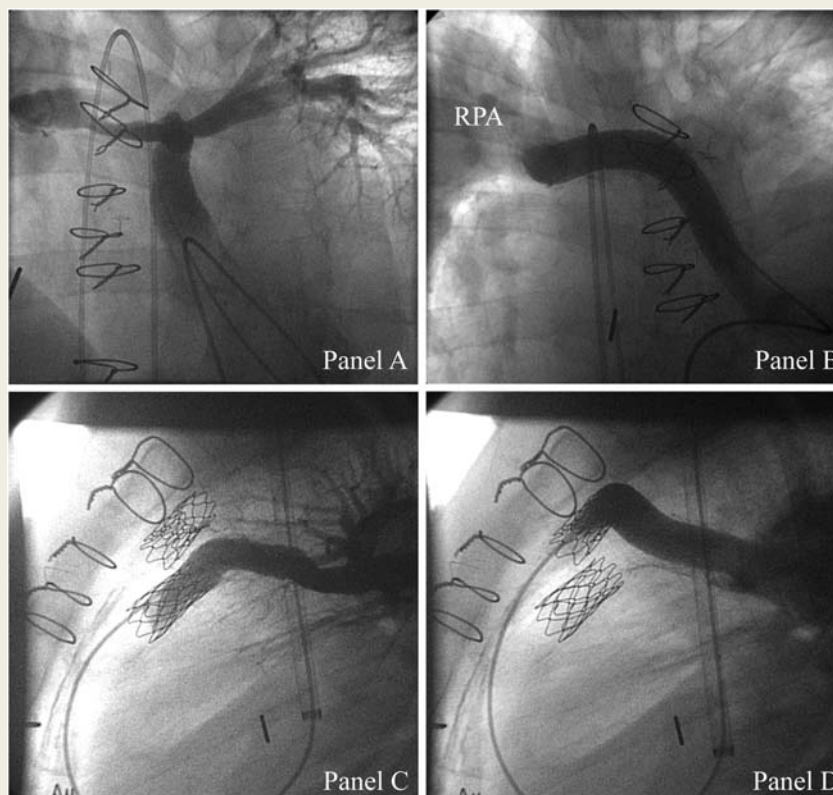
CARDIOVASCULAR FLASHLIGHT

doi:10.1093/eurheartj/ehr234

Online publish-ahead-of-print 21 July 2011

Bilateral percutaneous pulmonary valve implantation in dual conduits from the subpulmonary ventricle to the pulmonary arteries**Michael Hofbeck^{1*}, Oliver Kretschmar², and Ludger Sieverding¹**¹Department of Pediatric Cardiology, University Children's Hospital, Hoppe-Seyler-Strasse 1, D-72076 Tuebingen, Germany and ²Department of Congenital Heart Disease and Pediatric Cardiology, University Children's Hospital, Zürich, Switzerland* Corresponding author. Tel: +49 7071 2984751, Fax: +49 7071 295127, Email: michael.hofbeck@med.uni-tuebingen.de

Percutaneous pulmonary valve implantation (PPVI) of bovine valves mounted in a stent (Melody[®], Medtronic) has become a well-established therapy in patients with significant dysfunction of conduits between the right ventricle and the pulmonary arteries. Increasing experience with this technique has allowed to extend the limits of application. We report PPVI in a 32-year-old patient who was referred with heart failure due to complex congenital heart disease including atrial situs inversus, double discordance of atrioventricular and ventriculoarterial connexions, and pulmonary atresia. At the age of 13 and 20 years, he had undergone surgery with interposition of 18 and 14 mm valveless Goretex conduits between the subpulmonary ventricle and the pulmonary arteries. Reevaluation revealed severe obstruction of the first conduit at the bifurcation (*Panel A*; see supplementary video 1) which was treated by stent implantation and severe regurgitation of the second conduit connecting to the right pulmonary artery (*Panel B*; see supplementary video 2).



Since repeat surgery would have been associated with significant risk, bilateral PPVI appeared as an attractive alternative. The procedure was performed under general anaesthesia. We chose a jugular venous approach to obtain a better angle to enter the pulmonary artery conduits. The jugular vein was dilated with dilators up to 22 Fr and both Melody[®] valves were implanted subsequently using 18 mm delivery systems. Angiographies following deployment showed competence of both pulmonary valves with substantial improvement of flow to both pulmonary arteries (*Panels C and D*; see supplementary videos 3 and 4).

According to our experience, PPVI can be performed safely from a jugular approach with good valve function even in non-distensible conduits as small as 14 mm.

Panel A. Injection into the 18 mm tube graft shows significant distal obstruction treated subsequently by stent implantation.

Panel B. Angiography into the 14 mm tube graft shows severe pulmonary regurgitation and aneurysmal dilatation of the right pulmonary artery (RPA).

Panel C. Angiography into the 18 mm tube graft (lateral view) following percutaneous pulmonary valve implantation shows a competent pulmonary valve.

Panel D. Competent pulmonary valve of the 14 mm tube graft despite percutaneous pulmonary valve implantation in this undersized localization.

Supplementary materialSupplementary material is available at *European Heart Journal* online.Published on behalf of the European Society of Cardiology. All rights reserved. © The Author 2011. For permissions please email: journals.permissions@oup.com.