

Distinct illusory own-body perceptions caused by damage to posterior insula and extrastriate cortex

Lukas Heydrich^{1,2,3} and Olaf Blanke^{1,2,3}

1 Center for Neuroprosthetics, School of Life Sciences, Ecole Polytechnique Fédérale de Lausanne, 1015 Lausanne, Switzerland

2 Laboratory of Cognitive Neuroscience, Brain-Mind Institute, School of Life Sciences, Ecole Polytechnique Fédérale de Lausanne, 1015 Lausanne, Switzerland

3 Department of Neurology, University Hospital Geneva, 1205 Geneva, Switzerland

Correspondence to: Olaf Blanke,
Bertarelli Foundation Chair in Cognitive Neuroprosthetics,
Center for Neuroprosthetics and Brain Mind Institute,
School of Life Sciences,
Ecole Polytechnique Fédérale de Lausanne (EPFL),
1015 Lausanne,
Switzerland
E-mail: olaf.blanke@epfl.ch

Recent research in cognitive neuroscience using virtual reality, robotic technology and brain imaging has linked self-consciousness to the processing and integration of multisensory bodily signals. This work on bodily self-consciousness has implicated the temporo-parietal, premotor and extrastriate cortex and partly originated in work on neurological patients with different disorders of bodily self-consciousness. One class of such disorders is autoscopic phenomena, which are defined as illusory own-body perceptions, during which patients experience the visual illusory reduplication of their own body in extra-personal space. Three main forms of autoscopic phenomena have been defined. During autoscopic hallucinations, a second own body is seen without any changes in bodily self-consciousness. During out-of-body experiences, the second own body is seen from an elevated perspective and location associated with disembodiment. During heautoscopy, subjects report strong self-identification with the second own body, often associated with the experience of existing at and perceiving the world from two places at the same time. Although it has been proposed that each autoscopic phenomenon is associated with different impairments of bodily self-consciousness, past research on neurological patients and the development of experimental paradigms for the study of bodily self-consciousness has focused on out-of-body experiences and the association with temporo-parietal cortex. Here, we performed quantitative lesion analysis in the—to date—largest group of patients with autoscopic hallucination and heautoscopy and compared the location of brain damage with those of control patients suffering from complex visual hallucinations. We found that heautoscopy was associated with lesions to the left posterior insula, and that autoscopic hallucinations were associated with damage to the right occipital cortex. Autoscopic hallucination and heautoscopy were further associated with distinct symptoms and deficits. The present data suggest that the autoscopic hallucination is a visuo-somatosensory deficit implicating extrastriate cortex and is, despite the visual hallucination of the own body, not associated with major deficits in bodily self-consciousness. Based on the symptoms and deficits in patients with heautoscopy and the implication of the left posterior insula, we suggest that abnormal bodily self-consciousness during heautoscopy is caused by a breakdown of self–other discrimination regarding affective somatosensory experience due to a disintegration of visuo-somatosensory signals with emotional (and/or interoceptive) bodily signals. These brain mechanisms are distinct from those described for out-of-body experiences. The present data extend previous models of autoscopic phenomena and provide

Received June 13, 2012. Revised September 28, 2012. Accepted November 23, 2012

© The Author (2013). Published by Oxford University Press on behalf of the Guarantors of Brain. All rights reserved.

For Permissions, please email: journals.permissions@oup.com

clinical evidence for the importance of emotional and interoceptive signal processing in the posterior insula in relation to bodily self-consciousness.

Keywords: autoscopic phenomena; lesion analysis; posterior insula; multisensory integration; embodiment; bodily self-consciousness

Introduction

Autoscopic phenomena [from the Greek *autos* (self) and *skopeo* (looking at)] are dramatic illusory own-body perceptions and encompass a wide range of experiences involving the visual illusory reduplication of one's own body in extrapersonal space. Three main forms of autoscopic phenomena have been defined, and these include out-of-body experiences (Blanke *et al.*, 2004; Brandt *et al.*, 2005; De Ridder *et al.*, 2007; Heydrich *et al.*, 2011), autoscopic hallucinations (Maillard *et al.*, 2004; Zamboni *et al.*, 2005; Blanke *et al.*, 2008) and heautoscopy (Brugger *et al.*, 1994, 2006; Tadokoro *et al.*, 2006). Although autoscopic phenomena have been reported in various focal and generalized disorders of the CNS for a long time (Menninger-Lerchenthal, 1946), they have only recently been investigated with the modern tools of cognitive neuroscience and neurology (Easton *et al.*, 2009; Bolognini *et al.*, 2010).

During an out-of-body experience, the patient has the subjective feeling of being awake and experiences the 'self' or centre of awareness, as being located outside the physical body, at a somewhat elevated level (abnormal self-location). It is from this elevated extrapersonal location that the patient's body and the world are perceived (abnormal first-person perspective) (Devinsky *et al.*, 1989; Brugger, 2002; Blanke *et al.*, 2004). Most patients experience seeing their own body (autoscopy) as lying on the ground or in bed, and the experience tends to be described as vivid and realistic. Thus, self-identification with a body, that is the sensation of owning a body, is experienced at the elevated disembodied location and not at the location of the physical body (abnormal self-identification) (Table 1).

Out-of-body experiences have been reported in patients suffering from many different aetiologies (Devinsky *et al.*, 1989; Brugger, 2002; Blanke *et al.*, 2004). A recent lesion analysis

study using voxel-based lesion symptom mapping in the—to date—largest sample of patients with out-of-body experiences due to focal brain damage, however, revealed a well-localized origin centred at the right angular gyrus and posterior superior temporal gyrus (Ionta *et al.*, 2011). Based on the frequent association of out-of-body experiences with visuo-somatosensory illusions, abnormal vestibular sensations (Blanke and Mohr, 2005; Lopez *et al.*, 2008) and the role of the temporo-parietal junction in multisensory integration (Calvert *et al.*, 2000; Bremmer *et al.*, 2001), it has been suggested that out-of-body experiences occur owing to disturbed multisensory integration of bodily signals in personal (somatosensory, visual and proprioceptive) and extrapersonal space (visual and vestibular) (Blanke *et al.*, 2004; Ionta *et al.*, 2011).

Because past research on autoscopic phenomena has mostly focused on out-of-body experiences, the neurological mechanisms of autoscopic hallucination and heautoscopy are less well understood. During autoscopic hallucination, patients experience seeing an image of their body in extrapersonal space as if they were looking into a mirror, while self-location, self-identification and the first-person perspective remain unaffected (Table 1) (Féré, 1891; Brugger, 2002). Autoscopic hallucinations are mostly of brief duration (for exception, see Zamboni *et al.*, 2005), often accompanied by visual hallucinations or visual illusions, and associated with visual field deficits (Kölmel, 1985; Blanke and Mohr, 2005) that may be lateralized to the affected visual field (Kölmel, 1985). Moreover, patients often experience seeing their own face or the upper part of the trunk and only rarely their entire body (Blanke and Castillo, 2007).

Autoscopic hallucinations due to various neurological disorders such as migraine (Lippman, 1953) and focal epilepsy (Blanke *et al.*, 2004; Maillard *et al.*, 2004), as well as ischaemic and neoplastic brain damage of the occipital and/or occipito-parietal lobe

Table 1 Classification criteria for heautoscopy, out-of-body experience and autoscopic hallucinations, as well as lesion location suggested by previous case reports and small case series

	Autoscopic hallucination	Out-of-body experience	Heautoscopy
Self-location	Centred at physical body, stable	Centred at illusory body, stable	Centred at physical and/or illusory body, unstable
Self-identification	With physical body	With illusory body	With physical and/or illusory body
First-person perspective	Centred at physical body, stable	Centred at illusory body, stable	Centred at physical and/or illusory body, unstable
Second own body (autoscopic body)	2D image of own body, often of the face and upper trunk	3D image of whole own body	3D image of whole own body
Vividness/realism	Low	High	High
Lesion location	Bilateral, occipital, temporal	Right, temporal, parietal	Left, temporal, parietal

(Maillard *et al.*, 2004; Zamboni *et al.*, 2005), have been reported. Based on the frequent association with visual field deficits and other visual hallucinations, it has been argued that autoscopic hallucinations are a visual disorder (Féré, 1891; Sollier, 1903; Menninger-Lerchenthal, 1935; Hécaen and Ajuriaguerra, 1952), and several dysfunctional visual or vision-related mechanisms have been proposed: abnormal visual imagery (Coleman, 1934), hypnagogic visual hallucination (Lukianowicz, 1958), aberrant plasticity after cortical damage in the early visual cortex (Zamboni *et al.*, 2005) or a release phenomenon (Devinsky *et al.*, 1989). More recently, it has been proposed that autoscopic hallucinations are a disorder of multisensory integration in personal space (due to conflicting cortical signal integration from vision, proprioception and touch) (Blanke *et al.*, 2004; Maillard *et al.*, 2004; Bolognini *et al.*, 2010).

The third form of autoscopic phenomenon is heautoscopy and has been conceptualized as an intermediate form between autoscopic hallucinations and out-of-body experience. As in out-of-body experiences and autoscopic hallucinations, the patient with heautoscopy has the impression of seeing an image of his body in extrapersonal space. However, it is often difficult for the patient with heautoscopy to decide whether they are disembodied and whether the centre of conscious experience is localized within the physical body or the autoscopic body (Table 1) (Blanke *et al.*, 2004). This is associated with strong self-identification and close affinity with the autoscopic body (Devinsky *et al.*, 1989; Brugger, 2002; Blanke and Mohr, 2005), which may even persist if the autoscopic body only partly reflects the patient's visual bodily appearance (Brugger, 2002; Blanke and Mohr, 2005). It has been argued that such illusory self-identification may be related to the frequent report of echopraxia [e.g. the experienced imitation of the patient's movements by the autoscopic body (Lukianowicz, 1958; Brugger *et al.*, 2006)] or feelings of detachment from emotional and bodily processing concerning the patient's physical body (Menninger-Lerchenthal, 1935; Lukianowicz, 1958; Devinsky *et al.*, 1989; Brugger, 2002).

A further difference exists between heautoscopy with respect to out-of-body experiences and autoscopic hallucinations; patients with heautoscopy may report to experience existing at two places at the same time (bi-location), often associated with alternating or simultaneous self-locations and first-person perspectives at the physical and the autoscopic body (Sollier, 1903; Brugger *et al.*, 1994; Brugger, 2002; Blanke *et al.*, 2004). Heautoscopy has also been linked to various neurological (Lippman, 1953; Blanke *et al.*, 2004) and psychiatric conditions (Lukianowicz, 1958, 1963). These include temporal lobe epilepsy (Devinsky *et al.*, 1989; Brugger *et al.*, 1994; Tadokoro *et al.*, 2006), neoplasia originating in the insular cortex (Brugger *et al.*, 2006), typhoid fever (Féré, 1891; Menninger-Lerchenthal, 1946), migraine (Lippman, 1953), schizophrenia (Lukianowicz, 1963) and depression (Lukianowicz, 1958; Arenz, 2001). Functionally, many hypotheses have been proposed, suggesting that heautoscopy represents a vestibular disorder (Bonnier, 1905; Ionasescu, 1960; Menninger-Lerchenthal, 1961; Grüsser and Landis, 1991), aberrant visual memory (Dewhurst and Pearson, 1955), dissociative disease (Devinsky *et al.*, 1989) and descriptive psychological accounts such as externalization of the 'somatic ego' (Lunn, 1970),

projection of suppressed desires (Féré, 1891) or pathological grief reaction (Menninger-Lerchenthal, 1935).

Recent models account for heautoscopy, autoscopic hallucinations and out-of-body experiences within a common model, proposing that heautoscopy is based on abnormal integration of multisensory signals in personal space (as mentioned earlier in the text) as well as extrapersonal space (of visuo-vestibular signals) (Blanke *et al.*, 2004, 2008). However, we note that these accounts of heautoscopy and autoscopic hallucinations are almost entirely based on single case reports (Brugger *et al.*, 1994, 2006; Arenz, 2001; Zamboni *et al.*, 2005) or small case series (Féré, 1891; Devinsky *et al.*, 1989; Blanke *et al.*, 2004). Moreover, data regarding the exact lesion location of autoscopic hallucinations and heautoscopy are missing because, to date, no quantitative lesion analysis [e.g. lesion overlap, voxel-based lesion symptom mapping (Bates *et al.*, 2003; Rorden *et al.*, 2007)] has been carried out.

Major advances in lesion analysis have permitted us to analyse, with high spatial resolution, whether symptoms are associated with circumscribed brain regions. These approaches are based on statistical analysis at the group level and voxel-wise quantitative statistical analysis (Bates *et al.*, 2003; Rorden *et al.*, 2007; Ionta *et al.*, 2011). Here, we performed quantitative lesion analysis using MRICron (<http://www.sph.sc.edu/comd/rorden/mricron>) (Rorden *et al.*, 2007) and compared the distribution of brain lesions in the—to date—largest sample of patients with heautoscopy and with autoscopic hallucinations with those of control patients. This was combined with an in-depth analysis of several phenomenological aspects and neurological deficits in patients with heautoscopy and autoscopic hallucinations.

Based on earlier work (Blanke and Mohr, 2005) and differences in associated symptoms, we had three major predictions concerning brain damage. We hypothesized that autoscopic hallucinations and heautoscopy would be caused by damage to distinct brain regions (lesion overlap analysis). Moreover, given the strong alteration of bodily self-consciousness in heautoscopy (abnormal self-location, self-identification and first-person perspective), we predicted that brain damage in patients with heautoscopy will be significantly different from that in our control group of patients with complex visual hallucinations but preserved bodily self-consciousness, and affects regions in proximity to those recently described in abnormal states of bodily self-consciousness (Ionta *et al.*, 2011). Finally, we hypothesized that the lesion overlap in patients with autoscopic hallucinations will not differ from that in a control group, as patients with autoscopic hallucinations and the control group both suffer from frequent visual symptoms and have preserved bodily self-consciousness.

Patients and methods

Patients

We included nine patients suffering from heautoscopy (mean age: 37.8 years, four female, all right handed) and seven patients suffering from autoscopic hallucinations (mean age: 33.8 years, four female, all right-handed) due to circumscribed structural brain lesions and/or

Table 2 Patient characteristics in patients with heautoscopy

Patient	Diagnosis	Lesion site	Lesion side	Lesion analysis
HAS 1	Epilepsy (dysembryoblastic tumour)	Temporal lobe, insula	Left	MRI, EEG, PET
HAS 2	Epilepsy	Temporal lobe, insula	Left	MRI, iEEG
HAS 3	Epilepsy (dysembryoblastic tumour)	Temporal lobe, mesio-basal	Left	MRI, EEG, PET ^a
HAS 4	Epilepsy (focal dysplasia, after resection)	Temporo-parietal lobe, insula	Left	MRI, iEEG
HAS 5	Migraine (atrophy)	Parieto-occipital lobe	Bilateral	MRI
HAS 6	Epilepsy (lesional)	Insula and temporo-parieto-occipital lobe	Left	MRI, EEG
HAS 7	Epilepsy (astrocytoma)	Temporal lobe, insula	Right	CT, MRI, EEG, PET ^a
HAS 8	Epilepsy (astrocytoma)	Temporal lobe, insula	Left	CT, EEG ^a
HAS 9	Epilepsy (hippocampal sclerosis)	Temporal lobe, mesial	Left	MRI, SPECT ^a

^a Enough imaging data were available for accurate tracing onto a normalized standard template brain. No normalization of the original data was possible in these cases. iEEG = intracranial electroencephalography; SPECT = single-photon emission computed tomography.

Table 3 Patient characteristics in patients with autoscopic hallucination

Patient	Diagnosis	Lesion site	Lesion side	Lesion analysis
AH 1	Epilepsy (glioblastoma)	Parieto-occipital lobe	Left	MRI, EEG
AH 2	Epilepsy (focal dysplasia)	Parietal lobe	Right	MRI, EEG
AH 3	Ischaemic lesion (eclampsia)	Occipital lobe	Right	MRI
AH 4	Epilepsy (parasitical lesion)	Occipital lobe	Right	MRI, EEG
AH 5	Epilepsy (intracerebral haematoma)	Parieto-occipital lobe	Right	MRI, EEG ^a
AH 6	Epilepsy (oligodendroglioma)	Occipital lobe	Right	MRI, EEG ^a
AH 7	Tumour (postoperative lesion)	Occipital lobe	Right	MRI

^a Enough imaging data were available for accurate tracing onto a normalized standard template brain. No normalization of the original data was possible in these cases.

localized neural dysfunction due to focal epilepsy (Tables 2 and 3). Inclusion criteria were that heautoscopy or autoscopic hallucinations of neurological origin were caused by either focal brain damage (measured with MRI or CT) or a circumscribed zone of seizure onset (confirmed by intracranial EEG recording). Furthermore, we required the availability of a sufficient amount of detail about the autoscopic hallucinations or heautoscopy so that they could be classified with certainty. The patients were recruited at the Department of Neurology at Geneva University Hospital or from other clinical research groups, where the original neuroradiological data were available for analysis. Several of the patients have been reported previously by different authors in the form of case reports or small case series (Brugger *et al.*, 1994, 2006; Maillard *et al.*, 2004; Zamboni *et al.*, 2005; Tadokoro *et al.*, 2006; Bolognini *et al.*, 2010).

The control group consisted of 14 patients with complex visual hallucinations who were recruited during the same time period at the Geneva University Hospital (Supplementary Table 1). Complex visual hallucinations consisted of people and/or faces without disturbance of bodily self-consciousness (normal self-location, self-identification and first-person perspective) and were also due to circumscribed brain lesions.

Classification of autoscopic phenomena

Based on the criteria used previously (Brugger, 2002; Blanke and Mohr, 2005), we classified cases as having heautoscopy or autoscopic hallucinations based on the available data concerning the first-person perspective (e.g. from where the patients reported to perceive the world), self-location (e.g. the location in space where the patients

experience to be) and self-identification (e.g. the degree to which the patients identify with a body).

Phenomenology and associated symptoms

We assessed the phenomenology of heautoscopy and autoscopic hallucinations and, if reported, the presence of mirror-reversal of the autoscopic body and scene, as well as echopraxia. We further analysed the associated symptoms, such as visceral sensations (nausea, vomiting, palpitations), vestibular sensations (rotation, sensation of falling or flying, lightness and heaviness), visual field deficits and simple visual hallucinations (e.g. colours, light flashes), somatosensory deficits and associated emotions. Results of an extensive neuropsychological examination were also analysed (Blanke *et al.*, 2004).

Lesion mapping and spatial normalization

Brain pathology was confirmed using a multimodality imaging approach relying on a combination of MRI ($n = 28$, 93%), CT ($n = 4$, 13%), ictal and interictal scalp EEG ($n = 14$, 46%), intracranial EEG using subdural electrodes ($n = 2$, 6%), PET ($n = 8$, 26%), ictal and/or interictal single-photon emission computed tomography ($n = 4$, 13%) and/or intracranial electric stimulation ($n = 3$, 10%, Tables 1 and 2 and Supplementary Table 1) (Knowlton, 2004; Kurian *et al.*, 2007). MRI brain scans were normalized to the smoothed T₁ template using SPM5 (<http://www.fil.ion.ucl.ac.uk/spm/software/spm5>) (Ashburner and Friston, 2005). As unified segmentation models give

the most precise registration of lesioned structural images (Crinion *et al.*, 2007), no cost-function masking was necessary. Functional imaging (PET, single-photon emission computed tomography) was normalized using SPM5 and co-registered to the normalized MRI scans. Intracranial electrodes were co-registered to the normalized MRI scans for each patient using the Cartool software developed by Denis Brunet (<http://brainmapping.unige.ch/Cartool.htm>). Lesions were subsequently traced manually, slice by slice, either on the individual normalized brain scans or on the T₁-weighted images using MRICron (Rorden *et al.*, 2007). The manual tracing on the template brain was only done when confidence could be achieved for matching corresponding slices between the lesioned brain and the template brain. Thus, structural lesions were analysed by MRI, and if MRI was not available, by CT.

In a few patients, intracranial electrical stimulation and intracranial recordings were available and used to localize the seizure onset zone (Patient HAS 2 and Controls 1, 2 and 11). In this group of patients, the lesion site was defined as the location of the implanted electrodes (on the standard T₁ template) where the seizure onset was found (plus an additional radius of 10 mm around the ictal onset zone). No patients with unclear lesion boundaries, generalized seizures or metallic artefacts were included in the analysis. Lesion volumes (volume of interest) were determined as the sum of all voxels comprising the traced lesion in all slices and were spatially smoothed using a 5-mm full-width at half-maximum Gaussian kernel and a threshold of 0.5.

Lesion overlap and statistical analysis

For lesion overlap and statistical analysis, we used MRICron and non-parametric mapping, which is part of the MRICron software package (Rorden *et al.*, 2007). In a first step, simple voxel-based lesion overlap analysis establishing the anatomical subregions of maximal lesion overlap for heautoscopy and autoscopic hallucinations was performed. In a second step, non-parametric voxel-based lesion symptom mapping analysis (Bates *et al.*, 2003), contrasting autoscopic hallucinations and heautoscopy against the control group, was performed on the hemisphere that was significantly more often affected (as confirmed by the binomial test, see later in the text). The control group was matched for the hemispheric predominance and the cerebral vascular territories, as defined by the lesion overlap (e.g. left anterior for heautoscopy and right posterior for autoscopic hallucinations). We used the Lieberman test and corrected the results for multiple comparisons using a 5% false discovery rate (FDR). The Lieberman test is a non-parametric implementation of a two-group comparison on a binary variable. It is more appropriate than the χ^2 test (Rorden *et al.*, 2007). We only included voxels affected in at least 30% for all subsequent analyses. Right versus left hemispheric involvement was tested with a binomial distribution, with an expected frequency of 0.5.

The distribution of phenomenological data and associated symptoms and neurological findings was analysed using the χ^2 test and the Fisher exact test, respectively (Blanke and Mohr, 2005).

Results

Phenomenology

For illustration, several characteristic clinical, phenomenological and neuroradiological findings are described for two patients with heautoscopy and two patients with autoscopic hallucinations.

Details for the remaining patients are in the online Supplementary material.

Heautoscopy

Patient 1

Patient 1 was a 44-year-old right-handed man known for pharmaco-resistant epilepsy and complex partial seizures. Neurological examination was normal. Interictal EEG showed slow waves with spikes over the left anterior and medial temporal region. Ictal EEG showed a seizure onset in the left anterior and medial temporal lobe. CT and MRI revealed a cystic lesion in the left temporal lobe, including parts of the left insula, enhancing contrast medium in its posterior parts. A dysembryoblastic tumour was diagnosed (see Fig. 1A for individual lesion analysis).

The episodes always started with an epigastric aura and a sensation of intense fear. He then saw a man in his right visual field. Although vision was blurred, the patient could tell that this man was very familiar to him. The man spoke in an incomprehensible way, while the patient (according to his relatives) suffered from language problems at these moments. The patient reported that he increasingly felt that the man he was seeing was himself. He felt as if he was 'duplicated' (abnormal self-identification). During the full episode, the patient did not experience abnormal self-location and always experienced to perceive the world and the autoscopic body from the normal first-person perspective. Postictally, the patient was depressed and often cried.

Patient 2

Patient 2 was a right-handed 15-year-old girl suffering from pharmaco-resistant epilepsy. During invasive presurgical evaluation, the seizure onset was localized to the left medial temporal lobe, followed by rapid spread of the ictal activity to the left insula. MRI revealed a left hippocampal sclerosis. Postictal neuropsychological testing revealed a discrete deficit in verbal memory (see Fig. 1B for individual lesion analysis).

The initial ictal sensation was characterized by an ascending epigastric sensation, nausea and the urge to vomit. The patient further mentioned a generalized feeling of extreme warmth (as if her body was burning) and that she was not able to breathe (as if someone was trying to strangulate her). This was followed by the visual impression that a transparent body was leaving her body. The patient indicated that she felt that this body was her 'soul' leaving her body and that she could actually see a white, but transparent, body above her. The autoscopic body (her 'soul') was described as looking like the patient; in particular, she mentioned that she could clearly recognize the face and the upper parts of the trunk. Despite the highly realistic nature of these experiences, the patient remained critical of them and was aware that she was lying in the hospital bed. Towards the end of the seizure, the patient reported to feel that 'the soul' re-entered the body. The patient was agitated throughout the entire episode. To summarize, the patient reported strong self-identification with the physical as well as the autoscopic body, but did not experience any changes of self-location and the first-person perspective.

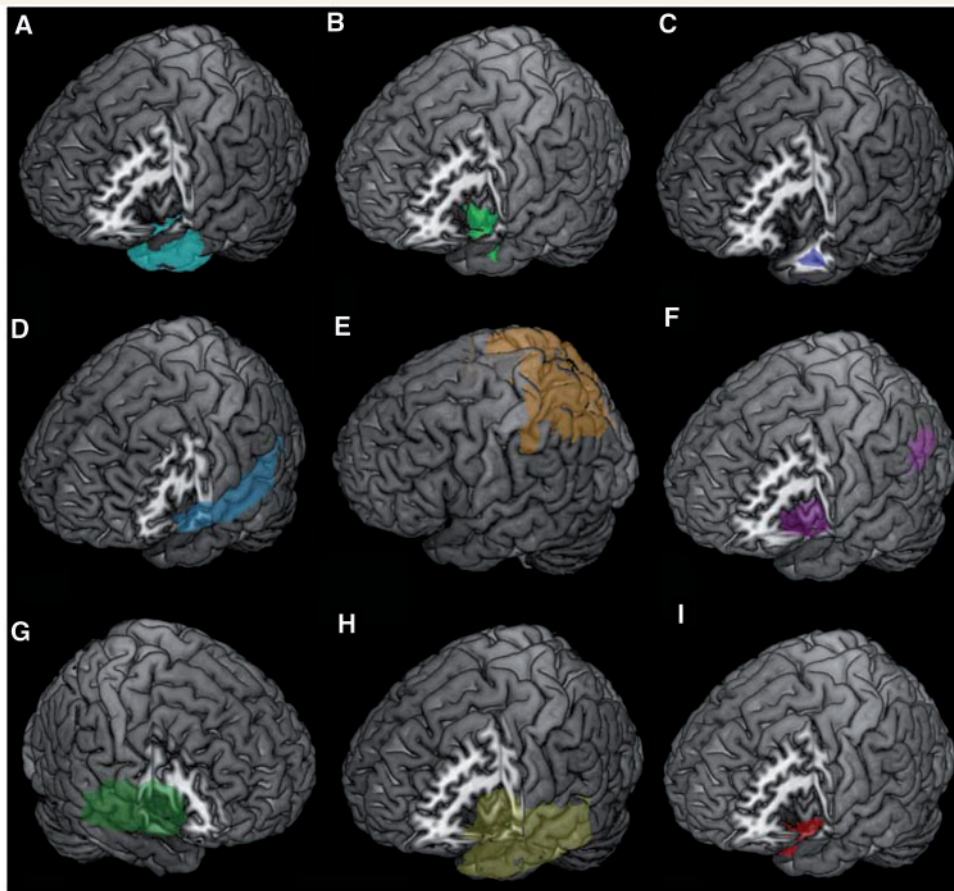


Figure 1 Individual lesion analysis in heautoscopy. Individual lesion analysis for Patients 1–9 (corresponding to A–I). Lesions are displayed on a standard template brain.

Autoscopic hallucinations

Patient 1

The patient was a right-handed 30-year-old man who suffered from complex partial seizures due to a glioblastoma in the left parietal lobe. The clinical examination was normal. The interictal EEG revealed a slowing over the left parietal lobe without any epileptiform activity. After resection of the tumour, no further seizures were noted.

During one episode, the patient saw his autoscopic body standing on top of a taxi for ~10 s. The autoscopic body appeared as if observing the scenery. There was no change of the first-person perspective (e.g. the patient did not see the scene from the taxi), no sensation of disembodiment and no affinity with the autoscopic body (normal self-location and self-identification). The episodes were initially characterized by the sensation of losing balance, together with palpitations and a weakness of the right arm.

Patient 2

The patient (Maillard *et al.*, 2004) was a right-handed 36-year-old woman known for intractable partial epilepsy. Seizures occurred weekly and included motor automatisms and tonic posturing of the trunk and upper and lower limbs bilaterally. She further

described three kinds of initial ictal symptoms: palinopsia (persistence of an image of an object that she had actually seen a few seconds before), macroasomatognosia (sensation of inflation of the nose, head and sometimes whole body) and autoscopic. The interictal EEG showed subcontinuous right parieto-central paroxysms, and the ictal EEG (associated with the autoscopic hallucinations) showed epileptic discharge over the right parieto-central area. MRI showed focal cortical thickening and subcortical increase in FLAIR signal in the right inferior parietal gyrus, consistent with the diagnosis of focal dysplasia.

The patient described seeing the image of her face and her chest (sometimes her whole body) as in a mirror. The autoscopic body had a vague oval contour, was of normal size and colour and showed no particular expression. Self-location, the first-person perspective and self-identification remained normal.

Summary of heautoscopy autoscopic hallucinations and heautoscopy

All patients with heautoscopy reported a strong affinity and self-identification with the autoscopic body (significantly different from autoscopic hallucinations, $P < 0.01$; see later in the text). The autoscopic body was seen in all cases, not only in front view but

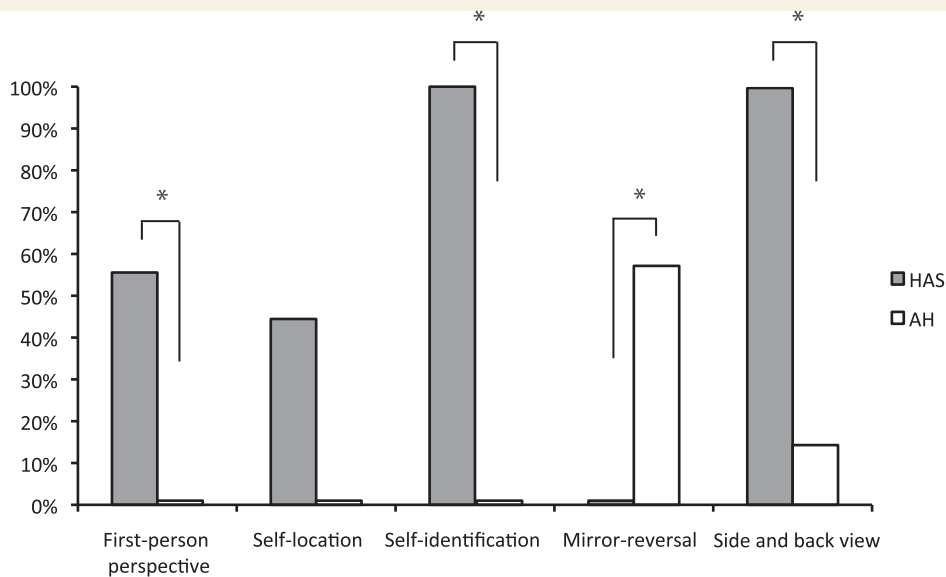


Figure 2 Phenomenology during heautoscopy (HAS) and autoscopic hallucinations (AH). Asterisks indicate a significant difference between the two groups (χ^2 test and Fisher exact test, respectively).

also in side and back views ($P < 0.01$). Five patients with heautoscopy reported alterations of the direction and the position of the first-person perspective (55%, $P = 0.029$). Only two patients with heautoscopy reported bi-location (22%, not significant). None of the patients reported to see the autoscopic body in a mirror-reversed way ($P = 0.01$), and three patients reported echopraxia (33%, not significant). Fig. 2 summarizes the phenomenological characteristics of the patients with heautoscopy and autoscopic hallucinations.

None of the patients with autoscopic hallucinations reported abnormal self-location, first-person perspective or self-identification; self-location and the origin of the first-person perspective as well as self-identification were always centred in the physical body. Patients described the autoscopic body as a mere visual body or a mirror reflection without experiencing any particular affinity (normal self-identification). The autoscopic body was usually seen in front of them (85%) and in a mirror-reversed way (57%). Shared movement (echopraxia) was reported by one patient (14%). For more detailed statistical results, see the online Supplementary material.

Control group

The control group for heautoscopy consisted of eight patients (mean age: 31.5 years, four female, six right handed, two ambidextrous) suffering from complex visual hallucinations due to damage of the left temporal, temporo-parietal or frontal cortex (Supplementary Table 1). Hallucinations included seeing a shadowy person, children, persons moving back and forth, two female persons (daughter and wife) and faces. Another six patients (mean age: 53.3 years, two female, all right handed) suffering from damage to the right posterior parietal and/or right occipital cortex were used as a control group for the patients suffering

from autoscopic hallucinations. The latter patients also suffered from complex visual hallucinations and all reported seeing people (e.g. daughter, little people and faces). None of the patients of the control groups reported any particular affinity or self-identification with the seen persons, or a change of the first-person perspective or self-location.

Associated symptoms and neurological deficits

Fig. 3 shows the associated symptoms and neurological deficits in the patients with heautoscopy and autoscopic hallucinations. Five patients with heautoscopy experienced strong emotional sensations (fear, pleasure, anger) with the autoscopic phenomenon (55%), whereas none of the patients with autoscopic hallucinations reported a particular emotional state ($P = 0.029$). Visceroceptive sensations (33%, not significant), vestibular sensations (55%, $P = 0.09$) and feelings of echopraxia (not significant) were more frequent (but not statistically significant) in the heautoscopy group as compared with the group with autoscopic hallucinations.

The neurological examination was abnormal in six patients with heautoscopy (67%) and in five patients with autoscopic hallucinations (72%, not significant), but differed in the type of deficit. Five patients with autoscopic hallucinations (72%) had a (mostly) contralesional visual field deficit or associated visual symptoms (and usually perceived the autoscopic image in the part of the visual field that was affected). Visual deficits were only found in two patients with heautoscopy (22%, $P = 0.05$). A sensorimotor deficit was present in five patients with heautoscopy (55%), but only one patient with autoscopic hallucinations (14%, $P = 0.09$). Neuropsychological testing yielded a deficit in five patients with heautoscopy (55%; including verbal memory and visuo-spatial

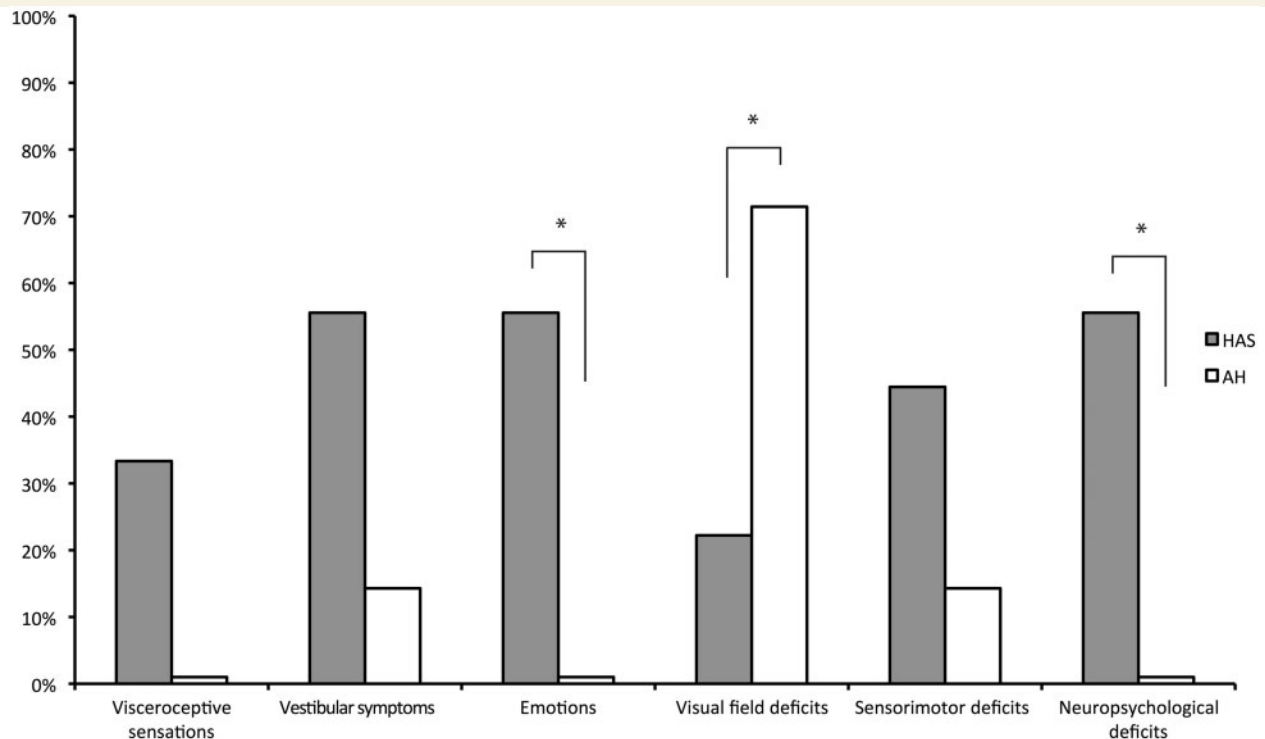


Figure 3 Associated symptoms in heautoscopy (HAS) and autoscopic hallucinations (AH). Asterisks indicate a significant difference between the two groups (χ^2 test and Fisher exact test, respectively).

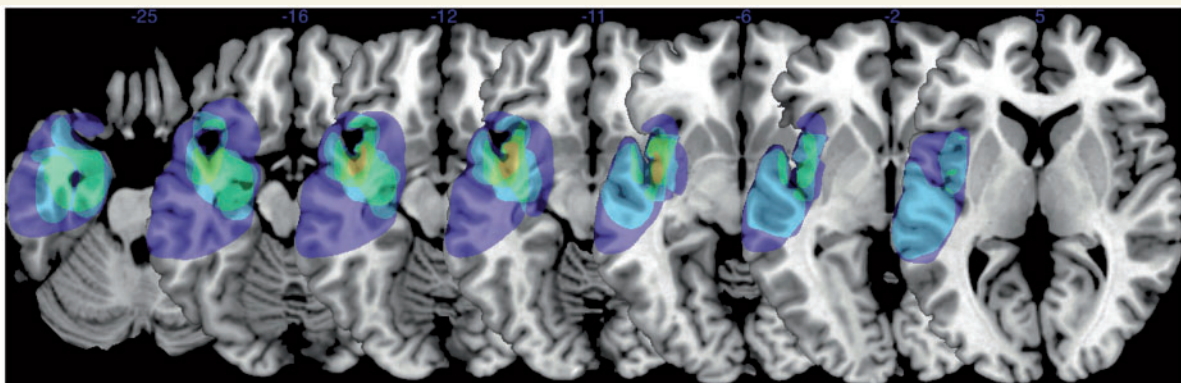


Figure 4 Lesion overlap in heautoscopy. Lesion overlap analysis highlighted the left posterior insula (centred on MNI coordinates $x = -40$, $y = 1$, $z = -10$), which was found to be involved in five out of nine patients with heautoscopy. The number of overlapping lesions is illustrated by colour, from violet ($n = 2$) to yellow (maximal lesion overlap, $n = 5$).

deficits, frontal signs), whereas all patients with autoscopic hallucinations had a normal neuropsychological examination ($P = 0.02$). For more detailed statistical results, see Fig. 3 and the online Supplementary material.

Lesion overlap

Heautoscopy

The left temporal lobe (superior, middle and inferior temporal gyrus), including mesial temporal lobe (amygdala, hippocampus),

and/or the left insula were affected in seven patients with heautoscopy. Two patients had left temporo-parietal lesions (including the angular gyrus and postcentral gyrus). One patient with heautoscopy suffered from exclusive left parietal lobe damage, and in one patient, the right insula was affected. The left hemispheric predominance was confirmed by statistical analysis ($P = 0.03$, binomial test, two tailed). Lesion overlap analysis highlighted the left posterior insula (centred on MNI coordinates $x = -40$, $y = 1$, $z = -10$), which was found to be involved in five out of eight patients with heautoscopy with left brain damage (Fig. 4).

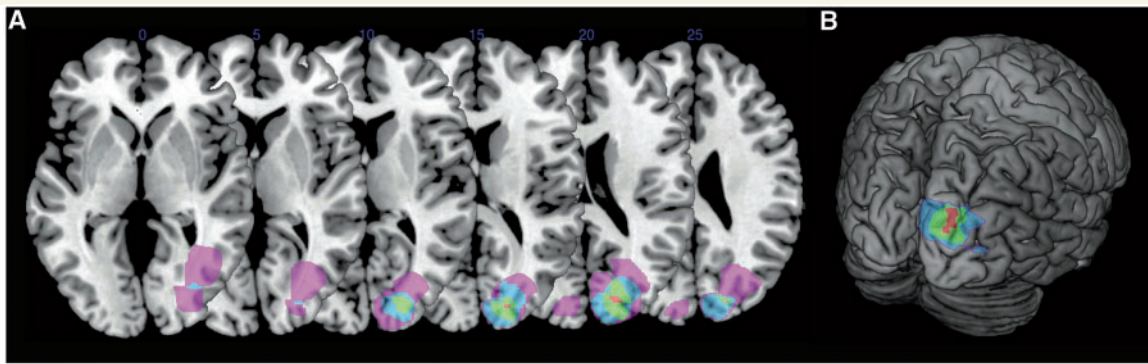


Figure 5 Lesion overlap in autoscopic hallucinations. (A) The lesion overlap map highlighted a subregion of voxels in the right occipital lobe, more specifically the right superior occipital gyrus and the right cuneus (centred on MNI coordinates $x = 20$, $y = -84$, $z = 20$), as the area involved in five patients with autoscopic hallucinations. The number of overlapping lesions is illustrated by colour, from violet ($n = 2$) to red (maximal lesion overlap, $n = 5$). (B) 3D rendering of the lesion overlap in patients with autoscopic hallucinations.

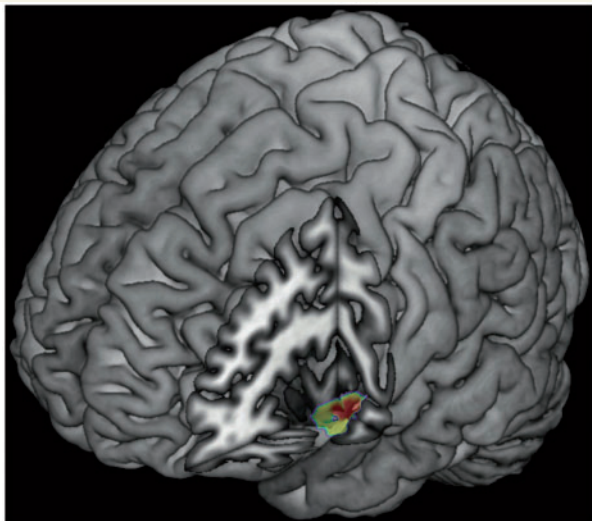


Figure 6 Voxel-based lesion symptom mapping in heautoscopy. Lesion overlap contrast yielded maximal involvement of the left posterior insula (centred on MNI coordinates $x = -40$, $y = 2$, $z = -11$; Z -score = 3.31, $P < 0.01$, corrected for FDR) for heautoscopy as compared with the control group. Only significant voxels are displayed.

Autoscopic hallucinations

In patients with autoscopic hallucination ($n = 7$), the right hemisphere was affected in six patients, and the left hemisphere only in one patient ($P = 0.12$, binomial test, two tailed). The occipital lobe was affected in five patients with autoscopic hallucinations, the parietal lobe in one patient and the parieto-occipital lobe in two patients. The lesion overlap map highlighted a subregion in the right occipital lobe, more specifically the right superior occipital gyrus and the right cuneus (centred on MNI coordinates $x = 20$, $y = -84$, $z = 20$), as the area involved in five of six patients with autoscopic hallucinations due to right hemisphere brain damage (Fig. 5).

Statistical lesion analysis

These results were corroborated and extended by statistical lesion overlap comparison (non-parametric mapping) (Rorden *et al.*, 2007). Lesion overlap contrast yielded maximal involvement of the left posterior insula (centred on MNI coordinates $x = -40$, $y = 2$, $z = -11$; Z -score = 3.31, $P < 0.01$, corrected for FDR) for heautoscopy as compared with the control group (Fig. 6). Autoscopic hallucinations did not significantly differ from the control group with complex visual hallucinations, which were due to lesion to the right parietal or occipital cortex (Z -score = 2.18, $P > 0.05$, corrected for FDR).

Discussion

Here we demonstrate phenomenological differences as well as distinct neuroanatomical substrates for heautoscopy and autoscopic hallucinations. Heautoscopy was characterized by a strong disturbance of bodily self-consciousness, including altered self-identification and emotional changes and affinity with the autoscopic body that were frequently associated with changes of the first-person perspective and self-location. Moreover, our analysis associated abnormal vestibular sensations, neuropsychological deficits and contralesional sensorimotor, but not visual, deficits with heautoscopy. This was different during autoscopic hallucinations. Self-identification, self-location and the first-person perspective remained centred at the physical body and the pseudo-hallucinatory autoscopic body was often experienced in a mirror-reversed way, and frequently seen on the side of the contralesional visual field deficit. Autoscopic hallucinations were not associated with neuropsychological or sensorimotor deficits. Using state-of-the-art lesion symptom mapping techniques in the—to date—largest sample of patients suffering from heautoscopy and autoscopic hallucinations, we were able to demonstrate distinct neuroanatomical substrates for both autoscopic phenomena: heautoscopy was linked to the left posterior insula and adjacent cortical regions, whereas autoscopic hallucinations were

associated with damage to the occipital cortex. Later in the text, we discuss the relevance of our findings in the context of the existing models for autoscopic phenomena and recent findings from cognitive neuroscience and neurology on body representation and bodily self-consciousness. We next discuss autoscopic hallucinations and then focus on heautoscopy and the role of the insular cortex as a multisensory integration area, comparing the present findings with the recent implication of the right temporo-parietal junction in bodily self-consciousness and out-of-body experiences (Ionta *et al.*, 2011).

The present data show that autoscopic hallucinations are associated with visual deficits and caused by damage to the right superior occipital gyrus and the right cuneus in extrastriate visual cortex. This location of brain damage was similar to that in the control group, compatible with the known implication of extrastriate visual cortex in other complex visual hallucinations (Cogan, 1973; Manford and Andermann, 1998). Because complex visual hallucinations may be restricted to the affected visual hemifield and because this was observed in the present patients with autoscopic hallucinations, we suggest that autoscopic hallucinations are due to damage in the extrastriate visual cortex. This damage likely includes visual body perception regions such as the extrastriate body area (Downing *et al.*, 2001; Astafiev *et al.*, 2004), the fusiform body area (Peelen and Downing, 2005) and the fusiform face area (Kanwisher *et al.*, 1997), although this has not been directly tested in the present study. All regions have been linked to the perception and recognition of the human body, body parts and faces. Importantly, the right fusiform face area and fusiform body area also respond to one's own face (Uddin *et al.*, 2005) and one's own body (Hodzic *et al.*, 2009). The extrastriate body area has also been shown to respond to sensorimotor signals, compatible with a role of these regions beyond mere visual processing (Astafiev *et al.*, 2004). However, we note that most of the lesions in the patients with autoscopic hallucinations were within the occipital cortex and that the maximal lesion overlap was more dorsal and posterior compared with the right fusiform body area and fusiform face area (Kanwisher *et al.*, 1997; Peelen and Downing, 2005), as well as the right extrastriate body area (Downing *et al.*, 2001). Accordingly, we cannot exclude that autoscopic hallucinations have resulted from interference with lower-level visual regions. As all three aspects of bodily self-consciousness were normal in patients with autoscopic hallucinations, the present data suggest that damage to the occipital cortex did not interfere with self-location, self-identification or the first-person perspective. As argued previously and extending related accounts of supernumerary phantom limbs (Ramachandran and Hirstein, 1998) and autoscopic hallucinations (Bolognini *et al.*, 2010), we argue that autoscopic hallucinations and autoscopy (i.e. the seeing of one's own body in extrapersonal space as is present during all autoscopic phenomena; Brugger *et al.*, 1997; Brugger, 2002) are caused by disintegration between visual and somatosensory signals (Blanke *et al.*, 2004; Blanke and Metzinger, 2009). Despite the inherent fascination and interest of the phenomenon for clinician and patient, the present data show that autoscopic hallucinations do not represent a disorder of bodily self-consciousness, as is the case in heautoscopy.

During heautoscopy, we found abnormal self-identification in all patients characterized by the experience of a strong emotional affinity towards and self-identification with the autoscopic body. Lesion overlap and statistical lesion analysis revealed that heautoscopy was caused by damage to or interference with the left posterior insula. The posterior insular cortex is a multisensory integration area, including somatosensory, motor, visual, auditory, vestibular and limbic signals (Augustine, 1996; Flynn, 1999). Schneider *et al.* (1993) observed large and often bilateral somatosensory receptive fields in the granular insular cortex. The posterior insula has also been implicated in disownership of body parts in neurological patients (e.g. somatoparaphrenia) (Baier and Karnath, 2008). Patients with somatoparaphrenia report the sensation that a certain body part, usually the left arm, is no longer their own, but belongs to another person (misattribution of a body part, abnormal self-identification) (Vallar and Ronchi, 2009). It has been suggested that the loss of ownership and the misattribution are a result of abnormal integration of sensorimotor and visual cues due to damage to the posterior insular cortex (Baier and Karnath, 2008). An implication of the insula in bodily self-consciousness is further supported by evidence from neuroimaging studies on manipulations of hand ownership and the related concept of agency through visuo-tactile and visuo-motor stimulations (Farrer *et al.*, 2003; Tsakiris *et al.*, 2007). These data and the present data on heautoscopy are compatible with the proposal that abnormal integration of somatosensory, visual and motor signals in the posterior insular cortex could result not only in misattribution of a body part (e.g. somatoparaphrenia, rubber hand illusion) but also in abnormal body ownership for a full body (e.g. self-identification with the autoscopic body).

However, a disintegration model based on somatosensory, motor and visual own-body signals as put forward for somatoparaphrenia (Baier and Karnath, 2008) and autoscopic hallucinations does not account for the observation that patients with heautoscopy experience a close emotional affinity towards the autoscopic body (Brugger *et al.*, 1997) and the frequent association of heautoscopy with the sensation of detachment from own bodily processing (e.g. depersonalization) (Devinsky *et al.*, 1989; Brugger *et al.*, 1997) and viscerceptive sensations (e.g. epigastric aura, vomiting, palpitation). We note that this aspect is critically absent in patients with autoscopic hallucinations and out-of-body experiences (Brugger *et al.*, 1997; Blanke *et al.*, 2004). Of relevance for heautoscopy, however, it has been suggested that the posterior insular cortex links somatosensory signals from the secondary somatosensory cortex with signals from limbic structures, such as the amygdala, the perirhinal cortex and the cingulate cortex (Friedman *et al.*, 1986). This is supported by recent functional MRI work in humans by Ebisch *et al.* (2011), showing that activity in the left posterior insular cortex distinguished between the physical experience and observation of touch, but only if the touch was of affective significance (e.g. pleasant versus neutral touch). In line with these results, Morrison *et al.* (2011) found that activity in the posterior insular cortex is associated with both seeing and feeling pleasant touch. In addition, it has been suggested that activity in the insular cortex reflects abnormal perception of touch in the case of vision–touch synaesthesia (Blakemore *et al.*, 2005), e.g. the case where the observation of another person

being touched is experienced as tactile stimulation on the equivalent part of one's own body. Thus, the posterior insular cortex has been proposed not only to encode emotionally relevant somatosensory experience for both self and other, but also to distinguish whether an emotionally relevant somatosensory stimulus has been delivered to our body or to someone else's body (Ebisch *et al.*, 2011; Morrison *et al.*, 2011).

Moreover, the posterior insular cortex has recently been implicated in the first-order cortical representation of pain and internal bodily states (viscerosensation), including homeostatic, gastrointestinal and cardiac signals (Augustine, 1996; Damasio *et al.*, 2000; Craig, 2002, 2009). The further processing of this afferent visceral–autonomic information and the integration with limbic processing in the (anterior) insular cortex (together with the anterior cingulate cortex) are thought to be of crucial importance for emotions, interoceptive awareness and self-awareness (Damasio *et al.*, 2000; Craig, 2002; Critchley *et al.*, 2004; Picard, 2010). Extending earlier theories of emotion (James, 1884; Lange, 1922), studies have recently suggested that the mapping of internal bodily states and emotional experience in the insular cortex is crucial for conscious feelings generally and human self-consciousness (Damasio *et al.*, 2000; Craig, 2002, 2009; Damasio, 2003). With respect to the present data on patients with heautoscopy, recent studies using functional MRI have shown increased insular activity not only during the subjective experience of one's own feelings and emotions but also when a familiar other is experiencing the same emotion (Singer *et al.*, 2004). It has thus been argued that these shared networks for self and other may form the basis for emotional perspective taking and empathy (Singer *et al.*, 2009). Our observation that heautoscopy after insula damage is frequently associated with heightened or altered emotional states and viscerosensitive sensations, such as palpitations, epigastric aura or vomiting [although only found in 33% of the present patient sample, but see Sollier (1903) for a viscerosensitive account of heautoscopy], may be related to interference with such brain representations. Based on these findings, we speculate that damage to the posterior insular cortex results in a breakdown of self–other discrimination regarding affective somatosensory experience due to a disintegration of somatosensory and visual signals with emotional (and/or interoceptive) own-body signals. We speculate that the appearance of the autoscopic body and the referral of self-generated emotional states and feelings to the autoscopic body are a consequence of this disintegration, leading to abnormal emotional affinity and abnormally strong self-identification with the autoscopic body.

Many patients with heautoscopy also suffer from abnormal self-location and first-person perspective such as alternating self-location and first-person perspective between the physical and the illusory body and sensation of bi-location. We argue that these changes are caused by additional abnormal integration of vestibular signals (as proposed previously by Grüsser and Landis, 1991; Blanke *et al.*, 2004; and Blanke and Mohr, 2005) with other bodily signals. Our data suggest that the former disintegration (somatosensory–visual signals with emotional–interoceptive signals) is present in all patients with heautoscopy, whereas the vestibular disturbance was only found in about half of them. Previous work revealed that heautoscopy is frequently associated

with vestibular disturbances (Blanke and Mohr, 2005) and was confirmed in the present study (55%). The posterior insular cortex in the right and left hemisphere is part of the 'vestibular cortical network', together with the temporo-parietal junction, anterior parietal cortex and premotor cortex (Guldin and Grüsser, 1998; Lopez and Blanke, 2011). Other illusory own-body perceptions, such as out-of-body experiences (Blanke *et al.*, 2004), the misattribution of body parts (Heydrich *et al.*, 2010) and depersonalization (Sang *et al.*, 2006), are also frequently associated with vestibular sensations and have been linked to the temporo-parietal junction (Simeon *et al.*, 2000; Blanke *et al.*, 2004; Heydrich *et al.*, 2011) and the posterior insular cortex (Landtblom *et al.*, 2011). Blanke *et al.* (2004) proposed that abnormal integration of mainly otolithic vestibular signals with other bodily signals (from vision, proprioception, touch) results in the abnormal elevated self-location and first-person perspective, characteristic of out-of-body experiences. Moreover, links between the vestibular system and bodily self-consciousness have also been revealed experimentally. Thus, vestibular stimulation has been shown to alter body ownership and somatosensory processing, both in patients with somatoparaphrenia (Bisiach *et al.*, 1991; Rode *et al.*, 1992) and healthy participants (Lopez *et al.*, 2008, 2010, 2012; Ferre *et al.*, 2011). Thus, it has been suggested that vestibular processing might be a central aspect of body ownership and embodiment (Lenggenhager *et al.*, 2008; Lopez *et al.*, 2008). During heautoscopy, vestibular sensations are variable, often related to the semicircular canals, and less prominent as compared with out-of-body experiences. We argue that—although changes in self-location and the first-person perspective in heautoscopy are less prominent than those during out-of-body experiences—their more variable and dynamic character (and association with abnormal emotional–interoceptive signals) may be related to the sensation of bi-location that is present in heautoscopy, but absent in out-of-body experiences, the latter being characterized by a clear psychological separation between the autoscopic and the physical body.

Why was left, but not right, damage to the posterior insula associated with heautoscopy? A previous literature review without quantitative lesion analysis also linked the left temporo-parietal cortex to heautoscopy (Blanke and Mohr, 2005). This lateralization is compatible with the presence of auditory verbal hallucinations in patients with heautoscopy that have been linked to the left hemisphere and the left temporo-parietal cortex in particular (Hubl *et al.*, 2004). Auditory verbal manifestations are generally absent in patients with autoscopic hallucinations and out-of-body experiences. We can currently only speculate why right posterior insula damage was not associated with heautoscopy. As suggested by Craig *et al.* (2009), there may be functional differences concerning self-processing in right versus left insular cortex. Such right versus left insula differences may also concern language (left) versus spatial (right) processing differences or vestibular processing differences (left, semicircular canals; right, otoliths) (Blanke, 2012). We also note that previous neuroimaging work in healthy subjects reported bilateral temporo-parietal activations in experimentally induced changes in self-location and first-person perspective (Lonta *et al.*, 2011). Future work is necessary to investigate right versus left

temporo-parietal activations (including the insula) with respect to emotional, vestibular, language and spatial processing.

In conclusion, we argue that heautoscopy is caused by damage to the left posterior insular cortex, leading to a disintegration of exteroceptive bodily signals (somatosensory, visual) with emotional and/or visceral corporeal signals. Such disintegration results in abnormal self-identification and heightened emotional affinity that patients with heautoscopy experience for the autoscopic body. Projecting self-generated emotional states and feelings onto the autoscopic body, while also experiencing detachment of emotional sensations and somatosensory processing for the own body [e.g. inner hollowness and depersonalization (Brugger, 2002)], is thus the fundamental pathomechanism in heautoscopy and is associated with the appearance of not just a seen second own body, but a 'true' double, often experienced as another self. Such emotional–somatosensory disintegration may lead to levels of self-identification that are elevated for both the physical and the autoscopic body, making self–other distinction and self-location ambiguous. If accompanied by additional abnormal vestibular signals, further changes in first-person perspective and self-location may result, leading to bi-location and the sensation of self-duplication, likely the strongest form of heautoscopy dissociation. Neurological and neuropsychological symptoms and lesion location differed in autoscopic hallucinations, highlighting visual and visuo-somatosensory mechanisms in extrastriate and occipital cortex. Given the normality of bodily self-consciousness during autoscopic hallucinations, we speculate that autoscopic hallucinations are a disorder of own-body representation due to visuo-tactile disintegration caused by damage to the ventral visual pathways in proximity to the extrastriate body area, fusiform body area or fusiform face area.

Acknowledgements

The authors would like to thank the following persons for sharing the data with us: P. Brugger (Zürich), M. Seeck (Geneva), L. Maillard and P. Vignal (Nancy), P. Kahane (Grenoble), Y. Tadokoro (Aichi, Japan), G. Zamboni (Modena), D. de Ridder (Antwerpen) and C. Brandt (Bielefeld). The authors also would like to thank H.-O. Karnath and C. Rorden for their advice on the lesion analysis.

Funding

L.H. is supported by the Swiss National Science Foundation (Grants 33CM30-124089) and the Cogito Foundation; O.B. is supported by the Swiss National Science Foundation (Sinergia Grant CRSII1-125135: Balancing Self and Body), the European Science Foundation (VERE) and the Bertarelli Foundation.

Supplementary material

Supplementary material is available at *Brain* online.

References

- Arenz D. Heautoskopie Doppelgängerphänomen und seltene Halluzination der eigenen Gestalt. *Nervenarzt* 2001; 72: 376–9.
- Ashburner J, Friston KJ. Unified segmentation. *Neuroimage* 2005; 26: 839–51.
- Astafiev SV, Stanley CM, Shulman GL, Corbetta M. Extrastriate body area in human occipital cortex responds to the performance of motor actions. *Nat Neurosci* 2004; 7: 542–8.
- Augustine JR. Circuitry and functional aspects of the insular lobe in primates including humans. *Brain Res Brain Res Rev* 1996; 22: 229–44.
- Baier B, Karnath HO. Tight link between our sense of limb ownership and self-awareness of actions. *Stroke* 2008; 39: 486–8.
- Bates E, Wilson SM, Saygin AP, Dick F, Sereno MI, Knight RT, et al. Voxel-based lesion-symptom mapping. *Nat Neurosci* 2003; 6: 448–50.
- Bisiach E, Rusconi ML, Vallar G. Remission of somatoparaphrenic delusion through vestibular stimulation. *Neuropsychologia* 1991; 29: 1029–31.
- Blakemore SJ, Bristow D, Bird G, Frith C, Ward J. Somatosensory activations during the observation of touch and a case of vision-touch synaesthesia. *Brain* 2005; 128 (Pt 7): 1571–83.
- Blanke O. Multisensory brain mechanisms of bodily self-consciousness. *Nat Rev Neurosci* 2012; 13: 556–71.
- Blanke O, Landis T, Spinelli L, Seeck M. Out-of-body experience and autoscopia of neurological origin. *Brain* 2004; 127 (Pt 2): 243–58.
- Blanke O, Metzinger T. Full-body illusions and minimal phenomenal selfhood. *Trends Cogn Sci* 2009; 13: 7–13.
- Blanke O, Mohr C. Out-of-body experience, heautoscopy, and autoscopic hallucination of neurological origin implications for neurocognitive mechanisms of corporeal awareness and self-consciousness. *Brain Res Brain Res Rev* 2005; 50: 184–99.
- Blanke O, Castillo V. Clinical neuroimaging in epileptic patients with autoscopic hallucinations and out-of-body-experiences. *Epileptologia* 2007; 24: 90–6.
- Blanke O, Arzy S, Landis T. Chapter 22: Illusory reduplications of the human body and self. *Handb Clin Neurol* 2008; 88: 429–58.
- Bolognini N, Ladavas E, Farne A. Spatial perspective and coordinate systems in autoscopia: a case report of a "fantome de profil" in occipital brain damage. *J Cogn Neurosci* 2010; 23: 1741–51.
- Bonnier P. L'aschématie. *Rev Neurol (Paris)* 1905; 12: 605–9.
- Brandt C, Brechtelsbauer D, Bien CG, Reiners K. Out-of-body experience as possible seizure symptom in a patient with a right parietal lesion [in German]. *Nervenarzt* 2005; 76: 1259, 1261–2.
- Bremmer F, Schlack A, Shah NJ, Zafiris O, Kubischik M, Hoffmann K, et al. Polymodal motion processing in posterior parietal and premotor cortex: a human fMRI study strongly implies equivalencies between humans and monkeys. *Neuron* 2001; 29: 287–96.
- Brugger P, Agosti R, Regard M, Wieser HG, Landis T. Heautoscopy, epilepsy, and suicide. *J Neurol Neurosurg Psychiatry* 1994; 57: 838–9.
- Brugger P, Regard M, Landis T. Illusory reduplication of one's own-body: phenomenology and classification of autoscopic phenomena. *Cogn Neuropsychiatry* 1997; 2: 19–38.
- Brugger P. Reflective mirrors: perspective-taking in autoscopic phenomena. *Cogn Neuropsychiatry* 2002; 7: 179–94.
- Brugger P, Blanke O, Regard M, Bradford DT, Landis T. Polyopic heautoscopy: case report and review of the literature. *Cortex* 2006; 42: 666–74.
- Calvert GA, Campbell R, Brammer MJ. Evidence from functional magnetic resonance imaging of crossmodal binding in the human heteromodal cortex. *Curr Biol* 2000; 10: 649–57.
- Cogan DG. Visual hallucinations as release phenomena. *Albrecht Von Graefes Arch Klin Exp Ophthalmol* 1973; 188: 139–50.
- Coleman SM. The phantom double. Its psychological significance. *Br J Med Psychol* 1934; 14: 254–73.
- Craig AD. How do you feel–now? The anterior insula and human awareness. *Nat Rev Neurosci* 2009; 10: 59–70.

- Craig AD. How do you feel? Interoception: the sense of the physiological condition of the body. *Nat Rev Neurosci* 2002; 3: 655–66.
- Crinion J, Ashburner J, Leff A, Brett M, Price C, Friston K. Spatial normalization of lesioned brains: performance evaluation and impact on fMRI analyses. *Neuroimage* 2007; 37: 866–75.
- Critchley HD, Wiens S, Rotshtein P, Ohman A, Dolan RJ. Neural systems supporting interoceptive awareness. *Nat Neurosci* 2004; 7: 189–95.
- Damasio AR, Grabowski TJ, Bechara A, Damasio H, Ponto LL, Parvizi J, et al. Subcortical and cortical brain activity during the feeling of self-generated emotions. *Nat Neurosci* 2000; 3: 1049–56.
- Damasio A. Feelings of emotion and the self. *Ann N Y Acad Sci* 2003; 1001: 253–61.
- De Ridder D, Van Laere K, Dupont P, Menovsky T, Van de Heyning P. Visualizing out-of-body experience in the brain. *N Engl J Med* 2007; 357: 1829–33.
- Devinsky O, Feldmann E, Burrows K, Bromfield E. Autoscopy phenomena with seizures. *Arch Neurol* 1989; 46: 1080–8.
- Dewhurst K, Pearson J. Visual hallucinations of the self in organic disease. *J Neurol Neurosurg Psychiatry* 1955; 18: 53–7.
- Downing PE, Jiang Y, Shuman M, Kanwisher N. A cortical area selective for visual processing of the human body. *Science* 2001; 28;293: 2470–3.
- Easton S, Blanke O, Mohr C. A putative implication for fronto-parietal connectivity in out-of-body experiences. *Cortex* 2009; 45: 216–27.
- Ebisch SJ, Ferri F, Salone A, Perrucci MG, D'Amico L, Ferro FM, et al. Differential involvement of somatosensory and interoceptive cortices during the observation of affective touch. *J Cogn Neurosci* 2011; 23: 1808–22.
- Farrer C, Franck N, Georgieff N, Frith CD, Decety J, Jeannerod M. Modulating the experience of agency: a positron emission tomography study. *NeuroImage* 2003; 18: 324–33.
- Féré C. Note sur les hallucinations autoscopiques ou spéculaires et sur les hallucinations altruistes. *C R Hebd Séances Mém Soc Biol* 1891; 3: 451–3.
- Ferre ER, Bottini G, Haggard P. Vestibular modulation of somatosensory perception. *Eur J Neurosci* 2011; 34: 1337–44.
- Flynn FG. Anatomy of the insula functional and clinical correlates. *Aphasiology* 1999; 13: 55–78.
- Friedman DP, Murray EA, O'Neill JB, Mishkin M. Cortical connections of the somatosensory fields of the lateral sulcus of macaques: evidence for a corticolimbic pathway for touch. *J Comp Neurol* 1986; 252: 323–47.
- Grüsser OJ, Landis T. Visual agnosias and other disturbances of visual perception and cognition. London: The Macmillan Press; 1991.
- Guldin WO, Grüsser OJ. Is there a vestibular cortex? *Trends Neurosci* 1998; 21: 254–9.
- Hécaen H, Ajuriaguerra J. Méconnaissances et hallucinations corporelles. Paris: Masson; 1952.
- Heydrich L, Dieguez S, Grunwald T, Seeck M, Blanke O. Illusory own-body perceptions: case reports and relevance for bodily self-consciousness. *Conscious Cogn* 2010; 19: 702–10.
- Heydrich L, Lopez C, Seeck M, Blanke O. Partial and full own-body illusions of epileptic origin in a child with right temporoparietal epilepsy. *Epilepsy Behav* 2011; 20: 583–6.
- Hodzic A, Muckli L, Singer W, Stirn A. Cortical responses to self and others. *Hum Brain Mapp* 2009; 30: 951–62.
- Hubl D, Koenig T, Strik W, Federspiel A, Kreis R, Boesch C, et al. Pathways that make voices: white matter changes in auditory hallucinations. *Arch Gen Psychiatry* 2004; 61: 658–68.
- Ionasescu V. Paroxysmal disorders of the body image in temporal lobe epilepsy. *Acta Psychiatr Scand* 1960; 35: 171–81.
- Ionta S, Heydrich L, Lenggenhager B, Mouthon M, Fornari E, Chapuis D, et al. Multisensory mechanisms in temporo-parietal cortex support self-location and first-person perspective. *Neuron* 2011; 70: 363–74.
- James W. What is an emotion? *Mind* 1884; 9: 188–205.
- Kanwisher N, McDermott J, Chun MM. The fusiform face area: a module in human extrastriate cortex specialized for face perception. *J Neurosci* 1997; 17: 4302–11.
- Knowlton RC. Multimodality imaging in partial epilepsies. *Curr Opin Neurol* 2004; 17: 165–72.
- Kölmel HW. Complex visual hallucinations in the hemianopic field. *J Neurol Neurosurg Psychiatry* 1985; 48: 29–38.
- Kurian M, Spinelli L, Delavelle J, Willi JP, Velazquez M, Chaves V, et al. Multimodality imaging for focus localization in pediatric pharmacoresistant epilepsy. *Epileptic Disord* 2007; 9: 20–31.
- Landtblom AM, Lindehammar H, Karlsson H, Craig AD. Insular cortex activation in a patient with “sensed presence”/ecstatic seizures. *Epilepsy Behav* 2011; 20: 714–18.
- Lange CG. The emotions. In: Lange CG, James W, editors. *The emotions a series of reprints and translations* (pp 135). Baltimore, MD: Williams & Wilkins; 1922. p. 33–90.
- Lenggenhager B, Lopez C, Blanke O. Influence of galvanic vestibular stimulation on egocentric and object-based mental transformations. *Exp Brain Res* 2008; 184: 211–21.
- Lippman CW. Hallucinations of physical duality in migraine. *J Nerv Ment Dis* 1953; 117: 345–50.
- Lopez C, Halje P, Blanke O. Body ownership and embodiment: vestibular and multisensory mechanisms. *Neurophysiol Clin* 2008; 38: 149–61.
- Lopez C, Lenggenhager B, Blanke O. How vestibular stimulation interacts with illusory hand ownership. *Conscious Cogn* 2010; 19: 33–47.
- Lopez C, Blanke O. The thalamocortical vestibular system in animals and humans. *Brain Res Rev* 2011; 67: 119–46.
- Lopez C, Schreyer HM, Preuss N, Mast FW. Vestibular stimulation modifies the body schema. *Neuropsychologia* 2012; 50: 1830–7.
- Lukianowicz N. Autoscopy phenomena. *AMA Arch Neurol Psychiatry* 1958; 80: 199–220.
- Lunn V. Autoscopy phenomena. *Acta Psychiatr Scand* 1970; 46: 118–25.
- Lukianowicz N. “Body image” disturbances in psychiatric disorders. *Br J Psychiatry* 1963; 113: 31–47.
- Maillard L, Vignal JP, Anxionnat R, TaillandierVespignani L. Semiologic value of ictal autoscopy. *Epilepsia* 2004; 45: 391–4.
- Manford M, Andermann F. Complex visual hallucinations. Clinical and neurobiological insights. *Brain* 1998; 121: 1819–40.
- Menninger-Lerchenhal E. *Das Truggebilde der eigenen Gestalt*. Berlin: S. Karger; 1935.
- Menninger-Lerchenhal E. *Der eigene Doppelgänger*. Bern: Huber; 1946.
- Menninger-Lerchenhal E. *Heautoskopie*. *Wien Med Wochenschr* 1961; 44: 745–56.
- Morrison I, Bjornsdotter M, Olausson H. Vicarious responses to social touch in posterior insular cortex are tuned to pleasant caressing speeds. *J Neurosci* 2011; 31: 9554–62.
- Peelen MV, Downing PE. Selectivity for the human body in the fusiform gyrus. *J Neurophysiol* 2005; 93: 603–8.
- Picard F. Epileptic feeling of multiple presences in the frontal space. *Cortex* 2010; 46: 1037–42.
- Ramachandran VS, Hirstein W. The perception of phantom limbs. The D. O. Hebb lecture. *Brain* 1998; 121 (Pt 9): 1603–30.
- Rode G, Charles N, Perenin MT, Vighetto A, Trillet M, Aimard G. Partial remission of hemiplegia and somatoparaphrenia through vestibular stimulation in a case of unilateral neglect. *Cortex* 1992; 28: 203–8.
- Rorden C, Karnath HO, Bonilha L. Improving lesion-symptom mapping. *J Cogn Neurosci* 2007; 19: 1081–8.
- Sang FY, Jauregui-Renaud K, Green DA, Bronstein AM, Gresty MA. Depersonalisation/derealisation symptoms in vestibular disease. *J Neurol Neurosurg Psychiatry* 2006; 77: 760–6.
- Simeon D, Guralnik O, Hazlett EA, Spiegel-Cohen J, Hollander E, Buchsbaum MS. Feeling unreal: a PET study of depersonalization disorder. *Am J Psychiatry* 2000; 157: 1782–8.
- Singer T, Seymour B, O'Doherty J, Kaube H, Dolan RJ, Frith CD. Empathy for pain involves the affective but not sensory components of pain. *Science* 2004; 303: 1157–62.
- Singer T, Critchley HD, Preusschoff K. A common role of insula in feelings, empathy and uncertainty. *Trends Cogn Sci* 2009; 13: 334–40.
- Schneider RJ, Friedman DP, Mishkin M. A modality-specific somatosensory area within the insula of the rhesus monkey. *Brain Res* 1993; 621: 116–20.

- Sollier P. Les phénomènes d'autoscopie. Paris: Félix Alcan; 1903.
- Tadokoro Y, Oshima T, Kanemoto K. Postictal autoscopia in a patient with partial epilepsy. *Epilepsy Behav* 2006; 9: 535–40.
- Tsakiris M, Hesse MD, Boy C, Haggard P, Fink GR. Neural signatures of body ownership: a sensory network for bodily self-consciousness. *Cereb Cortex* 2007; 17: 2235–44.
- Uddin LQ, Kaplan JT, Molnar-Szakacs I, Zaidel E, Iacoboni M. Self-face recognition activates a frontoparietal "mirror" network in the right hemisphere: an event-related fMRI study. *NeuroImage* 2005; 25: 926–35.
- Vallar G, Ronchi R. Somatoparaphrenia: a body delusion. A review of the neuropsychological literature. *Exp Brain Res* 2009; 192: 533–51.
- Zamboni G, Budriesi C, Nichelli P. "Seeing oneself": a case of autoscopia. *Neurocase* 2005; 11: 212–15.