

Dr Bachet: At 3 o'clock in the morning on a Sunday, you get a radiologist that makes you a CT scan in a few minutes? It must be good to be at Bad Neustadt.

Dr Urbanski: The CT angiography takes a few minutes. It's normal.

Dr Bachet: Well, anyway, we have to stop this discussion. But there is a little point I want to address before closing the discussion. I don't know if I understood correctly, but you said that in some Marfan patients you don't remove all the sinuses?

Dr Urbanski: Yes.

Dr Bachet: For me this is erroneous.

Dr Urbanski: I demonstrated here.

Dr Bachet: Marfan patients should have their root replaced systematically.

Dr Urbanski: After 10 years, they're still alive and the root is normal.

Dr Bachet: Yes, but you had only three Marfan patients in your statistics. Wait until you have a few more.

Dr Urbanski: As I said, each Marfan patient presents different root and leaf pathology. And the role of the surgeon is to decide properly in which patients the root is replaced with a Bentall procedure and which are repaired.

European Journal of Cardio-Thoracic Surgery 44 (2013) 444–445
doi:10.1093/ejcts/ezt065 Advance Access publication 24 February 2013

EDITORIAL COMMENT

Selective sinus repair in acute type A dissection

Thierry Carrel*

Clinic for Cardiovascular Surgery, Bern University Hospital, Berne, Switzerland

* Corresponding author. Clinic for Cardiovascular Surgery, Bern University Hospital, Freiburgstrasse, 3010 Berne, Switzerland. Tel: +41-31-6322375; e-mail: thierry.carrel@insel.ch (T. Carrel).

Keywords: Aortic dissection • Aortic root repair • Valve preservation • Selective sinus replacement

Currently, aortic valve-preserving root replacement is gaining popularity in selected younger patients with the tricuspid valve to avoid the requirement for lifelong anticoagulation. Different types of procedures (aortic root remodelling according to M. Yacoub and reimplantation technique according to T. David) have been described and increasingly used in the elective setting. Resuspension of the commissures of the aortic valve and graft replacement of the supracoronary aorta represent the most commonly performed procedures for patients presenting with acute dissection type A. When doing them, the surgeon needs to be confident that the valve repair will be durable and the sinuses of Valsalva will not dilate excessively over time. The presence of advanced valve pathology (leaflet calcifications, commissural fusion or large fenestrations close to the commissures) is usually an indication for valve replacement.

Urbanski *et al.* [1] report a series of 46 patients treated because of acute aortic dissection type A in whom one-, two- or a three-sinus repair was performed in order to selectively repair the dissected part of the aortic root and to avoid the use of any type of glue. The authors have to be congratulated for the excellent early and long-term results obtained in a difficult group of patients.

Aortic root remodelling using a selective sinus repair was reported by Stephen Westaby as early as 2002, where he described this successful approach in 29 patients suffering from atherosclerotic aneurysm of the aortic root and who were operated on between 1995 and 2001 (Fig. 1) [2]. In this paper, Westaby *et al.* suggested that root dilatation begins in the non-coronary, then in the right coronary sinus. The left coronary sinus usually retains normal dimensions until a very advanced stage. Rather than employing aortic root replacement or the David procedure, Westaby *et al.* elected to replace the ascending aorta and remodel the sinotubular junction and the involved

sinuses. The long-term follow-up of these patients revealed that aortic valve and root repair provided a durable repair and allowed the avoidance of a more radical aortic root replacement with prosthesis-related complications.

Although the approach described by Urbanski *et al.* is an attractive one, some critical points have to be emphasized:

- (i) It might be questionable to include very old patients for a valve-sparing technique since aortic valve replacement with a bioprosthesis (or complete root replacement with a biological composite graft) might be the more straightforward and secure treatment.
- (ii) It is difficult to confirm an important advantage with single or double sinus repair with separate patches in Marfan patients, because the latter suffer generally from a pathology of the whole aortic root and should receive the most complete root repair or replacement. With this in mind, it is surprising that a 'partial' repair did not lead to any re-intervention on the aortic root.
- (iii) Whether a classical David reimplantation procedure, or a root repair with three separate patches is the better option for those patients with a circumferentially dissected aortic root seems clear to me: the David procedure with a Valsalva tube graft secured below the aortic annulus ensures the best stability of the aortic annulus on its whole circumference and should therefore be the preferred surgical technique.
- (iv) Finally, the surgical treatment of acute aortic dissection type A should remain the simplest possible, shortening the time spent on cardiopulmonary bypass as well as the myocardial-protected ischaemic time as much as possible. I personally found a clamp time of 106 min to be rather long for two aortic anastomoses and a selective sinus repair.

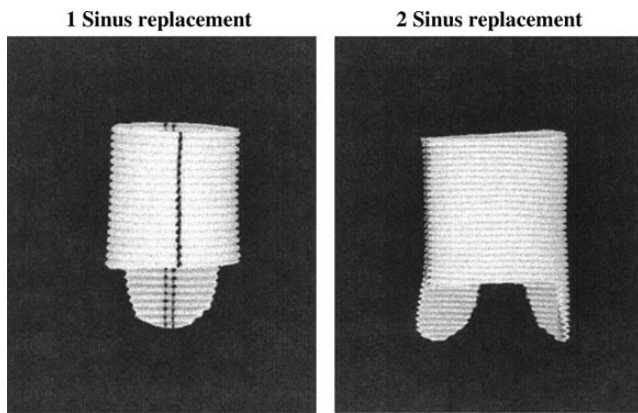


Figure 1: Selective one- and two-sinus repair of the aortic root following the technique of Westaby by shaping the Dacron graft correspondingly (Westaby *et al.* [2]; reproduced with kind permission of Oxford University Press).

In my institutional experience with 40–50 acute type A dissections treated surgically per year, the proportion of suitable candidates for such an approach is probably small. But it is true that the majority of such patients have a proximal dissection into the non-coronary sinus, as the coronary ostia tend to limit the circumferential propagation of the dissecting process around the aortic root.

I would personally not recommend selective sinus repair in younger patients with annulo-aortic ectasia in whom the aortic

annulus is severely dilated (>27–28 mm) and in those with bicuspid valves.

The main advantage of the technique described by Urbanski *et al.* may be the better visualization of the annulus with a small separate piece of the graft to reconstruct the corresponding sinus, thus allowing precise stitches through the more solid tissue of the aortic annulus. One theoretical drawback of the selective sinus repair is that a single Dacron ‘pseudosinus’ is not really created and, therefore, the closing stress of the corresponding leaflet is high, thus limiting, at least theoretically, leaflet durability.

Finally, a selective sinus repair may not avoid further ongoing dilatation of the native annulus, which is not fixed on the whole circumference like in a classical David reimplantation procedure, as this technique reinforces the whole annulus.

REFERENCES

- [1] Urbanski PP, Hijazi H, Dinstak W, Diegeler A. Valve-sparing aortic root repair in acute type A dissection. How many sinuses have to be repaired for curative surgery? *Eur J Cardiothorac Surg* 2013;44:439–44.
- [2] Westaby S, Saito S, Anastasiadis K, Moorjani N, Jin XY. Aortic root remodeling in atheromatous aneurysms: the role of selected sinus repair. *Eur J Cardiothorac Surg* 2002;21:459–64.
- [3] David TE, Armstrong S, Manlhiot C, Mc Crindle BW, Feindel CM. Long-term results of aortic root repair using the reimplantation technique. *J Thorac Cardiovasc Surg* 2012; 10.1016/j.jtcvs.2012.11.075.