

Concise Report

Stiff skin syndrome: evidence for an inflammation-independent fibrosis?

Serena Guiducci^{1,*}, Joerg H. W. Distler^{2,*}, Anna Franca Milia¹, Irene Miniati¹, Veronica Rogai¹, Mirko Manetti³, Fernanda Falcini⁴, Lidia Ibba-Manneschi³, Steffen Gay², Oliver Distler² and Marco Matucci-Cerinic¹

Objectives. Stiff skin syndrome (SSS) is a rare scleroderma-like syndrome of unknown aetiology. A 16-year-old boy presented with thoracic and abdominal asymmetry, and 'orange peel' cutaneous lesions, with fibrotic stone-hard indurations at the buttocks, thighs and arms leading to secondary joint contractures of the extremities. Our aim was to analyse the expression of extracellular matrix (ECM) molecules and pro-fibrotic cytokines in the dermis and epidermis of SSS.

Methods. The diagnosis of SSS was confirmed by clinical and histopathological examination. Collagen type 1 alpha-2 chain (Col1A2), fibronectin-1, thrombospondin-1, TGF- β , connective tissue growth factor (CTGF), IL-6, -1 β , ET-1, Fibroblast growth factor receptor 3 (FGFR-3) and MCP-1 expression was analysed in SSS and age- and sex-matched healthy control skin by real-time PCR. VEGF expression was also studied.

Results. Histopathological examination showed flattened dermal papillae, a scarce presence of sub-epidermal microvessels and mild dermal fibrosis, but no inflammatory infiltrates. In the SSS dermis, the expression of IL-1 β , -6 and MCP-1 was low, whereas VEGF was intensively expressed. No differences were observed for TGF- β , CTGF and ET-1. In contrast, col1A2, fibronectin-1 and thrombospondin-1 were overexpressed in the SSS dermis.

Conclusion. In our SSS patient, an overexpression of ECM proteins was detected, whereas no inflammatory infiltrates or up-regulation of pro-fibrotic cytokines were found. The data suggest that fibrosis in SSS might be independent from inflammation.

KEY WORDS: Stiff skin syndrome, Fibrosis, Cytokines, Extracellular matrix, Inflammation.

Introduction

Stiff skin syndrome (SSS) is clinically characterized by stone-hard skin, leading to a secondary limitation of joint mobility. First manifestations of SSS are usually observed between birth and early childhood [1], and the disease progresses until the skin of the entire body becomes fibrotic with subsequent growth retardation and joint contractures. Skin fibrosis can also lead to decreased costo-vertebral joint mobility with restrictive changes of lung function [1].

SSS was first described in 1968 in a boy with joint contractures and skin changes resembling scleroderma [1] and, in 1971, in four patients showing skin hardening and secondary limitation of joint mobility [2]. Until now, about 30 SSS patients have been described in the literature, with few familial cases [2–4]. The pathogenesis of SSS remains unknown. Initially, an abnormal mucopolysaccharide metabolism limited to the skin, in absence of mucopolysacchariduria, has been suggested [2]. Cutaneous lesions in SSS were attributed to deposits of acid mucopolysaccharides localized within collagen fibres in the dermis and hypodermis [1, 2, 5–7]. Recently, the most relevant modifications were localized in the fascia, which was thickened by a hyalinized collagenous tissue

[3–6, 9]. In skin fibroblasts, collagen synthesis was up-regulated as shown by increased activity of prolylhydroxylase and lysylhydroxylase [9].

The aim of our study was to investigate, in a young boy with SSS, the cutaneous histopathology and the expression of extracellular matrix (ECM) molecules and pro-fibrotic cytokines in order to provide new insights into the pathogenesis of this rare disease.

Case report

A 16-year-old boy, born from healthy unrelated parents, was referred to the Division of Rheumatology of the University of Florence. No one in the family was affected by a similar or fibrosing disease. Medical history revealed that, on the second day after delivery, he had developed severe icterus requiring ex-sanguinis transfusion due to maternal–fetal incompatibility (ABO anti-A). A reduced height–weight growth during the first year was observed but blood tests including serum creatinine, transaminases, glucose and complete blood cell count were within normal limits. Thyroid function was also normal and screening for coeliac disease, arginine-stimulated growth hormone (GH) concentration and metabolic tests were negative.

At 1 year of age, the baby developed thoracic and abdominal asymmetry, and 'orange peel' cutaneous lesions mimicking eosinophilic fasciitis, with induration of the buttocks, thighs and arms. Since then, the skin and the underlying tissues, progressively hardened leading to a reduced extension of the right elbow and both legs.

At 4 years of age, a biopsy from the right thigh including cutaneous and subcutaneous layers and muscle fascia, was taken and showed dense fibrous thickened fascia, three to four times the normal size with increased deposition of collagen. A mild fibrosis of the deep portion of dermis retinacula and mild

¹Department of BioMedicine, Division of Rheumatology and DENOthe Centre, University of Florence, AOUC, Florence, Italy, ²Department of Rheumatology, Center of Experimental Rheumatology, University Hospital Zurich, Zurich, Switzerland, ³Department of Anatomy, Histology and Forensic Medicine and ⁴Department of Pediatrics, Rheumatology Unit, A. Meyer Children's Hospital, University of Florence, Florence, Italy.

Submitted 18 December 2008; revised version accepted 14 April 2009.

Correspondence to: Serena Guiducci, Division of Rheumatology, Department of BioMedicine, University of Florence, AOUC, Villa Monna Tessa, Viale Pieraccini 18, 50139 Florence, Italy. E-mail: serena16@libero.it

*Serena Guiducci and Joerg H. W. Distler equally contributed to this work.

interstitial accumulation of mucopolysaccharides without inflammatory infiltrates or vascular changes were observed. ANAs, ENA antibodies and ACAs were negative and complement fractions (C3 and C4) were normal. Oesophageal and chest X-rays, nail-fold capillaroscopy, ophthalmological and psychological evaluations were negative. Hand X-rays, at 8 years, showed a skeletal age of 4 years.

When the patient was brought to our attention at an age of 16 years the most relevant sign was the stone-hard induration of buttocks and thighs (Fig. 1A). The patient was not receiving any pharmacological treatment. RP, sclerodactyly, fingertip ulcers and dysphagia were not observed. The following tests were normal: complete blood count, kidney and liver functional tests, ESR (Westergren), CRP, C3 and C4, serum lysozyme, serum electrophoresis, serum hormonal estimations (pubertal values), routine urine analysis, abdominal ultrasound and echocardiography. Chest X-ray showed rib cage dysmorphism. Pulmonary function tests revealed a mild reduction of forced vital capacity (FVC) (2.61 vs 3.93 predicted). Osteocalcin was increased to 93.3 ng/ml (normal range 11.1–32.2 ng/ml). Dual X-ray of spinal column at the lumbar level showed significant reduction of bone mass with osteoporosis (*T*-score L4 – 2.74). No calcifications of soft periarticular tissues were observed. ASMA, anti-microsomal,

anti-mitochondrial, ANA, anti-nDNA, ENA, ACA, aPL, anti-thyroid (anti-TG, anti-TSH, anti-TPO) and anti-gastric mucosa antibodies were negative. Nail-fold videocapillaroscopic examination did not reveal any significant alterations.

Despite generalized limitation of joint mobility, there was no evidence of joint inflammation. The child showed difficulty walking due to stiffness of the right lower limb. The clinical features fulfilled the criteria for SSS proposed by Kikuchi [1]: stiff skin, limitation of joint mobility without visceral involvement and no increased amount of mucopolysacchariduria. Hypertrichosis, skin atrophy, dental abnormalities, bone hypoplasia and knuckle pads were not detected in our patient.

Materials and methods

Sample collection

Full-thickness biopsies, approximately 3 × 0.5 cm, were obtained from the clinically involved skin of the right femoral region of the SSS patient. Skin biopsies were also obtained from the same anatomical region of three age- and sex-matched healthy control subjects, who underwent surgery for traumatic lesions. Each biopsy was cut into two samples and processed for histological analysis and real-time PCR. Biopsies were taken after informed consent from parents and approval by the institutional review board was obtained.

Histopathological analysis

For histopathological analysis, the specimens were fixed in 10% buffered formalin and routinely processed for paraffin embedding. Sections (5 μm thick) were processed for haematoxylin and eosin (H&E), Masson's trichrome and alcian blue stainings (Bio-Optica, Milan, Italy). The stained sections were examined under a light microscope (Eclipse E400; Nikon, Tokyo, Japan) and photographed with a digital camera (Coolpix 2500; Nikon).

Immunohistochemistry

Sections were de-waxed and heated in EDTA buffer (pH 8.0) for antigen retrieval. After blocking endogenous peroxidase activity and non-specific site binding, the sections were incubated with a mouse monoclonal antibody against the panendothelial marker von Willebrand factor (vWF; 1:50 dilution; Novocastra Laboratories, Newcastle, UK). The immunoreactivity was detected using biotinylated secondary antibodies and avidin-biotin-peroxidase complex (UltraVision Detection System; LabVision Corporation, Fremont, CA, USA), followed by colour development using 3,3'-diaminobenzidine tetrahydrochloride (Vector, Burlingame, CA, USA) as chromogen. Sections were lightly counterstained with Mayer's haematoxylin, and finally the slides were mounted with Aquatex mounting medium (Merck, Darmstadt, Germany). Normal isotype-matched IgG (Sigma, St Louis, MO, USA) were used at the same concentration to replace the primary antibody, as a negative staining control. The stained sections were examined under a light microscope (Eclipse E400). Three fields (×40 magnification) from two random sections of each biopsy were analysed by a blinded observer. In the examined fields we performed a semiquantitative analysis of vWF-positive blood vessels, considering the distinct areas such as papillary dermis and reticular dermis. The score was defined as follows: +++ = plenty of vessels; ++ = moderate presence of vessels; + = few vessels; +/- = very few vessels; - = hardly any vessels, as described elsewhere [10].

Quantitative real-time PCR

In each biopsy, the epidermis was separated from the dermis for better homogenization of the tissue samples and better comparability of the gene expression. For real-time PCR, total RNA was reverse transcribed into cDNA with Random Hexamers

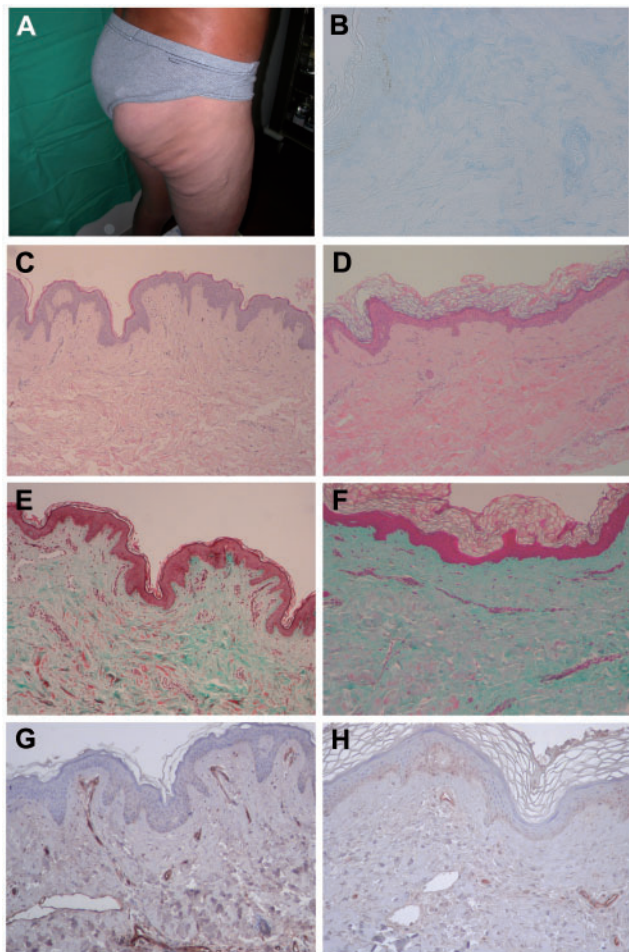


FIG. 1. (A) At the age of 16 years, the most relevant sign was the stone-hard skin induration of only buttocks and thighs. (B) Negative alcian blue staining indicates the absence of mucopolysaccharide deposits between collagen bundles in SSS dermis (original magnification ×40). (C, D) H&E staining of control (C) and SSS (D) skin from the right femoral region (original magnification ×20). No inflammatory infiltrates are present in SSS dermis (D). (E, F) Masson's trichrome staining of control (E) and SSS (F) skin. Mild fibrosis and dense, tightly packed and irregularly distributed collagen bundles are evident in SSS dermis (F) (original magnification ×20). (G, H) Immunostaining for the panendothelial marker vWF in control (G) and SSS (H) skin (blue haematoxylin counterstaining; original magnification ×20).

(Applied Biosystems, Rotkreuz, Switzerland). For quantification of mRNA, SYBR Green real-time PCR [ET-1, connective tissue growth factor (CTGF), IL-6, -1 β , Fibroblast growth factor receptor 3 (FGFR-3), TGF- β , collagen type 1 alpha-2 chain (col1A2), fibronectin-1 and thrombospondin-1] or TaqMan real-time PCR (MCP-1 and VEGF) was performed using the ABI Prism 7700 Sequence Detection System (Applied Biosystems). Specific primer pairs for each gene were designed with the Primer Express software (Applied Biosystems) as described elsewhere [11–15]. Unspecific signals caused by primer dimers or genomic DNA were excluded by dissociation curve analysis, no template controls and samples without enzyme in the reverse transcription (non-RT controls). A pre-developed β -actin assay (Applied Biosystems) was used as an endogenous control to normalize for the amounts of loaded cDNA. Differences were calculated with the threshold cycle (Ct) and the comparative Ct method for relative quantification. All measurements were performed in duplicate.

Results

Analysis of fibrosis

Histopathological findings. The SSS skin showed flattened dermal papillae, and absence of sebaceous glands (Fig. 1D) as compared with control skin (Fig. 1C). In the dermis, tightly packed and irregularly distributed collagen bundles were observed with mild fibrosis, as shown by Masson's trichrome staining (Fig. 1E and F). Alcian blue staining was negative indicating the absence of mucopolysaccharide deposits between collagen bundles (Fig. 1B).

Quantitative real-time PCR. In the dermis, an overexpression of col1A2, fibronectin and thrombospondin-1 was observed, while in the epidermis none of these molecules was different from controls. Interestingly, no difference was detected in the expression of pro-fibrotic mediators (TGF- β , ET-1 and CTGF) both in the epidermis and in the dermis (Table 1).

Analysis of microvessels

Histopathological findings. A loss of sub-epidermal microvessels (+) (Fig. 1G and H) was detected when compared with healthy skin, where microvessels are largely present (+++). In the reticular dermis, a regular distribution and presence of blood vessels were observed (+++).

Quantitative real-time PCR. In the dermis, VEGF was increased in respect to control, while in the epidermis it did not show any difference (Table 1).

Analysis of inflammation

Histopathological findings. No inflammatory infiltrates were detected in the SSS dermis (Fig. 1D).

Quantitative real-time PCR. This analysis showed a different pattern between epidermis and dermis as IL-6, -1 β , FGFR-3 and MCP-1 were normally expressed in the epidermis, but down-regulated in the dermis (Table 1).

Discussion

In the SSS dermis, the present study clearly showed an increase of fibrotic molecules (col1A2, fibronectin-1 and thrombospondin-1) and the presence of irregularly distributed collagen bundles, flattening of dermal papillae and absence of sebaceous glands. Inflammatory mediators (IL-6, -1 β , FGFR-3 and MCP-1) were down-regulated in agreement with the absence of dermal inflammatory infiltrates. No differences in pro-fibrotic cytokines (TGF- β , ET-1 and CTGF) were detected. In a previous work, circulating levels of pro-inflammatory cytokines (IL-6, TNF- α and TGF- β 2), were found to be increased, whereas collagen production and DNA biosynthesis were normal [16]. These differences to our findings might be explained by the different methodological approach. In fact, assessment of these factors in the skin might be more relevant for the pathogenesis of the disease, as serum circulating levels are influenced by a large number of confounding factors. However, different disease stages might also account for controversial results.

Up to date, about 30 cases of SSS have been described in the literature, but the pathogenesis remains still unknown. Usually, SSS is a diagnosis of exclusion, with a distinctive clinical presentation but no pathognomonic laboratory or pathological findings. The clinical differential diagnosis of stone-hard and thickened skin areas includes SSc, sclerodema, eosinophilic fasciitis and scleromyxoedema. The appearance of the disease in early childhood, the limitation of joint mobility, the proximal rather than a distal stiffness and the absence of organ involvement are the main clinical findings that differentiate SSS from SSc [7, 17]. Moreover, microvascular abnormalities, RP and autoantibodies were absent in SSS [18]. However, in our SSS patient, a loss of microvessels was clearly evident at the dermal-epidermal junction and in the papillary dermis, despite the overexpression of VEGF found in the dermis.

SSS is a non-progressive cutaneous disease and involves mostly the buttocks, the trunk and thighs, and does not show increased deposition of acid-mucopolysaccharides in the dermis [16]. In agreement with other authors [16], our data did not show mucopolysaccharide deposits in the dermis. However, Geng *et al.* [18] reported mild deposits of mucopolysaccharides between the collagen bundles throughout the dermis, hypothesizing that SSS could be a localized form of mucopolysaccharidosis [2]. Notably, our patient had no exposure to chemical substances or drugs that have been implicated in the pathogenesis of pseudo-scleroderma [19].

The similarity between SSS and the alterations in collagen metabolism has been put forward in the model of the tight-skin mouse (Tsk-1) [5]. However, the literature remains controversial about the collagen production, as cultured fibroblasts of SSS or of Tsk-1 mice were normal [5], but also revealed an abnormal production of collagen [9]. Our data clearly support the concept of an increased collagen and ECM production in the dermis as shown by quantitative real-time PCR. Richard *et al.* [16] proposed that a primary fibroblast defect or a fascial abnormality needs to be ruled out in this disease. Recently, Liu *et al.* [4] found areas of fascial sclerosis or increased fibroblast cellularity with thickened and sclerotic collagen bundles without associated inflammation. In our case, pro-inflammatory mediators such as IL-1 β and -6 involved in the regulation of dermal fibrosis, were down-regulated in the dermis, suggesting that fibrosis in SSS might be independent from an inflammatory process.

TABLE 1. Quantitative real-time PCR results

	MCP-1	VEGF	ET-1	IL-1 β	TGF- β	CTGF	Col1A2	FGFR-3	IL-6	Fibronectin-1	Thrombospondin-1
Epidermis	1.03	1.4	0.76	0.05	0.95	1.13	1.05	0.86	0.98	1.5	0.7
Derms	0.26	3.31	1.39	0.29	1.4	1.42	11.39	0.18	0.11	4.1	5

The value in SSS is represented as x-fold increased or decreased vs control assumed = 1.

In conclusion, our results suggest that the fibrotic process in SSS might be independent from local inflammation. However, it should be considered that our observations were performed on an SSS patient with long-standing disease, and therefore need to be confirmed in early disease stages. If these findings are confirmed in larger sample numbers, they have direct implications on therapeutic approaches in these patients, as unspecific immunosuppressive treatments are unlikely to be successful in these patients. Future investigations should focus on the dermis, and in particular on ECM components such as collagen fibres and microfibril metabolism. Further studies are warranted to clarify, at different disease stages, the factors involved in the development of dermal fibrosis in SSS.

Rheumatology key messages

- In our SSS case, ECM proteins were overexpressed, whereas no inflammatory infiltrates or pro-fibrotic cytokine up-regulation was found.
- Fibrosis in SSS might be independent from local inflammation.

Acknowledgement

Funding: This study was supported by grants from the University of Florence.

Disclosure statement: O.D. has received grants and/or honoraria and/or served as a consultant for Encysive, Actelion, Ergonex, Array Biopharma, Biovitrum and Fibrogen. All other authors have declared no conflicts of interest.

References

- 1 Kikuchi I, Inoue S, Hamada K, Ando H. Stiff skin syndrome. *Pediatr Dermatol* 1985;3:48–53.
- 2 Esterly NB, McKusick VA. Stiff skin syndrome. *Pediatrics* 1971;47:360–9.
- 3 Helm TN, Wirth PB, Helm KF. Congenital fascial dystrophy: the stiff skin syndrome. *Cutis* 1997;60:153–4.
- 4 Liu T, McCalmont TH, Frieden IJ, Williams ML, Connolly MK, Gilliam AE. The stiff skin syndrome: case series, differential diagnosis of the stiff skin phenotype, and review of the literature. *Arch Dermatol* 2008;144:1351–9.
- 5 Jablonska S, Schubert H, Kikuchi I. Congenital fascia dystrophy: stiff skin syndrome. A human counterpart of the tight skin mouse. *J Am Acad Dermatol* 1989;21:943–50.
- 6 Bodemer C, Habib K, Teillac D, Munich A, De Prost Y. Un nouveau cas de stiff skin syndrome. *Ann Dermatol Venereol* 1991;118:805–6.
- 7 Gilaberte Y, Saenz-de Santamaria MC, Garcia-Latasa FJ, Gonzalez-Mediero I, Zambrano A. Stiff skin syndrome: a case report and review of the literature. *Dermatology* 1995;190:148–51.
- 8 Bundy SE, Lie K. Stiff skin syndrome. *Birth defects* 1975;11:360–1.
- 9 Jablonska S, Groniowski J, Krieg T *et al.* Congenital fascial dystrophy: a non inflammatory disease of fascia: the stiff skin syndrome. *Pediatr Dermatol* 1984; 2:87–97.
- 10 Ibbas-Manneschi L, Niissalo S, Milia AF *et al.* Variations of neuronal nitric oxide synthase in systemic sclerosis skin. *Arthritis Rheum* 2006;54:202–13.
- 11 Distler JH, Jünger A, Huber LC *et al.* Imatinib mesylate reduces production of extracellular matrix and prevents development of experimental dermal fibrosis. *Arthritis Rheum* 2007;56:311–22.
- 12 Distler JH, Jünger A, Caretto D *et al.* Monocyte chemoattractant protein 1 released from glycosaminoglycans mediates its profibrotic effects in systemic sclerosis via the release of interleukin-4 from T cells. *Arthritis Rheum* 2006;54:214–25.
- 13 Distler O, Distler JH, Scheid A *et al.* Uncontrolled expression of vascular endothelial growth factor and its receptors leads to insufficient skin angiogenesis in patients with systemic sclerosis. *Circ Res* 2004;95:109–16.
- 14 Distler JH, Jungel A, Huber LC *et al.* The induction of matrix metalloproteinase and cytokine expression in synovial fibroblasts stimulated with immune cell microparticles. *Proc Natl Acad Sci USA* 2005;102:2892–7.
- 15 Jungel A, Distler O, Schulze-Horsel U *et al.* Microparticles stimulate the synthesis of prostaglandin E2 via induction of cyclooxygenase 2 and microsomal prostaglandin E synthase 1. *Arthritis Rheum* 2007;56:3564–74.
- 16 Richard MA, Grob JJ, Philip N *et al.* Physiopathogenic investigations in a case of familial stiff-skin syndrome. *Dermatology* 1998;197:127–31.
- 17 Braun-Falco O, Plewig G, Wolff HH, Burgdorf WHC, eds. *Diseases of connective tissue*. *Dermatology*, 2nd edn. Berlin: Springer-Verlag, 2000;758.
- 18 Geng S, Lei X, Toyohara JP, Zhan P, Wang J, Tan S. Stiff skin syndrome. *J Eur Acad Dermatol Venereol* 2006;20:729–32.
- 19 Mitchell H, Bolster MB, LeRoy EC. Scleroderma and related conditions. *Med Clin N Am* 1997;81:129–49.