



## Novel therapeutic concepts

# Human atrial fibrillation substrate: towards a specific fibrotic atrial cardiomyopathy

Hans Kottkamp\*

Department of Electrophysiology, Hirslanden Hospital, Witellikerstrasse 40, Zurich 8032, Switzerland

Received 11 March 2013; revised 11 April 2013; accepted 15 May 2013; online publish-ahead-of-print 11 June 2013

The atrial structure/substrate of patients with atrial fibrillation (AF) and clinically similar characteristics can present very differently, and also the 'phenotype' (i.e. paroxysmal, persistent, and long standing persistent) of the arrhythmia cannot comprehensively explain these differences. It was unclear why some patients stay in paroxysmal AF for decades, whereas other patients with the same characteristics progress to persistent AF within a few months. In this review, evidence is described that AF patients without apparent structural heart disease have a chronic fibrotic bi-atrial substrate. There is also evidence from intraoperatively obtained specimen analysis, post-mortem autopsy findings, electroanatomic mapping studies, and delayed enhancement-MRI investigations that a higher mean value of fibrosis is detected in patients with persistent vs. paroxysmal AF but that the variability in the extend of fibrosis is always very high with part of paroxysmal AF patients having massive fibrosis and part of persistent AF patients showing mild fibrosis. In addition, patients undergoing ablation very early after the first AF episodes show already significant fibrosis. These data do not support a causal relationship that AF (significantly) produces fibrosis in the sense of 'AF begets AF' instead of being a consequence of the fibrotic process. In patients with mitral stenosis, evidence for reverse atrial remodelling after commissurotomy was reported, however, in patients with 'lone' AF, the atrial substrate progressed after successful AF elimination indicating towards the independent/progressive disease process of an underlying structural atrial disease called fibrotic atrial cardiomyopathy. Other 'conventional wisdoms' also need to be re-considered including the aetiological role of age and arterial hypertension for human structural atrial remodelling.

### Keywords

Atrial fibrillation • Fibrosis • Cardiomyopathy • Substrate • Pathophysiology

## Different substrates for atrial fibrillation

The observation of tachycardia-induced *experimental electrical* remodelling providing the prerequisites for atrial fibrillation (AF) to persist led to the landmark concept of 'AF begets AF'.<sup>1</sup> However, the underlying pathophysiological process of *human structural* atrial remodelling remained less completely understood.

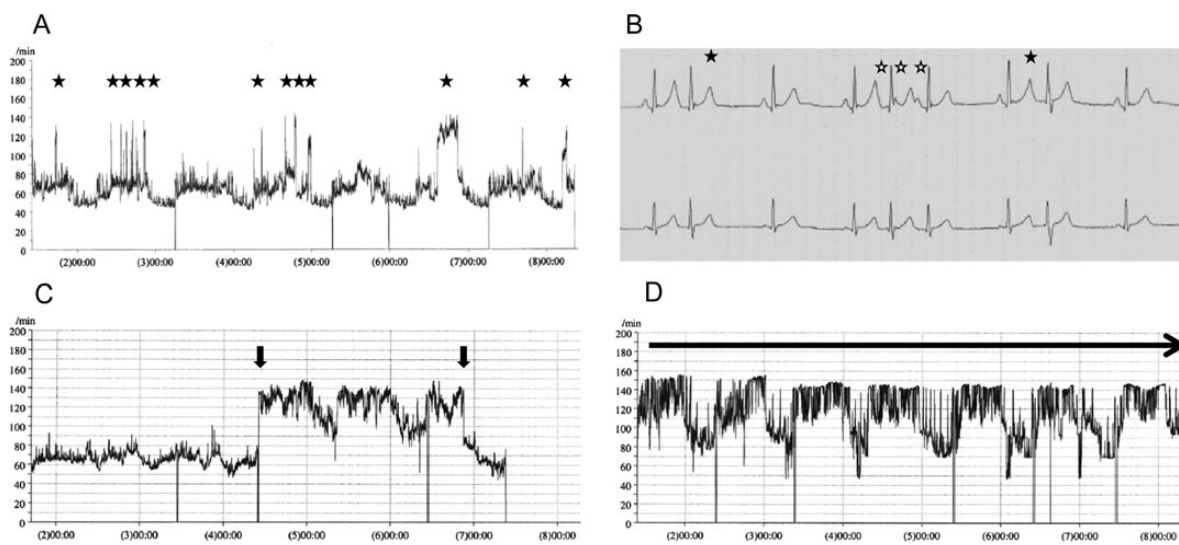
The atria of patients with AF and clinically similar characteristics can present very differently during electroanatomic mapping. Interestingly, even patients with the worst (bi-)atrial substrate may present with paroxysmal (instead of persistent) AF. Left atrial size, underlying heart disease, age, and 'phenotype' (i.e. paroxysmal, persistent, and long-standing persistent) of the arrhythmia alone cannot explain these differences. Some patients with no or limited heart disease stay in paroxysmal AF for decades or 'forever', whereas some patients with the same clinical characteristics progress

to persistent AF directly or within weeks or months (Figure 1). The experimental concepts of atrial remodelling induced by the arrhythmia itself cannot conclusively explain these differences.

The clinical and pathophysiological differentiation between patients where the PV trigger in paroxysmal 'focal' AF is the *only driver* of the disease in a self-perpetuating process and patients with *substrate-based* AF as a *consequence* of, e.g. mitral stenosis with a significantly enlarged left atrium seems clear. In addition, there is now increasing evidence that even in patients with so-called lone or idiopathic AF, the AF is an *arrhythmic manifestation* of a structural atrial disease which has recently been defined and described as *fibrotic atrial cardiomyopathy* (FACM).<sup>2,3</sup> Different expressions can be found from mild (FACM I), moderate (FACM II) to excessive fibrosis (FACM III), and wide clinical variations from asymptomatic to multiple arrhythmic manifestations (including AF, left and/or right atrial re-entrant tachycardia, sinus, and/or AV node disease). Furthermore, the seemingly clear role of co-existing structural cardiovascular

\* Corresponding author. Tel: +41 44 387 2000, Fax: +41 44 387 2001, Email: [hans.kottkamp@hirslanden.ch](mailto:hans.kottkamp@hirslanden.ch)

Published on behalf of the European Society of Cardiology. All rights reserved. © The Author 2013. For permissions please email: [journals.permissions@oup.com](mailto:journals.permissions@oup.com)



**Figure 1** The progression from paroxysmal to persistent atrial fibrillation may be very different in clinically matched patients. (A) 7-day-ECG in a 69-year-old patient with paroxysmal 'lone' atrial fibrillation. The patient had a history of paroxysmal atrial fibrillation of 22 years with frequent episodes per week or even per day (asterisks), however, the individual episodes stayed short within minutes or maximally few hours with no evidence for progression. (B) During sinus rhythm, this patient presented with frequent premature atrial complexes with 'P-on-T' phenomenon (black asterisks) and also frequent atrial salvos (white asterisks). (C) 7-day-ECG in another 69-year-old patient with paroxysmal 'lone' atrial fibrillation. This patient had a short history of atrial fibrillation of only 6 months, however, he presented with atrial fibrillation episodes lasting already >48 h in the initial 7-day-ECG (arrows). Hardly any premature atrial complexes were found during periods of sinus rhythm (not shown). (D) This patient progressed to persistent atrial fibrillation within only another 3 months.

diseases (e.g. hypertension) and also the role of age for human structural atrial remodelling need to be re-analysed.

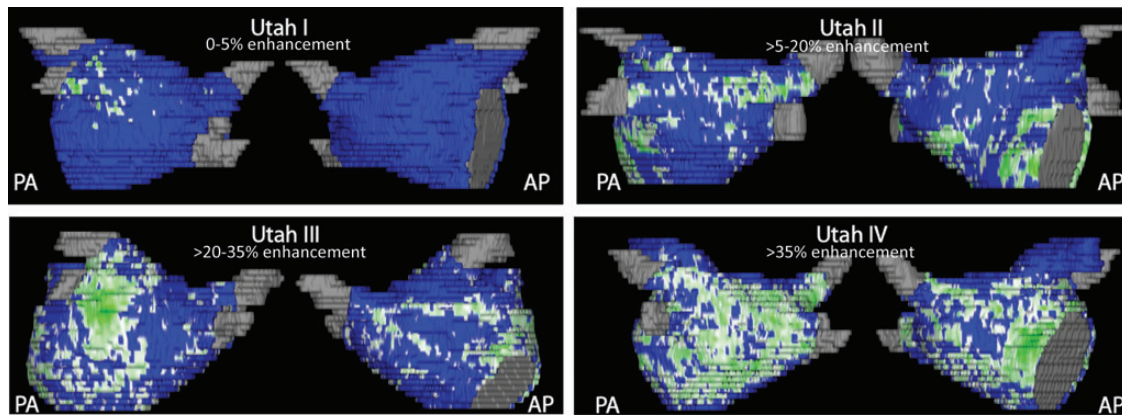
## Atrial structural remodelling and atrial arrhythmias

The presence of interstitial (micro-)fibrosis leading to changes in cellular coupling results in spatial 'non-uniform anisotropic' impulse propagation and is a potential cause of atrial activation abnormalities that may underlie the initiation and perpetuation of re-entrant arrhythmias including fibrillation.<sup>4,5</sup> Importantly, the arrhythmogenic conduction events were described to occur within very small areas, e.g. re-entrant circuits were found as small as  $0.6 \times 2.6$  mm in human atrial bundles. Accordingly, increased fibrosis as a structural correlate of AF has been reported in humans using intra-operatively obtained specimen.<sup>6,7</sup> Cardiac atrial and/or ventricular fibrosis is characterized by excessive accumulation of collagenous material in the extracellular space. Electroanatomic bipolar voltage mapping has been described to define the relationship between anatomic and electrophysiological abnormalities in an experimental model<sup>8</sup> and is now used in clinical electrophysiological studies for substrate description. Alternatively, the utility of delayed enhancement (DE)—magnetic resonance imaging (MRI) was described in detecting, quantifying and localizing atrial fibrosis including four categories of structural changes ('Utah stages I–IV')<sup>9,10</sup> (Figure 2).

## Atrial remodelling in conditions predisposing to atrial fibrillation

John *et al.*<sup>11</sup> described electroanatomic remodelling of the left and right atria in 24 patients with rheumatic mitral stenosis undergoing mitral commissurotomy. Importantly, patients were excluded if they had any suggestion of atrial arrhythmia/AF or other structural heart disease besides mitral stenosis. In comparison with 24 control patients, the patients with mitral stenosis showed—beyond left atrial enlargement—a significantly reduced biatrial voltage (left atrium  $1.8 \pm 0.6$  vs.  $3.6 \pm 0.6$  mV, right atrium  $1.9 \pm 0.6$  vs.  $3.3 \pm 0.5$  mV), reduced conduction velocity, and prolonged effective refractory periods.<sup>11</sup> These abnormalities may clearly play a role in the increased propensity to AF in patients with mitral stenosis. Indeed, patients with mitral stenosis were more susceptible to induction of AF with extrastimulus provocation. Similar left atrial remodelling was described in patients with haemodynamically significant atrial septal defects (but no AF) compared with control patients including significantly reduced left atrial voltage.<sup>12</sup>

Hypertension is another common co-existing factor which is described to be associated with AF. Medi *et al.*<sup>13</sup> described results from electroanatomic mapping and reported right atrial changes in 10 patients with systemic hypertension plus left ventricular hypertrophy (but no AF) compared with 10 control patients. In patients with chronically treated hypertension, a significant slowing of conduction velocity was described. Furthermore, sustained AF was induced in 30% of hypertension patients but no controls. Overall,



**Figure 2** Quantification of left atrial structural remodelling with delayed enhancement magnetic resonance imaging ('Utah I–IV'). Posterior-anterior and anterior-posterior view of enhancement (green) vs. normal tissue (blue) in patients with 'lone' atrial fibrillation (Courtesy of Nassir F. Marrouche, M.D., CARMA Center, Salt Lake City).

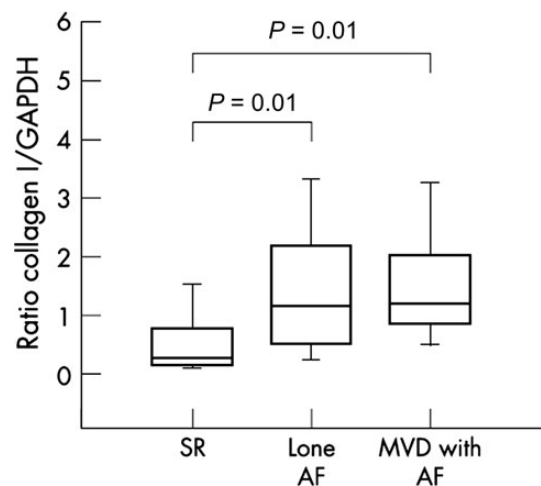
the structural changes in hypertensive patients observed in this study were less pronounced (compared with the changes in patients with mitral stenosis or atrial septal defect). Importantly, the mean right atrial voltage as a surrogate for the structural (i.e. fibrotic) atrial remodelling was identical in the hypertension and control groups ( $2.2 \pm 0.5$  vs.  $2.2 \pm 0.3$  mV).

## A chronic bi-atrial substrate in patients with paroxysmal 'lone' atrial fibrillation

The evidence for a chronic and substantial atrial substrate in patients with lone AF is substantiated by an investigation of extracellular matrix proteins in left atrial tissue of patients with 'lone' AF ( $n = 56$ ), with AF plus mitral valve disease ( $n = 46$ ), and with sinus rhythm ( $n = 16$ ).<sup>7</sup> Left atrial tissue was obtained from atriotomy during cardiac surgery. The association of human AF with fibrosis was shown with collagen concentrations being significantly increased in patients with AF compared with those in sinus rhythm. Importantly, collagen I—which is the major collagenous product of cardiac fibroblasts—was enhanced in 'lone' AF patients even to a similar extent compared with AF in patients with severe mitral valve disease (Figure 3).

Stiles *et al.*<sup>14</sup> investigated 25 patients ( $53 \pm 8$  years) with 'lone' AF during an electrophysiological study after at least 7 days in sinus rhythm and found slower conduction velocity, longer effective refractory periods, and—importantly—significantly lower voltages (left atrium  $1.7 \pm 0.7$  vs.  $3.3 \pm 0.7$  mV, right atrium  $1.7 \pm 0.4$  vs.  $2.9 \pm 0.4$  mV) compared with control patients without AF. These findings confirm a substantial *chronic structural bi-atrial* substrate since the *electrical remodelling* is reversible within a few days.<sup>15</sup> It might be that not all patients with paroxysmal 'lone' AF have an (underdetected) chronic substrate, but many more than assumed (Figure 4).

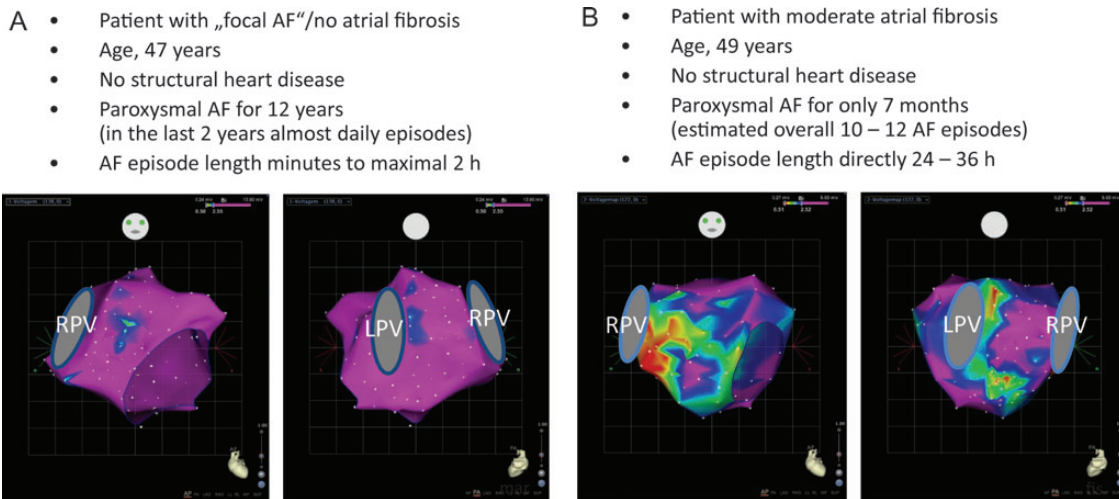
The findings of a chronic substrate in patients with paroxysmal 'lone' AF were recently extended in a DE-MRI study of the left atrial substrate.<sup>16</sup> In that study, 40 of 333 included patients met



**Figure 3** Collagen I expression in left atrial tissue of patients in sinus rhythm, with 'lone' atrial fibrillation, and with atrial fibrillation plus mitral valve disease. Collagen I was enhanced in 'lone' atrial fibrillation patients to a similar extent when compared with atrial fibrillation in patients with severe mitral valve disease (modified from Boldt *et al.*<sup>7</sup>)

criteria for 'lone' AF. The majority of these 'lone' AF patients showed a mild or even moderate degree of left atrial fibrosis, thereby compatible with mild/moderate and/or early forms of FACM I/II.

Is mild-to-moderate left atrial fibrosis necessary on top of PV triggers for AF to sustain for hours or days? Clinically, the time relationship of the trigger initiating AF and the substrate taking over for maintaining AF is largely unknown. Evidence for *short* trigger activity came from a study investigating a surgical left atrial linear lesion concept targeting at the prevention of anatomic left atrial re-entry *without* PV isolation in patients with paroxysmal and persistent AF.<sup>17</sup> After a mean follow-up of 3.6 years, atrial ectopy, atrial runs,



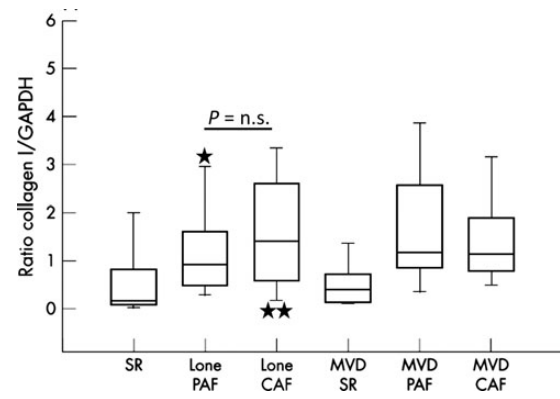
**Figure 4** Electroanatomic left atrial voltage mapping in two patients with paroxysmal ‘lone’ atrial fibrillation. (A) The patient had a long history of paroxysmal atrial fibrillation of 12 years, however, the duration of the atrial fibrillation episodes remained very short and the voltage map still shows no evidence at all of fibrosis. These fibrosis-free maps are found in our experience in <10% of patients with paroxysmal ‘lone’ atrial fibrillation. (B) This patient had a very short history of PAF of only 7 months. Since the patient was extremely symptomatic, an overall cumulative frequency of 10–12 atrial fibrillation episodes could be estimated. However, the fibrotic atrial cardiomyopathy process was already substantial with moderate fibrosis at the time of the clinical advent of paroxysmal atrial fibrillation. Projections from anterior and posterior are given. Voltages of mapping points >2.5 mV are annotated purple (normal voltage), voltages <0.5 mV are indicated red (severely reduced voltage). LPV and RPV, left and right pulmonary veins.

and re-occurrence of AF episodes were analysed by 7-day-ECGs in 30 patients. Overall, 87% of the patients were free from AF. However, atrial ectopy was present in all patients and atrial runs in 83% of the patients with a median of 9 runs per patient/week (range, 1–321). Importantly, the median duration of the atrial runs as a surrogate for the *duration* of PV trigger activity measured only 1.2 s (range, 0.7–25). This may indicate that a chronic atrial *substrate* is indeed necessary for even relatively short episodes of AF to sustain.

## More atrial substrate in patients with persistent vs. paroxysmal atrial fibrillation? Fibrotic changes as cause for or consequence of atrial fibrillation?

If the clinical AF episodes were the critical stimulus for the development of structural (fibrotic) remodelling, then there should be a step-wise increase with longer history and/or longer episodes of AF (higher cumulative AF burden), and especially a clear increase in fibrosis when patients with paroxysmal and persistent AF are compared. However, this does not seem to be the case.

Differences in patients with paroxysmal and persistent AF were analysed in the study with left atriotomy specimen obtained during cardiac surgery.<sup>7</sup> Importantly, there was a *similar* degree of enhanced collagen expression in paroxysmal and persistent AF (Figure 5). While there was a tendency of an increased *mean* fibrosis level in patients with persistent AF vs. paroxysmal AF, the *variation* within the two groups was clearly very high and a statistical difference in fibrosis extent, therefore, could not be demonstrated.



**Figure 5** Collagen I expression in human atrial tissue from patients with sinus rhythm, ‘lone’ paroxysmal atrial fibrillation and persistent (CAF) atrial fibrillation, and in patients with mitral valve disease plus sinus rhythm, paroxysmal atrial fibrillation, and CAF, respectively. Note, the overlapping wide variation/range of collagen I in patients with paroxysmal atrial fibrillation and CAF, with some paroxysmal atrial fibrillation patients having excessive fibrosis (asterisks) and some CAF patients having mild fibrosis (double asterisks) (modified from Boldt et al.<sup>7</sup>).

Platonov et al.<sup>18</sup> confirmed and extended the results from Boldt et al. by investigating structural abnormalities in post-mortem autopsy atrial specimen from 30 patients in three age-matched groups of patients without AF history, with paroxysmal AF, or with permanent AF. Atrial tissue samples were collected from the right atrium, Bachmann’s bundle, and from the posterior left atrial wall.



Patients with any history of AF had a three- to five-fold greater extent of fibrosis compared with patients without AF history. A comparison revealed a greater extent of fibrosis in patients with permanent AF compared with patients with paroxysmal AF. However, these differences were statistically significant in the left atrial tissue specimen only at the superior PV level, whereas no significant differences between patients with paroxysmal and permanent AF were found in the posterior left atrial wall and at the inferior PV level.<sup>18</sup> Importantly, the *variation* in the data obtained from the posterior level between patients with paroxysmal and permanent AF were very high. In addition, the extent of fibrosis showed no clear correlation with the duration of AF history.

Recently, Teh *et al.*<sup>19</sup> described electroanatomic remodelling of the left atrium in paroxysmal ( $n = 17$ ) and persistent ( $n = 14$ ) AF patients without structural heart disease compared with control patients ( $n = 15$ ). Again, a lower voltage in the AF patients was found compared with the control patients. The mean left atrial voltage difference between patients with paroxysmal and persistent AF even reached a low statistical difference, however, in half of the left atrial areas that were investigated, this difference was not statistically significant.

Oakes *et al.*<sup>9</sup> reported on the DE-MRI quantification of left atrial structural remodelling in 81 patients with AF. Mild enhancement was found in 43 patients, 28 of these (65%) had paroxysmal AF. However, 15 of these patients (35%) still had only mild enhancement but were already in persistent AF. Furthermore, from the 30 patients with moderate enhancement, 43% still presented with paroxysmal and 57% with persistent AF, respectively, again indicating towards the high variability of structural remodelling in patients with paroxysmal and persistent AF.

## Atrial fibrillation and the association to age and other co-existing cardiovascular diseases

From an *epidemiological* point of view, human ageing certainly is associated with an increased likelihood of developing AF.<sup>20</sup> However, a potential causative *aetiological* relationship of human age and development of AF is far less well established. Indeed, data on qualitative and quantitative analyses of bi-atrial human tissue from patients with non-valvular AF are scarce. In the human autopsy investigation, Platonov *et al.*<sup>18</sup> reported on the association between structural changes in the human atria, age, and history of AF. In contradiction to the 'conventional wisdom' about the association between human age and atrial fibrosis, Platonov *et al.* were not able to detect *any* correlation between patient age and increase in fibrosis extent. Furthermore, atrial samples from age-matched arrhythmia-free patients contained 'negligibly' low amounts of fibrofatty tissue, even in very old patients. These autopsy results match well with data from an electroanatomic mapping study investigating the impact of age on left and right atrial voltage.<sup>21</sup> In that study, the mean bipolar voltage in young patients  $\leq 40$  years was somewhat higher compared with older patients; however, there were hardly any differences in the age group 51–60 compared with 61–70 and beyond 70 years. Furthermore, age was also *equally* distributed in the four DE-MRI fibrosis grade groups (mean age 69 years in the total non-lone AF group, 68 years in the Utah I group, 66 years in

the Utah II group, 68 years in the Utah III group, and 70 years in the Utah IV group, respectively).<sup>16</sup>

Similar to the *assumed* aetiological association of human ageing and AF, co-existing cardiovascular diseases (e.g. hypertension) are also thought to play an important aetiological role in the development of AF. Mahnkopf *et al.*<sup>16</sup> compared the left atrial structural changes using DE-MRI in patients with 'lone' AF ( $n = 40$ ) vs. those with 'classical' comorbidities ( $n = 293$ ). Importantly, the degree of left atrial structural remodelling was found to be completely *independent* of co-morbidities. Furthermore, the distribution of groups Utah I–IV showed no significant differences between patients with lone AF and non-lone AF. For example, fibrosis grade Utah II was found in 65 vs. 64% of lone AF and non-lone AF patients, and fibrosis grade Utah III in 23 vs. 23% of lone AF and non-lone AF patients, respectively.<sup>16</sup> In addition, co-existing cardiovascular diseases were *equally* distributed in the four fibrosis grade groups, e.g. hypertension in 66% of patients of the total non-lone AF group, in 76% of the Utah I group, in 67% of the Utah II group, in 61% of the Utah III group, and in 68% of the Utah IV group, respectively. These data thereby confirm the autopsy study data, where the comorbidity status expressed in the CHA<sub>2</sub>DS<sub>2</sub>-VASc score measured  $3.8 \pm 1.8$  in patients with AF vs.  $4.3 \pm 1.9$  in patients without AF.<sup>18</sup> These data also confirm results from electroanatomic mapping, where no atrial voltage differences could be detected in patients with (arrhythmia free) hypertension patients vs. control patients.<sup>13</sup>

## Evidence for reverse human atrial structural remodelling?

John *et al.*<sup>22</sup> investigated the potential for *reverse* human atrial remodelling in 21 patients undergoing mitral commissurotomy for treatment of severe mitral stenosis. Bi-atrial voltage mapping was performed before and after commissurotomy—and in 14 patients, right atrial mapping was repeated after  $\geq 6$  months. Importantly, a *further* significant increase in atrial voltage was demonstrated late after interventional treatment from  $1.8 \pm 0.7$  to  $2.8 \pm 0.6$  mV. Therefore, late after reversal of chronic stretch, a progressive improvement in bipolar voltage could be shown indicating the potential for *reverse* human atrial remodelling.

If AF itself were the stimulus for the development of this fibrotic substrate in patients without structural heart disease, it could be hypothesized that this substrate was reversed after successful AF elimination. Teh *et al.*<sup>23</sup> performed right atrial electroanatomic maps in 11 control patients and 11 'lone' AF patients undergoing catheter ablation at baseline *plus*  $\geq 6$  months following successful elimination of AF. The substrate did *not* appear to reverse after successful ablation of AF. In contrast, there was a *progressive* substrate remodelling 6–14 months after successful catheter ablation with further decrease in atrial bipolar voltage and further prolongation of regional refractoriness.

## Fibrotic atrial cardiomyopathy: diagnosis, causality, and implications for ablation

Electroanatomic mapping and DE-MRI are potential clinical *diagnostic* tools. Electroanatomic mapping, however, has all limitations of

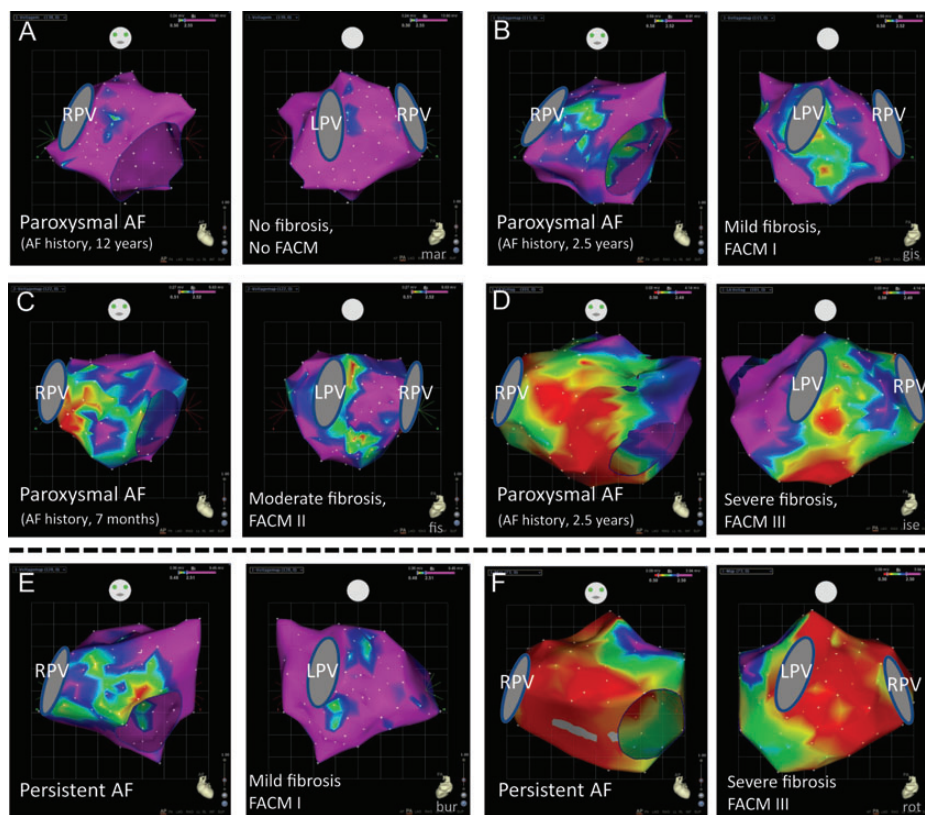
invasive procedures and does not allow diagnostic follow-up investigations. In contrast, the potential of DE-MRI for detecting and quantifying atrial fibrosis looks attractive as a non-invasive, repeatable diagnostic tool. Recently, pre-operatively elevated serum markers of collagen synthesis (PICP) have been reported to be associated with post-surgical AF.<sup>24</sup> Furthermore, a linear correlation between PICP and left atrial fibrosis was described. This raises the potential option of identifying *subclinical* FACM in general before the advent of AF. Overall, the definition and the understanding of the term 'lone' AF needs to be modified in the future. FACM to date is difficult to detect by conventional means but constitutes a substantial and chronic structural atrial disease posing the patient to the risk of developing AF and other manifestations.<sup>3</sup>

Genetics seem to play a key role in FACM. A familial aggregation of lone AF in young persons has been described recently.<sup>25</sup> Frequently, a familiar appearance of clinical findings indicating towards FACM can be observed. However, genetic analyses of specific subgroups of AF so far are limited. Besides the key player genetics, additional pathophysiological aspects might include an inflammatory process as indicated by studies from Frustaci *et al.*<sup>26</sup> on biopsy findings in patients with lone AF, Chung *et al.*<sup>27</sup> on C-reactive protein elevation in patients with atrial arrhythmias, and findings on the role of steroids to prevent AF recurrences after ablation.<sup>28</sup>

In patients with 'pure' focal AF (i.e. without atrial fibrosis), PV isolation can be considered a *curative* treatment option. In patients with the potentially progressive disease FACM, where AF is a manifestation of a structural atrial disease, catheter ablation can also effectively treat AF but ablation cannot be considered curative. Verma *et al.*<sup>29</sup> reported that pre-existent left atrial scarring in patients undergoing ablation was an independent predictor of procedural failure, which was confirmed in DE-MRI studies.<sup>9,10</sup> Progressive atrial remodelling after ablation in FACM cases may explain late recurrences despite durable PV isolation and development of 'new' arrhythmias. In addition, the association of left atrial fibrosis and the risk of stroke in patients with AF will need to be considered for oral anticoagulation strategies in the future.<sup>3,30</sup>

## Fibrotic atrial cardiomyopathy: summary and outlook

There is substantial evidence that the majority of patients without *apparent* structural heart disease (so-called 'lone' AF) has a chronic fibrotic bi-atrial substrate.<sup>7,14,16</sup> A higher *mean* value of fibrosis is detected in patients with persistent vs. paroxysmal AF.<sup>7,9,18,19</sup> However, the *variability* in the extend of fibrosis in patients with



**Figure 6** Electroanatomic left atrial voltage mapping in patients with 'lone' paroxysmal (A–D) and persistent (E–F) atrial fibrillation. The electroanatomic maps of the patients with paroxysmal atrial fibrillation show a wide variation of voltage distribution with no correlation to atrial fibrillation history duration: (A) no fibrosis; (B) mild fibrosis; (C) moderate fibrosis; (D) extensive fibrosis. (E and F) Also in patients with persistent atrial fibrillation, a wide variation of voltage distribution is found. Projection from anterior and posterior is given. Voltages of mapping points  $>2.5$  mV are annotated purple (normal voltage), voltages  $<0.5$  mV are indicated red (severely reduced voltage). LPV and RPV, left and right pulmonary veins.

paroxysmal and persistent AF is very high with part of paroxysmal AF patients having massive fibrosis as well as part of persistent AF patients showing mild fibrosis.<sup>7,9,18,19</sup> Thus, these data do not support a *causal* relationship that AF (significantly) *produces* fibrosis in the sense of 'AF begets AF' instead of being a *consequence* of the fibrotic process in FACM (Figure 6). There are obviously patients with 'lone' AF, where the substrate is already very advanced with massive bi-atrial fibrosis before the advent of AF.<sup>3</sup> Accordingly, no clear correlation could be demonstrated between the extent of fibrosis and the duration of AF history.<sup>16,18</sup> The analysed studies with different methodologies are very consistent, however, the relatively small size of some of these studies necessitates confirmation and extension in future trials.

Other 'conventional wisdoms' also need to be re-considered. In the autopsy investigation specifically addressing the role of age, no correlation at all could be detected between patient age and fibrosis extent.<sup>18</sup> Instead, the *clinical manifestation* of FACM with cardiac arrhythmias in most patients occurs in advanced ages ( $\geq 60$  years) and less frequently in younger ages. In the same line, the degree of left atrial structural remodelling was found to be *independent* of comorbidities (e.g. hypertension, diabetes) in DE-MRI and autopsy studies.<sup>16,18</sup> Given these results that age and 'classical' co-morbidities have no association with the extent of atrial fibrosis, these data all indicate that the chronic bi-atrial substrate of patients with AF is the result of a specific FACM. Further striking evidence for the existence of FACM in patients with 'lone' AF comes from electroanatomic mapping studies on the reversibility of human atrial structural remodelling.<sup>22,23</sup> In patients with mitral stenosis, there was clear evidence for *reverse* atrial remodelling after commissurotomy. However, in patients with 'lone' AF, the atrial substrate *progressed* despite successful AF elimination indicating towards the *independent* and potentially *progressive* disease process of FACM.

Different expressions of the FACM disease exist from mild-to-severe fibrosis (FACM I–III), and with wide clinical variations from asymptomatic cases to cases with multiple arrhythmic manifestations, atrial mechanical dysfunction as well as thromboembolic complications.<sup>3</sup> Clinically, the co-existence of sick sinus node plus paroxysmal AF ('bradycardia–tachycardia–syndrome') is the most frequent FACM manifestation *combination*.<sup>3,31</sup>

Recently, localized electrical 'rotors' have been described as prevalent sustaining mechanisms of human AF, and catheter ablation at patient-specific sources improved clinical outcome.<sup>32</sup> It might be speculated that these patient-specific sources correlate with areas of atrial fibrosis where the site-specific *micro-architecture* of connective tissue fibres and the remaining myocardial fibres allows re-entrant/rotor activation to occur and to sustain. The combination of localizing atrial fibrosis *plus* mapping of specific functional areas allowing re-entrant/rotor activation may hold promise for catheter-based AF substrate modification in the future.

**Conflict of interest:** H.K. served as a consultant for Biosense Webster within the past 2 years.

## References

- Wijffels MC, Kirchhof CJ, Dorland R, Allesie MA. Atrial fibrillation begets atrial fibrillation. A study in awake chronically instrumented goats. *Circulation* 1995;**92**: 1954–1968.
- Kottkamp H. Atrial fibrillation substrate: the 'unknown species'—from lone atrial fibrillation to fibrotic atrial cardiomyopathy. *Heart Rhythm* 2012;**9**:481–482.
- Kottkamp H. Fibrotic atrial cardiomyopathy: a specific disease/syndrome supplying substrates for atrial fibrillation, atrial tachycardia, sinus node disease, AV node disease, and thromboembolic complications. *J Cardiovasc Electrophysiol* 2012;**23**: 797–799.
- Spach MS, Dolber PC. Relating extracellular potentials and their derivatives to anisotropic propagation at a microscopic level in human cardiac muscle: evidence for electrical uncoupling of side to side fiber connections with increasing age. *Circ Res* 1986; **56**:356–371.
- Spach MS, Boineau JP. Microfibrosis produces electrical load variations due to loss of side-to-side cell connections: a major mechanism of structural heart disease arrhythmias. *Pacing Clin Electrophysiol* 1997;**20**:397–413.
- Kostin S, Klein G, Szalay Z, Hein S, Bauer EP, Schaper J. Structural correlate of atrial fibrillation in human patients. *Cardiovasc Res* 2002;**54**:361–379.
- Boldt A, Wetzel U, Lauschke J, Weigl J, Gummert J, Hindricks G, Kottkamp H, Dhein S. Fibrosis in left atrial tissue of patients with atrial fibrillation with and without underlying mitral valve disease. *Heart* 2004;**90**:400–405.
- Callans D, Ren JF, Michele J, Marchlinski FE, Dillon SM. Electroanatomic left ventricular mapping in the porcine model of healed anterior myocardial infarction. Correlation with intracardiac echocardiography and pathological analysis. *Circulation* 1999;**100**:1744–1750.
- Oakes RS, Badger TJ, Kholmovski EG, Akoum N, Burgon NS, Fish EN, Blauer JJE, Rao SN, DiBella EVR, Segerson NM, Daccarett M, Windfelder J, McGann CJ, Parker D, MacLeod RS, Marrouche NF. Detection and quantification of left atrial structural remodeling with delayed-enhancement magnetic resonance imaging in patients with atrial fibrillation. *Circulation* 2009;**119**:1758–1767.
- Akoum N, Daccarett M, McGann C, Segerson N, Vergara G, Kuppalahally S, Badger T, Burgon N, Haslam T, Kholmovski E, MacLeod R, Marrouche N. Atrial fibrosis helps select the appropriate patient and strategy in catheter ablation of atrial fibrillation: A DE-MRI guided approach. *J Cardiovasc Electrophysiol* 2011;**22**: 16–22.
- John B, Stiles MK, Kuklik P, Chandy ST, Young GD, Mackenzie L, Szumowski L, Joseph G, Jose J, Worthley SG, Kalman JM, Sanders P. Electrical remodelling of the left and right atria due to rheumatic mitral stenosis. *Eur Heart J* 2008;**29**: 2234–2243.
- Roberts-Thomson KC, John B, Worthley SG, Brooks AG, Stiles MK, Lau DH, Kuklik P, Shipp NJ, Kalman JM, Sanders P. Left atrial remodeling in patients with atrial septal defects. *Heart Rhythm* 2009;**6**:1000–1006.
- Medi C, Kalman JM, Spence SJ, Teh AW, Lee G, Bader I, Kaye DM, Kistler PM. Atrial electrical and structural changes associated with longstanding hypertension in humans: Implications for the substrate for atrial fibrillation. *J Cardiovasc Electrophysiol* 2011;**22**:1317–1324.
- Stiles MK, John B, Wong CX, Kuklik P, Brooks AG, Lau DH, Dimitri H, Roberts-Thomson KC, Wilson L, De Sciscio P, Young GD, Sanders P. Paroxysmal lone atrial fibrillation is associated with an abnormal atrial substrate: characterizing the 'second factor'. *J Am Coll Cardiol* 2009;**53**:1182–1191.
- Garratt CJ, Duytschaever M, Killian M, Dorland R, Mast F, Allesie MA. Repetitive electrical remodeling by paroxysms of atrial fibrillation in the goat: no cumulative effect on inducibility or stability of atrial fibrillation. *J Cardiovasc Electrophysiol* 1999; **10**:1101–1108.
- Mahnkopf C, Badger TJ, Burgon NS, Daccarett M, Haslam TS, Badger CT, McGann CJ, Akoum N, Kholmovski E, MacLeod RS, Marrouche NF. Evaluation of the left atrial substrate in patients with lone atrial fibrillation using delayed-enhanced MRI: implications for disease progression and response to catheter ablation. *Heart Rhythm* 2010;**7**:1475–1481.
- Tanner H, Hindricks G, Kobza R, Dorszewski A, Schirdewahn P, Piorowski C, Gerd-Li JH, Kottkamp H. Trigger activity more than three years after left atrial linear ablation without pulmonary vein isolation in patients with atrial fibrillation. *J Am Coll Cardiol* 2005;**46**:338–343.
- Platonov PG, Mitrofanova LB, Orshanskaya V, Ho SY. Structural abnormalities in atrial walls are associated with presence and persistency of atrial fibrillation but not with age. *J Am Coll Cardiol* 2011;**58**:2225–2232.
- Teh AW, Kistler PM, Lee G, Medi C, Heck PM, Spence SJ, Sparks PB, Morton JB, Kalman JM. Electroanatomic remodeling of the left atrium in paroxysmal and persistent atrial fibrillation patients without structural heart disease. *J Cardiovasc Electrophysiol* 2012;**23**:232–238.
- Miyasaka Y, Barnes ME, Gersh BJ, Cha SS, Bailey KR, Abhayaratna W, Seward JB, Tsang TS. Secular trends in incidence of atrial fibrillation in Olmsted County, Minnesota, 1980 to 2000, and implications on the projections for future prevalence. *Circulation* 2006;**114**:119–125.
- Tuan TC, Chang SL, Tsao HM, Tai CT, Lin YJ, Hu YF, Lo LW, Udyavar AR, Chang CJ, Tsai WC, Tang WH, Suenari K, Huang SY, Lee PC, Chen SA. The impact of age on the electroanatomical characteristics and outcome of catheter



- ablation in patients with atrial fibrillation. *J Cardiovasc Electrophysiol* 2010;**21**: 966–972.
22. John B, Stiles MK, Kuklik P, Brooks AG, Chandy ST, Kalman JM, Sanders P. Reverse remodeling of the atria after treatment of chronic stretch in humans. *J Am Coll Cardiol* 2010;**55**:1217–1226.
  23. Teh AW, Kistler PM, Lee G, Medi C, Heck PM, Spence SJ, Morton JB, Sanders P, Kalman JM. The long-term effects of catheter ablation for lone atrial fibrillation. Progressive atrial electroanatomic substrate remodelling despite successful ablation. *Heart Rhythm* 2012;**9**:473–480.
  24. Swartz MF, Fink GW, Sarwar MF, Hicks GL, Yu Y, Hu R, Lutz CJ, Taffet SM, Jalife J. Elevated pre-operative serum peptides for collagen I and III synthesis result in post-surgical atrial fibrillation. *J Am Coll Cardiol* 2012;**60**:1799–1806.
  25. Oyen N, Ranthe MF, Carstensen L, Boyd HA, Olesen MS, Olesen SP, Wohlfahrt J, Melbye M. Familial aggregation of lone atrial fibrillation in young persons. *J Am Coll Cardiol* 2012;**60**:917–921.
  26. Frustaci A, Chimenti C, Bellocci F, Morgante E, Russo MA, Maseri A. Histological substrate of atrial biopsies in patients with lone atrial fibrillation. *Circulation* 1997;**96**: 1180–1184.
  27. Chung MK, Martin DO, Sprecher D, Wazni O, Kanderian A, Carnes CA, Bauer JA, Tchou PJ, Niebauer MJ, Natale A, Van Wagoner DR. C-reactive protein elevation in patients with atrial arrhythmias. *Circulation* 2001;**104**:2886–2891.
  28. Koyama T, Tada H, Sekiguchi Y, Arimoto T, Yamasaki H, Kuroki K, Machino T, Tajiri K, Zhu XD, Kanemoto-Igarashi M, Sugiyasu A, Kuga K, Nakata Y, Aonuma K. Prevention of atrial fibrillation recurrence with corticosteroids after radiofrequency catheter ablation. *J Am Coll Cardiol* 2010;**56**:1463–1472.
  29. Verma A, Wazni OM, Marrouche NF, Martin DO, Kilicaslan F, Minor S, Schweikert RA, Saliba W, Cummings J, Burkhardt JD, Bhargava M, Belden WA, Abdul-Karim A, Natale A. Pre-existent left atrial scarring in patients undergoing pulmonary vein antrum isolation. An independent predictor of procedural failure. *J Am Coll Cardiol* 2005;**45**:285–292.
  30. Daccarett M, Badger TJ, Akoum N, Burgon NS, Mahnkopf C, Vergara G, Kholmovski E, McGann CJ, Parker D, Brachmann J, MacLeod RS, Marrouche NF. Association of left atrial fibrosis detected by delayed-enhancement magnetic resonance imaging and the risk of stroke in patients with atrial fibrillation. *J Am Coll Cardiol* 2011;**57**:831–838.
  31. Akoum N, McGann C, Vergara G, Badger T, Ranjan R, Mahnkopf C, Kholmovski E, MacLeod R, Marrouche N. Atrial fibrosis quantified using late Gadolinium enhancement MRI is associated with sinus node dysfunction requiring pacemaker implant. *J Cardiovasc Electrophysiol* 2012;**23**:44–50.
  32. Narayan SM, Krummen DE, Shivkumar K, Clopton P, Rappel WJ, Miller JM. Treatment of atrial fibrillation by the ablation of localized sources. *J Am Coll Cardiol* 2012;**60**:628–636.

## CARDIOVASCULAR FLASHLIGHT

doi:10.1093/eurheartj/eh224

Online publish-ahead-of-print 25 July 2013

### Epicardial Wolff–Parkinson–White ablation

Christoph Scharf\* and Lam Dang

Clinic im Park, Zürich, Switzerland

\* Corresponding author. Tel: +41 12558762, Fax: +41 12554401, Email: christoph.scharf@gmail.com

A 45-year-old female patient without structural heart disease was referred for redo Wolff–Parkinson–White (WPW) ablation after an unsuccessful endocardial procedure. The refractory period of the accessory pathway had been measured at 230 ms and antiarrhythmic treatment with flecainide was unsuccessful.

- (1) The surface electrogram shows the largest negative  $\delta$ -wave in lead III.
- (2) During endocardial mapping of the ventricular insertion the earliest activation was found near the coronary sinus ostium (x); however, radiofrequency application was not successful. Note the morphology of the unipolar signal (Abl uni) with an initially positive small spike (red arrow) resulting from epi-endocardial activation followed by the broad negative ventricular activation signal.

- (3) Epicardial mapping via subxiphoidal access showed the earliest signal (XX) opposite to the endocardial site (X). The distance between the two locations was 1.5 cm. Note the morphology with an entirely negative small pathway spike (red arrow) followed by the broad negative ventricular activation signal. Irrigated radiofrequency ablation was successful after 25 s and increase of power from 20 to 30 W.

Epicardial access can be necessary, if the largest negative  $\delta$ -wave is in lead III on the surface ECG. The morphology of the unipolar signal indicates the true epicardial origin of the ventricular pathway insertion. Success can be observed even after delayed response to RF delivery.

In Panel 1: ECG, electrocardiogram; LAO, left anterior oblique; Abl, ablation electrode; CS, coronary sinus; CSp, coronary sinus electrode proximal; CSd, coronary sinus electrode distal; RV, right ventricular electrode; LAT, local activation time measured relative to onset of QRS signals on surface ECG. The local activation time is measured conventionally (middle) and visualized in a coloured Carto-3D map (red earliest).

