



European Journal of Cardio-thoracic Surgery 28 (2005) 163

EUROPEAN JOURNAL OF
CARDIO-THORACIC
SURGERYwww.elsevier.com/locate/ejcts

Images in cardio-thoracic surgery

Giant saphenous vein graft aneurysm

Enrico Ferrari*, Frank Stumpe, Ludwig Karl von Segesser

Department of Cardiovascular Surgery, Centre Hôpitalier Universitaire Vaudois (CHUV), 46 Rue du Bugnon, CH-1011 Lausanne, Switzerland

Received 10 January 2005; accepted 9 March 2005; Available online 22 April 2005

Keywords: Saphenous vein; Aneurysm; Graft

A 71-year-old man was operated in 1982. A single venous aorto-coronary bypass to the left anterior descending coronary artery was performed. Twenty-two years later, we re-operated this patient. Intraoperatively, we found

a giant saphenous vein graft aneurysm (Figs. 1 and 2). Its diameter was approximately 5 cm. Three new grafts were performed with excellent outcome.

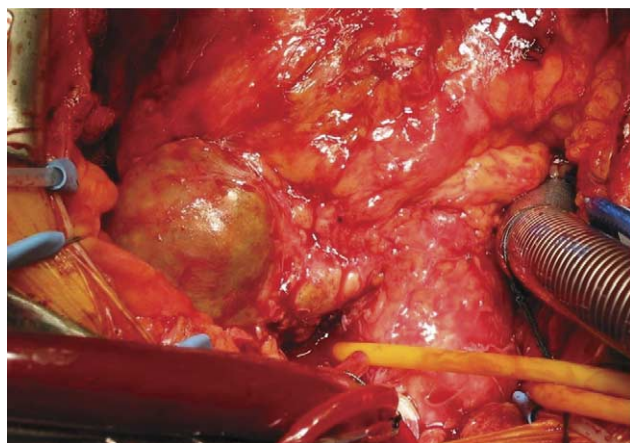


Fig. 1. View of the giant saphenous vein graft aneurysm through the median sternotomy. This aneurysm is approximately 5 cm of diameter and is a part of a 22-year-old saphenous vein graft.

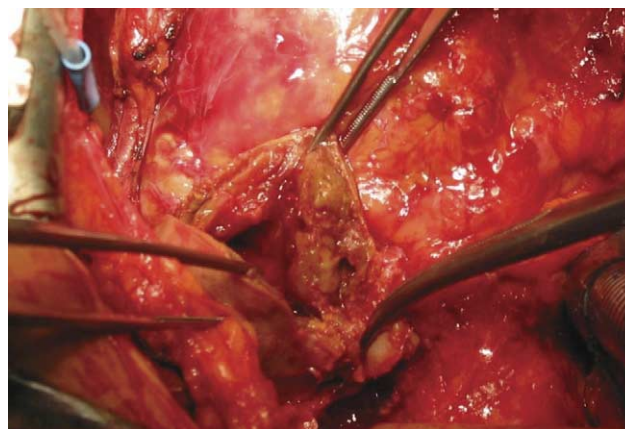


Fig. 2. The aneurysm has been opened. Inside it is possible to see old blood and thrombotic material.

* Corresponding author. Tel.: +41 79 310 1386; fax: +41 21 314 2278.
E-mail address: enrico.ferrari@hospvd.ch (E. Ferrari).