



Case report

Delayed visceral malperfusion in aortic dissection—successful surgical revascularization using a saphenous vein graft

Beat Kipfer^a, Hannu Savolainen^a, Bernhard Egger^b, Thierry P. Carrel^{a,*}^a Department of Cardiovascular Surgery, University Hospital, CH-3010 Bern, Switzerland^b Department of Visceral and Transplantation Surgery, University Hospital, CH-3010 Bern, Switzerland

Received 27 June 2005; received in revised form 27 June 2005; accepted 25 August 2005; Available online 4 November 2005

Abstract

Obstruction of the thoracoabdominal aorta and/or its branches with subsequent organ ischemia is a frequent complication of aortic dissection. Surgical and percutaneous fenestrations have been used and endovascular stenting has emerged as an additional less invasive approach. In some cases, surgical revascularization may be the most successful procedure. We report two patients who underwent surgical revascularization of the celiac trunk and superior mesenteric artery for delayed abdominal malperfusion due to aortic dissection.

© 2005 Elsevier B.V. All rights reserved.

Keywords: Aortic dissection; Intestinal malperfusion

1. Introduction

Patients suffering from acute aortic dissection may present with malperfusion of aortic branches [1]. Compromised flow of the celiac trunk or superior mesenteric artery (SMA) has a dramatic impact on outcome [2]. Improvement of malperfusion has been reported following surgical and endovascular fenestration. The role of endovascular stenting is controversial [3–6].

We report surgical revascularization with an autologous saphenous vein graft in two patients presenting with delayed malperfusion caused by distal aortic dissection leading to hepatic and mesenteric ischemia despite aortic fenestration.

2. Case 1

A 46-year-old patient was admitted for an acute type B dissection presenting with oliguria and peripheral malperfusion. Surgical fenestration was performed. The infrarenal aorta was transected and a bifurcated Dacron prosthesis anastomosed to the common iliac arteries. Initial recovery was uneventful and perfusion of renal and femoral arteries was confirmed by duplex scan.

Ten days later, he re-presented with severe chest pain. Retrograde dissection into the aortic arch and the ascending

aorta was diagnosed with CT-scan. Emergent replacement of the ascending aorta and the aortic arch using elephant trunk technique was performed; including incision of the membrane into the descending aorta. On day 3, liver enzymes increased and the general condition of the patient deteriorated rapidly. CT-scan revealed a partially thrombosed true lumen at the origin of the visceral arteries (Fig. 1A). The common hepatic artery showed reduced flow by duplex scan.

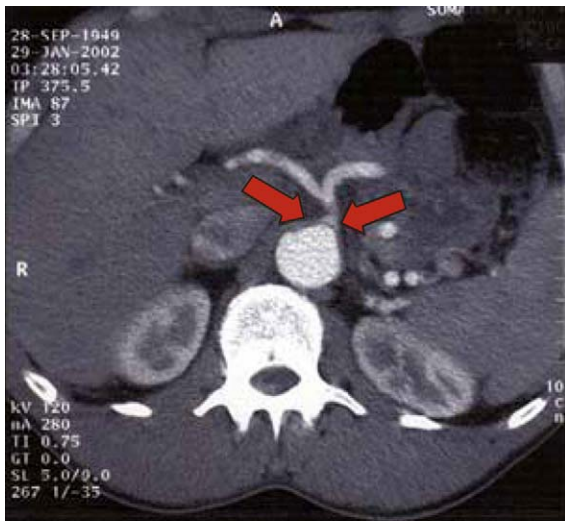Laparotomy was performed. The liver was swollen and bluish. The other abdominal organs were perfused. Systolic pressure in the common hepatic artery was 30 mmHg. Perfusion was re-established with a saphenous vein graft from the left limb of the graft. The bypass was tunneled in a retrocolic/gastric fashion to the common hepatic artery. Transit-time flow measurement (TTFM) demonstrated a flow >200 ml/min. The liver recovered within minutes. Further recovery was uneventful. Postoperative patency was demonstrated by MRI.

3. Case 2

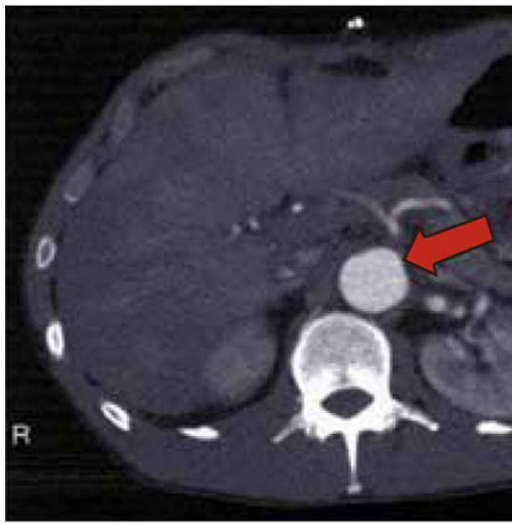A 53-year-old patient was admitted with severe abdominal pain and weak bilateral femoral pulses. CT-scan showed type B dissection with a narrowed true lumen at the origin of the visceral arteries (Fig. 1B). During initial assessment all signs of malperfusion disappeared. Standard medical treatment was begun.

Two days later, the patient complained of abdominal pain. Duplex scan showed reduced flow in the renal arteries and

* Corresponding author. Tel.: +41 31 632 23 75; fax: +41 31 632 44 43.
E-mail address: thierry.carrel@insel.ch (T.P. Carrel).



(A)



(B)

Fig. 1. (A) Narrowing of the true lumen at the origin of the celiac trunk (arrows). (B) Severe narrowing of the origin of the celiac trunk and thrombosed true lumen of the aorta (arrow).

superior mesenteric artery. Surgical fenestration was performed at renal level. The infrarenal aorta was transected and reconstructed with a Dacron graft to the common iliac arteries. The inferior mesenteric artery was reimplemented. Postoperative CT-scan showed normal contrasting in both kidneys and visceral arteries.

Seven days later the patient developed signs of septicemia. CT-scan revealed compression and partial thrombosis of the true lumen with occlusion of the superior mesenteric artery. Air entrapment and thickening of the colon wall raised suspicion of ischemia. Laparoscopy was performed and a profound malperfusion of the small intestine, liver, and colon was found. No pulsations were seen in the celiac trunk or superior mesenteric artery. Two saphenous vein grafts were connected to the left limb of the Dacron graft and anastomosed to the superior mesenteric artery and common hepatic artery (Fig. 2). TTFM showed a flow >250 ml/min for

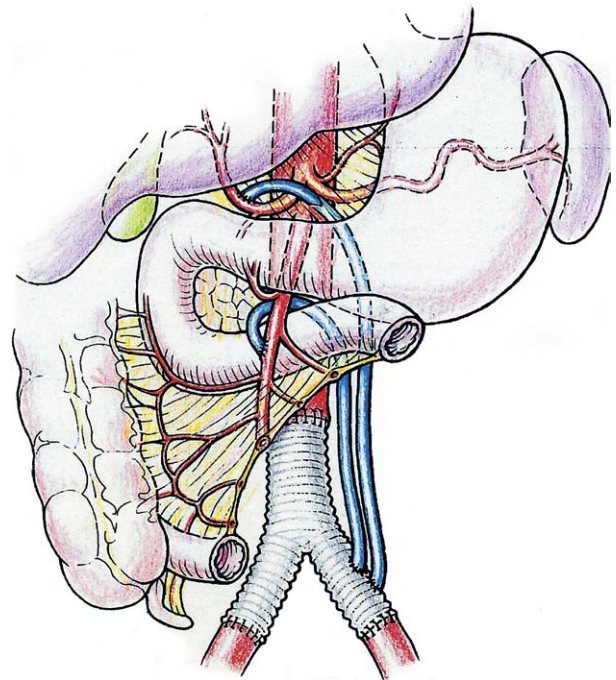


Fig. 2. Schematic drawing of the saphenous vein bypass grafts between the left limb of a bifurcated Dacron graft and the superior mesenteric and hepatic artery, respectively.

the hepatic and SMA, respectively. The organs recovered immediately. Delayed closure of the abdomen was performed.

Despite prolonged ICU-stay, the patient recovered well. Patency of the bypasses was confirmed by MRI four months postoperatively.

4. Discussion

Visceral and peripheral malperfusion have been reported in up to 30% of patients with acute aortic dissection [1,5,7]. Diagnosis and therapy of visceral malperfusion are still challenging. Adverse outcome is mainly related to delayed diagnosis and presence of irreversible intestinal ischemia at the time of surgical exploration. In case of still viable visceral organs, surgical options include fenestration [3], abdominal aortic tailoring [4], and direct revascularization.

Fenestration may equalize the pressure in both aortic channels and decreases the obstruction produced by the false lumen. Extension of the dissection into side branches is unlikely to be resolved by a limited fenestration. In selected cases with dynamic obstruction, this method has been demonstrated to produce long-term stability along the fenestrated aortic segment and excellent survival [1].

Abdominal aortic tailoring has been advocated as well [4]. It consists of an extraperitoneal approach with lateral aortotomy and an incision of the true and the false lumen. The intimal membrane is widely excised; if

entering the orifices, it is either tacked circumferentially or the vessel is endarterectomized using standard technique. Limited experience exists with this approach. The results seem similar to conventional fenestration. Limitations of this method include incomplete inspection of the visceral organs (extraperitoneal approach) and technical complexity.

Direct revascularization using a graft may offer some advantages. Transperitoneal approach allows full inspection of the abdominal organs and intestinal resection. All major aortic branches are accessible for inspection and flow measurement. The undissected iliac arteries or the bifurcated graft offer an inflow source. Direct revascularization is technically straightforward.

Recently, endovascular procedures which avoid anesthesia have emerged as an alternative treatment to surgery. The purpose of an endovascular intervention is the creation of entries large enough to achieve equalization of blood pressure in both aortic channels. The role of additional stenting of compromised aortic branches is controversial. The Stanford group reported their experience with 30 patients using the combined. In 18 patients with mesenteric ischemia, early and late mortality were 39% and 9%, respectively [5]. Intestinal resection was necessary in 28% (5 of 18 patients). Procedure-related complication rate was 22.5% and included stent misplacement (7.5%) and distal embolization (5%). Favorable outcome was strongly related to appropriate selection and the timing of the endovascular procedure [5]. While mortality has been reported to be 16% [7], serious complications may have been encountered in up to 30% [8–10].

In the era of endovascular techniques, surgical revascularization of the visceral arteries still represents a safe and straightforward alternative.

References

- [1] Lauterbach SR, Cambria RP, Brewster DC, Gertler JP, Lamuraglia GM, Isselbacher EM, Hilgenber AD, Moncure AC. Contemporary management of aortic branch compromise resulting from acute aortic dissection. *J Vasc Surg* 2001;33:1185–92.
- [2] Hagan PG, Nienaber CA, Isselbacher EM, Bruckman D, Karavite DJ, Russman PL, Evangelista A, Fattori R, Suzuki T, Oh JK, Moore AG, Malouf JF, Pape LA, Gaca C, Sechtem U, Lenferink S, Deutsch HJ, Diedrichs H, Marcos y Robles J, Llovet A, Gilon D, Das SK, Armstrong WF, Deeb GM, Eagle KA. The International Registry of Acute Aortic Dissection (IRAD): new insights into an old disease. *JAMA* 2000;283:897–903.
- [3] Panneton JM, Teh SH, Cherry Jr KJ, Hofer JM, Glociczki P, Andrews JC, Bower TC, Pairolero PC, Hallett Jr JW. Aortic fenestration for acute or chronic aortic dissection: an uncommon but effective procedure. *J Vasc Surg* 2000;32:711–21.
- [4] Webb TH, Williams GM. Abdominal aortic tailoring for renal, visceral and lower extremity malperfusion resulting from acute aortic dissection. *J Vasc Surg* 1997;26:474–80 [discussion 480–81].
- [5] Slonim SM, Miller DC, Mitchell RS, Semba CP, Razavi MK, Dake MD. Percutaneous balloon fenestration and stenting for life-threatening ischemic complications in patients with acute aortic dissection. *J Thorac Cardiovasc Surg* 1999;117:1118–26.
- [6] Dake MD, Kato N, Mitchell RS, Semba CP, Razavi MK, Shimono T, Hirano T, Takeda K, Yada I, Miller DC. Endovascular stent-graft placement for the treatment of acute aortic dissection. *N Engl J Med* 1999;340:1546–52.
- [7] Gysi J, Schaffner T, Mohacsi P, Aeschbacher B, Althaus U, Carrel TP. Early and late outcome of operated and non-operated acute dissection of the descending aorta. *Eur J Cardiothorac Surg* 1997;11:1163–9.
- [8] Kato N, Shimono T, Hirano T, Suzuki T, Ishida M, Sakuma H, Yada I, Takeda K. Midterm results of stent-graft repair of acute and chronic aortic dissection with descending tear: the complication-specific approach. *J Thorac Cardiovasc Surg* 2002;124:306–12.
- [9] Deeb GM, Williams DM, Bolling SF, Qunint LE, Monaghan H, Sievers J, Karavite D, Shea M. Surgical delay for acute type A dissection with malperfusion. *Ann Thorac Surg* 1997;64:1669–75.
- [10] Gaxotte V, Cochetoux B, Haulon S, Vincentelli A, Lions C, Koussa M, Willoteaux S, Asseman P, Prat A, Beregi JP. Relationship of intimal flap position to endovascular treatment of malperfusion syndromes in aortic dissection. *J Endovasc Ther* 2003;10(4):719–27.