

## CORRESPONDENCE

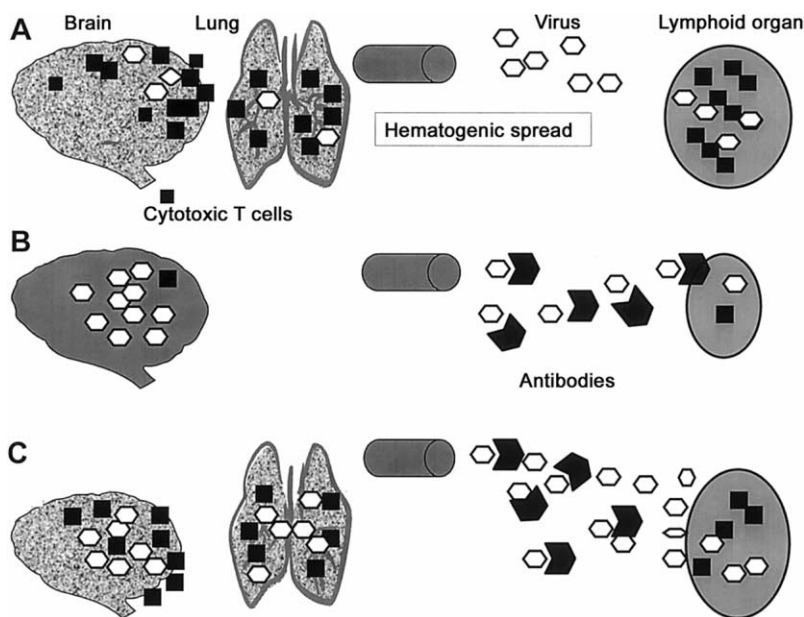
**Neutralizing Antiviral Antibodies Reduce Hematogenic Viral Spread but Not Antiviral Cytotoxic T Cell Induction and Subsequent Immunopathology**

**To the Editor**—In their article on treatment of respiratory syncytial virus (RSV) bronchiolitis and pneumonia in a cotton rat model, Prince et al. [1] observe that parenteral treatment with a monoclonal antibody (MAb) directed against the viral F protein resulted in the clearance of infectious virus but had only a small effect on the pulmonary pathology. Earlier studies demonstrated that immunoglobulin therapy for RSV infection, although safe, resulted in no clinically beneficial outcome [2, 3]. The article by Prince et al. is further evidence that the virus-host relationship is complex and is influenced by many factors, such as the virus, viral kinetics, viral genotypes, and host factors (e.g., cytokine responses, type and kinetics of cytotoxic and CD4<sup>+</sup> T cell responses, and major histocompatibility complex presentation) [4, 5].

Studies with the noncytotoxic lymphocytic choriomeningitis virus (LCMV) in mice produced several interesting findings that could explain, in part, phenomena observed for RSV infection,

in particular, data reported by Prince et al. [1]. Immunization with subunit vaccines may change the relative balance between virus spread and the immune response. This was observed in a study of the noncytotoxic LCMV, where immunization with a recombinant vaccinia virus expressing the LCMV glycoprotein, nucleoprotein, or the corresponding peptide protected mice from LCMV disease by induction of a protective cytotoxic T cell (CTL) response; however, identical immunization aggravated disease after infection with certain LCMV isolates via enhancement of T cell-mediated immunopathology [6, 7]. Similar influences on the immune balance may explain why a formalin-inactivated RSV vaccine not only failed to protect vaccine recipients in the late 1960s but also led to enhanced illness after natural exposure to the virus [8].

Of importance, the findings by Prince et al. [1] are strikingly similar to those found earlier for LCMV. Neutralizing anti-LCMV antibodies protected against hematogenic virus spread and prevented infection of the spleen or lymphoid cells but had little effect on viral infection of cells and spread between cells in solid peripheral tissues, such as the footpad or meninges (i.e., the initial site of infection) [9]. Neutralizing anti-LCMV antibodies regulated the balance between virus spread relative to



**Figure 1.** *A*, Slowly replicating lymphocytic choriomeningitis virus (LCMV; or, in analogy, respiratory syncytial virus [RSV]) spreads to lymphoid organs (e.g., spleen), inducing strong cytotoxic T cell (CTL) responses. CTL then cause severe immunopathologic disease in the brain (or lung for RSV). *B*, Antiviral antibodies prevent viral hematogenic spread of the slowly replicating LCMV isolate and, therefore, CTL induction almost completely. After this, no immunopathologic disease develops. However, because of subtotal lack of CTL, antiviral antibodies also inhibit fast virus elimination in the brain. *C*, Despite antiviral antibodies, faster replicating LCMV isolates (or possibly RSV) induce cellular immune responses and cause immunopathologic disease. In the latter (*C*), the time factor is crucial; although neutralizing antibodies reduce hematogenic spread, this is not sufficient to abrogate CTL induction and immunopathology completely. Moreover, because antigenic stimulation in lymphoid organs is reduced, efficient CTL responses occur only some days later, enabling more virus spread in primary organs, unfavorable CTL virus kinetics, and immunopathologic disease. *Hexagons*, viruses; *squares*, CTL; *shaded inverted hexagons*, antibodies.

the kinetics of the disease-causing CD8<sup>+</sup> T cell responses and thereby changed the outcome of immunopathologic disease.

When mice were intracerebrally challenged with a low dose of the slowly replicating LCMV Armstrong isolate, virus spread to the spleen and induced CTL responses, which then were directed against infected choriomeningeal cells, causing lethal immunopathology (figure 1A). Preexisting neutralizing antibodies efficiently prevented the hematogenic spread of this isolate and reduced the induction of CTL virtually completely and hence prevented immunopathology (figure 1B) [9]. After intracerebral or footpad infection with the faster replicating isolate LCMV-WE, preexisting antiviral antibodies again reduced the hematogenic spread and reduced CTL induction. However, neutralizing antibodies could not sufficiently control viral replication, and thereby CTL responses, to attenuate lethal choriomeningitis or an immunopathologic footpad swelling (i.e., disease at the sites of primary infection; figure 1C) [9, 10]. In accordance with these findings, the results of Prince et al. [1] could be explained as follows: after infection with RSV, treatment with MAbs directed against viral F protein resulted in a subtotal clearance of infectious virus. Remaining virus, despite the dramatic viral clearance, still was replicating sufficiently in the periphery to induce efficient (cellular) immune responses and to cause pulmonary disease (figure 1C).

The LCMV model may also explain why treatment with parenteral triamcinolone acetonide dramatically reduced the pathologic lesions of viral bronchiolitis and pneumonia but resulted in delayed clearance of the virus. Of interest, after infection with the slowly replicating LCMV Armstrong isolate, treatment with neutralizing antiviral antibodies not only drastically lowered primary CTL responses and immunopathologic disease but also delayed viral elimination (figure 1B); LCMV still was measurable at high titers in brains (i.e., at the site of infection). After infection with RSV, treatment with corticosteroids most likely reduced cellular immune responses, thereby preventing immunopathology and also clearance of the virus.

In our view, the LCMV model may help to elucidate the course of experimental RSV infection after parenteral treatment with MAbs. The data of Prince et al. [1] and of our study demonstrate that neutralizing antiviral antibodies and/or immunosuppression may drastically alter the kinetics of virus present in initially infected peripheral organs versus secondary lymphoid tissues yet may alter immune responses and result in modulated immunopathology. Thus, optimal vaccines and treatments should be efficient, both locally in tissues via activated T cells and systemically via soluble factors, including protective antibodies.

**Manuel Battegay,<sup>1</sup> Peter Seiler,<sup>2</sup> Lukas Hunziker,<sup>2</sup>  
Katja Wolf,<sup>1</sup> and Rolf M. Zinkernagel<sup>2</sup>**

<sup>1</sup>Outpatient Department of Internal Medicine, University Hospital Basel, Basel, and <sup>2</sup>Institute of Experimental Immunology, University of Zurich, Zurich, Switzerland

## References

1. Prince GA, Mathews A, Curtis SJ, Porter DD. Treatment of respiratory syncytial virus bronchiolitis and pneumonia in a cotton rat model with systemically administered monoclonal antibody (Palivizumab) and glucocorticosteroid. *J Infect Dis* **2000**;182:1326–30.
2. Rodriguez WJ, Gruber WC, Welliver RC, et al. Respiratory syncytial virus (RSV) immune globulin intravenous therapy for RSV lower respiratory tract infection in infants and young children at high risk for severe RSV infections: Respiratory Syncytial Virus Immune Globulin Study Group. *Pediatrics* **1997**;99:454–61.
3. Malley R, DeVincenzo J, Ramilo O, et al. Reduction of respiratory syncytial virus (RSV) in tracheal aspirates in intubated infants by use of humanized monoclonal antibody to RSV F protein. *J Infect Dis* **1998**;178:1555–61.
4. Zinkernagel RM. Immunology taught by viruses. *Science* **1996**;271:173–8.
5. Zinkernagel RM, Planz O, Ehl S, et al. General and specific immunosuppression caused by antiviral T-cell responses. *Immunol Rev* **1999**;168:305–15.
6. Oehen S, Hengartner H, Zinkernagel RM. Vaccination for disease. *Science* **1991**;251:195–8.
7. Battegay M, Oehen S, Schulz M, Hengartner H, Zinkernagel RM. Vaccination with a synthetic peptide modulates lymphocytic choriomeningitis virus-mediated immunopathology. *J Virol* **1992**;66:1199–201.
8. Kim HW, Canchola JG, Brandt CD, et al. Respiratory syncytial virus disease in infants despite prior administration of antigenic inactivated vaccine. *Am J Epidemiol* **1969**;89:422–34.
9. Battegay M, Kyburz D, Hengartner H, Zinkernagel RM. Enhancement of disease by neutralizing antiviral antibodies in the absence of primed antiviral cytotoxic T cells. *Eur J Immunol* **1993**;23:3236–41.
10. Seiler P, Kalinke U, Rulicke T, et al. Enhanced virus clearance by early inducible lymphocytic choriomeningitis virus-neutralizing antibodies in immunoglobulin-transgenic mice. *J Virol* **1998**;72:2253–8.

Financial support: Swiss National Science Foundation (grant 32-43'413.95).

Reprints or correspondence: Dr. Manuel Battegay, Outpatient Dept. of Internal Medicine, University Hospital Basel, Petersgraben 4, CH-4031 Basel, Switzerland (mbattegay@uhbs.ch).

**The Journal of Infectious Diseases** 2001;183:1425–6

© 2001 by the Infectious Diseases Society of America. All rights reserved.  
0022-1899/2001/18309-0019\$02.00

## Reply

**To the Editor**—We are pleased that Battegay et al. [1] support the basic finding of our paper [2], that therapy for certain viral diseases should target both the elimination of the infectious agent and the modulation of the host inflammatory response. Although we believe that the model of lymphocytic choriomeningitis virus (LCMV) in mice may provide valuable clues to the pathogenesis, prevention, and treatment of other infectious diseases, we think that it is important to comment on several of the observations by Battegay et al. that may not be direct parallels of the work we described.

First, our study used a single approach to respiratory syncytial virus (RSV) disease, passive immunotherapy using a monoclonal antibody. Thus, the observations of Battegay et al. [1] about active immunization, although of potential value in understanding vaccine-enhanced RSV disease, are of less relevance to the work we described. Second, their description of antibody studies in LCMV disease deals with passive immu-

noprophyllaxis of a systemic viral disease, whereas our study examined only passive immunotherapy for a self-limiting mucosal infection. Third, although their studies show that prophylactic antibody to LCMV may, under certain circumstances, enhance the disease process, our studies and those of several clinical trials showed no evidence that antibody therapy for RSV accentuated disease. Fourth, their hypothesis that our results could be explained by subtotal clearance of virus, with remaining virus then inducing the pathologic inflammatory response, does not take into account the fact that immunotherapy was not initiated until the peak of viral replication, by which time host inflammatory changes were already well under way.

Nonetheless, we are grateful for their supportive comments and are confident that they are reflective of a growing awareness of the role of host inflammation in infectious disease pathogenesis, with the attendant implications for therapy.

**Gregory A. Prince,<sup>1</sup> Amy Mathews,<sup>1</sup> Spencer J. Curtis,<sup>1</sup>  
and David D. Porter<sup>2</sup>**

<sup>1</sup>Virion Systems, Rockville, Maryland; <sup>2</sup>Department of Pathology and Laboratory Medicine, School of Medicine, University of California, Los Angeles

#### References

1. Battegay M, Seiler P, Hunziker L, Wolf K, Zinkernagel RM. Neutralizing antiviral antibodies reduce hematogenic viral spread but not antiviral cytotoxic T cell induction and subsequent immunopathology [letter]. *J Infect Dis* **2001**; 183:1425–6 (in this issue).
2. Prince GA, Mathews A, Curtis SJ, Porter DD. Treatment of respiratory syncytial virus bronchiolitis and pneumonia in a cotton rat model with systemically administered monoclonal antibody (Palivizumab) and glucocorticosteroid. *J Infect Dis* **2000**; 182:1326–30.

Reprints or correspondence: Dr. Gregory A. Prince, Virion Systems, 9610 Medical Center Dr., Ste. 100, Rockville, MD 20850 (gprince@erols.com).

**The Journal of Infectious Diseases** 2001;183:1426–7

© 2001 by the Infectious Diseases Society of America. All rights reserved. 0022-1899/2001/18309-0020\$02.00

### Timing of Human Immunodeficiency Virus Type 1 and Human Herpesvirus 8 Infections and Length of the Kaposi's Sarcoma-Free Period in Coinfected Persons

**To the Editor**—In 1998, we reported that human immunodeficiency virus type 1 (HIV-1)-infected homosexual men have the highest risk of developing Kaposi's sarcoma (KS) if they acquire human herpesvirus 8 (HHV-8) after HIV infection [1]. This observation has been confirmed recently by Jacobson et al. [2], who also found that the duration of HIV-1 infection before HHV-8 acquisition influences the risk for KS. Therefore, we [1] and Jacobson et al. [2] suggested that immunodeficiency at the time of primary HHV-8 infection may shorten the KS-free period.

In a subsequent correspondence, Rezza [3] suggested that this is not necessarily the case, since most cases of transplant-associated KS in an HHV-8-endemic country occurred in patients who had acquired HHV-8 before transplantation [4]. Rezza infers from these data that factors like HIV-1 Tat and/or inflammatory cytokines, rather than immunosuppression, might be responsible for the increased incidence of KS in HIV-1 and HHV-8 coinfecting persons.

Jacobson and Jenkins [5] responded to the report by Rezza [3] by suggesting that KS in HIV-1-negative transplant recipients cannot be formally compared with KS in HIV-1-positive individuals in regard to the impact of immunosuppression on the rate of progression of HHV-8 infection to KS. We agree with the comments of Jacobson and Jenkins and wish to point out that, in our original report [1], CD4 cell count, not HIV-1 virus load, was an independent risk factor for KS. In our view, it is therefore more likely that HIV-related immunodeficiency, rather than steady-state levels of HIV in blood, and, by inference, levels of HIV-1 Tat or inflammatory cytokines increase the risk for KS.

**Neil Renwick,<sup>1</sup> Gerrit Jan Weverling,<sup>2</sup> Thomas Schulz,<sup>3</sup>  
and Jaap Goudsmit<sup>1</sup>**

<sup>1</sup>Departments of Human Retrovirology and of Clinical Epidemiology and Biostatistics, Academic Medical Center, University of Amsterdam, Amsterdam, The Netherlands; <sup>2</sup>Department of Virology, Medizinische Hochschule Hannover, Hannover, Germany

#### References

1. Renwick N, Halaby T, Weverling GJ, et al. Seroconversion for human herpesvirus 8 is highly predictive of Kaposi's sarcoma. *AIDS* **1998**; 12:2481–8.
2. Jacobson LP, Jenkins FJ, Springer G, et al. Interaction of human immunodeficiency virus type 1 and human herpesvirus type 8 infections on the incidence of Kaposi's sarcoma. *J Infect Dis* **2000**; 181:1940–9.
3. Rezza G. Immunosuppression, timing of human herpesvirus 8 infection, and risk of Kaposi's sarcoma among human immunodeficiency virus type 1-infected persons and transplant recipients [letter]. *J Infect Dis* **2000**; 182:1809.
4. Parravacini C, Olsen SJ, Capra M, et al. Risk of Kaposi's sarcoma-associated herpes virus transmission from donor allograft among Italian posttransplant Kaposi's sarcoma patients. *Blood* **1997**; 90:2826–9.
5. Jacobson LP, Jenkins FJ. Reply. *J Infect Dis* **2000**; 182:1809–10.

Reprints or correspondence: Prof. J. Goudsmit, Dept. of Human Retrovirology, Academic Medical Center, University of Amsterdam, Meibergdreef 15, Amsterdam 1105AZ, The Netherlands (j.goudsmit@amc.uva.nl).

**The Journal of Infectious Diseases** 2001;183:1427

© 2001 by the Infectious Diseases Society of America. All rights reserved. 0022-1899/2001/18309-0021\$02.00

### No Increase in Liver Decompensation Risk with Atypical Hepatitis C Virus Antibody Pattern

**To the Editor**—Goedert et al. [1] found a surprising correlation between high anti-hepatitis C virus (HCV) c100 and low anti-c22 reactivity in RIBA and liver decompensation during an average of 3 years of follow-up of patients with hemophilia coinfecting with HCV and human immunodeficiency virus (HIV). They outlined the need of corroboration of such findings in both HCV-HIV-coinfecting subjects and persons infected only with HCV.

We retrospectively examined the results of anti-HCV antibody determination in Western blot testing (Murex Diagnostics) of 241 HCV-infected (HCV-RNA positive) patients (6 HIV-coinfecting [none with hemophilia]) followed up in our outpatient clinic and correlated these findings with eventual decompensation during a mean follow-up of 3 years.

Of the 241 patients, only 5 (1 of whom was coinfecting with HIV) had, when first tested, high levels of anti-NS4 antibodies (++++, Western blot) and low levels of anti-core antibodies (+, Western blot). None of the 5 had any episode of decompensation during follow-up, whereas 5 other patients (1 HIV-positive patient) developed ascites and/or hepatic encephalopathy. Because the c100 and c22 peptides used in RIBA overlap NS4 and core, respectively, in Western blot, our results, although confirming that low anti-core reactivity in the face of high anti-NS4 levels is atypical, do not show any correlation of this pattern with impending liver decompensation. Although our findings are in a nonhemophilic, largely non-HIV-infected cohort, they show that high anti-NS4 (c100) and low anti-core (c22) antibody levels cannot be regarded as potential surrogate markers of progressive liver disease in all HCV-infected persons.

**Maria Serena Longhi, Francesca Cainelli,  
Ercole Concia, and Sandro Vento**

*Department of Infectious Diseases, University of Verona, Verona, Italy*

#### References

1. Goedert JJ, Hatzakis A, Maloney EM, Eyster ME. Increased liver decompensation risk with atypical hepatitis C virus antibody levels. *J Infect Dis* 2000; 182:590–4.

Reprints or correspondence: Dr. Sandro Vento, University of Verona, Dept. of Infectious Diseases, “Borgo Trento” Hospital, Piazzale Stefani 1, 37125 Verona, Italy (vento@borgotrento.univr.it).

**The Journal of Infectious Diseases** 2001;183:1428

© 2001 by the Infectious Diseases Society of America. All rights reserved.  
0022-1899/2001/18309-0022\$02.00

### A Pathologist's View of Organisms and Human Atherosclerosis

**To the Editor**—Several different organisms have been associated with ischemic heart disease. Reports of remnants or viable organisms in human atherosclerotic lesions have led to the suggestion that the lesions could, in part, be due to various infectious agents, either separately or in combination.

The antibody status of some organisms has been studied in patients with ischemic heart disease and has been compared with findings in persons free of symptoms. These studies examined antibodies to *Chlamydia pneumoniae*, cytomegalovirus, *Helicobacter pylori*, dental bacteria, and hepatitis A virus [1]. The rationale for selecting the specific antibodies for study in this group of patients is not clear. If one were to study the antibody status of every pathogen in humans, it would seem reasonable to expect that a certain percentage of organisms would be more common in patients with ischemic heart disease and that a certain percentage would be less common in such a group.

What is the status of bacterial infections, viruses, and fungal and parasitic infections in patients with ischemic heart disease? Can we conclude that organisms that are more frequent in patients with cardiac ischemia have a role in ischemia and that those that are decreased somehow protect against ischemia of the heart muscle? The association with atherosclerosis of the arteries in this group is tenuous, in that ischemia of the heart cannot be equated with and is not an indication of the severity of atherosclerosis [2].

Atherosclerosis is an arterial disease mainly of the aorta and larger arteries. The coronary arteries are but a small part of atherosclerosis and hardly indicate the extent of the lesion. It is not correct to assume that the clinical symptom of ischemia of the cardiac muscle is solely due to atherosclerosis or that it is an indication of the extent and severity of atherosclerotic disease in the arterial vasculature [2].

Another group of studies has been concerned with the molecular detection of microorganisms in atherosclerotic lesions. In the 1980s, various herpesvirus remnants were found in atherosclerotic lesions in the aorta and normal aortic tissue. Recently, it was reported that DNA of *H. pylori* [3] and certain dental bacteria [4] are present in atherosclerotic lesions. The finding of polymerase chain reaction-positive material has not always been consistent, and there have been calls to standardize these methods. It seems improbable that pathologists examining these lesions could overlook such large organisms. The implications of finding DNA remnants in these lesions have not been fully addressed. Whether the DNA is in the intima (where atherosclerosis occurs) or in the media or adventitia is not clear. Is the DNA present in blood? Blood is invariably present in the specimen that is examined (arteries not only are in contact with blood but are supplied by vasovasorum that contain blood). From a practical point of view, atherosclerotic arterial

lesions with features akin to those of herpesviruses, hepatitis A virus, *H. pylori*, or dental bacteria are not seen. Pathologically, it is difficult to accept that a lesion with such specific constant features can be caused by a variety of different viruses and bacteria.

*C. pneumoniae* is associated with atherosclerosis in a different way. The human atherosclerotic lesion is considered to be lipid related. Initial electron microscopy studies in the 1960s examined the nature of lipid in human atherosclerotic lesions and revealed that most lipid structures were in different forms [5]. Small double membrane-bound structures were called vesicles, others were called small lipid droplets, some were called dense bodies, and others were called "unknown structures." Larger forms were called dense reticular membrane-bound lipid. Vacuoles also were described. These contained dense lipid bodies. At more or less the same time, electron microscopy studies of cultured *Chlamydia* organisms illustrated structures that were identical to those described and illustrated in the studies of human atherosclerosis [6]. These consisted of smaller elementary forms and larger reticulate organisms growing in vacuoles. The pathologists were unaware of the features of *Chlamydia* organisms, and the chlamydiologists were unaware of the features of lipid structures in human atherosclerotic lesions. In the 1990s, the question of identification of these structures was addressed [7–9]. The current evidence, which is accumulating, suggests that these structures may well be *C. pneumoniae*. The implications are that previously overlooked or misinterpreted major inherent components may consist largely of chlamydiae and not fat, as accepted. From a pathologic point of view, not only are *Chlamydia*-like structures present in human atherosclerotic lesions, but a reassessment of the lesion in light of the new findings shows that most of these lesions have specific constant pathologic features, which are consistent with those

of a chronic chlamydial granuloma or chlamydioma of the arteries [10].

**Allan Shor**

*National Centre for Occupational Health, Johannesburg, South Africa*

#### References

1. Zhu J, Quyyumi AA, Norman JE, et al. The possible role of hepatitis A virus in the pathogenesis of atherosclerosis. *J Infect Dis* **2000**; 182:1583–7.
2. Willerson JT, Hills LD, Winniford M, et al. Speculation regarding mechanism responsible for ischaemic heart disease syndromes. *J Am Coll Cardiol* **1986**; 8: 245–50.
3. Farsak B, Yildirim A, Akyon Y, et al. Detection of *Chlamydia pneumoniae* and *Helicobacter pylori* DNA in human atherosclerotic plaques by PCR. *J Clin Microbiol* **2000**; 38:4408–11.
4. Haraszthy VI, Zambon JJ, Trevisan M, et al. Identification of periodontal pathogens in atheromatous plaques. *J Periodontol* **2000**; 71:1554–60.
5. Geer JC, McGill Jr HC, Strong JP. The fine structure of human atherosclerotic lesions. *Am J Pathol* **1961**; 38:263–87.
6. Armstrong JA, Valentine RC, Fildes C. Structure and function of the trachoma agent in cell cultures as shown by electronmicroscopy. *J Gen Microbiol* **1963**; 30:359–73.
7. Shor A, Kuo CC, Patton DL. Detection of *Chlamydia pneumoniae* in coronary arterial fatty streaks and atheromatous plaques. *S Afr Med J* **1992**; 82: 158–61.
8. Kuo CC, Shor A, Campbell LA, et al. Demonstration of *Chlamydia pneumoniae* in atherosclerotic lesions of coronary arteries. *J Infect Dis* **1993**; 167:841–9.
9. Shor A, Phillips JI. *Chlamydia pneumoniae* and atherosclerosis. *JAMA* **1999**; 282:2071–3.
10. Shor A, Phillips J. Histological and ultrastructural findings suggesting an initiating role for *Chlamydia pneumoniae* in the pathogenesis of atherosclerosis: a study of fifty cases. *Cardiovasc J S Afr* **2000**; 11:16–23.

Reprints or correspondence: Dr. Allan Shor, National Centre for Occupational Health and University of the Witwatersrand, PO Box 4788, Johannesburg 2000, South Africa (shora@health.gov.za).

**The Journal of Infectious Diseases** 2001;183:1428–9

© 2001 by the Infectious Diseases Society of America. All rights reserved.  
0022-1899/2001/18309-0023\$02.00