

Decisional role of the dorsolateral prefrontal cortex in ocular motor behaviour

C. Pierrot-Deseilligny,¹ R. M. Müri,² C. J. Ploner,³ B. Gaymard,¹ S. Demeret¹ and S. Rivaud-Pechoux¹

¹INSERM 289 and Service de Neurologie 1, Hôpital de la Salpêtrière, Assistance Publique-Hôpitaux de Paris, Paris, France, ²Eye Movement Research Laboratory and Department of Neurology, Inselspital, Bern, Switzerland and ³Klinik für Neurologie, Charité, Berlin, Germany

Correspondence to: Professor Ch. Pierrot-Deseilligny, Service de Neurologie 1, Hôpital de la Salpêtrière, 47 Bd de l'Hôpital, 75651 Paris cedex 13, France
E-mail: cp.deseilligny@psl.ap-hop-paris.fr

Summary

Three patients with a unilateral cortical lesion affecting the dorsolateral prefrontal cortex (DLPFC), i.e. Brodmann area 46, were tested using different paradigms of reflexive saccades (gap and overlap tasks), intentional saccades (antisaccades, memory-guided and predictive saccades) and smooth pursuit movements. Visually guided saccades with gap and overlap, latency of correct antisaccades and memory-guided saccades and the gain of smooth pursuit were normal, compared with controls. These results confirm our anatomical data showing that the adjacent frontal eye field (FEF) was unimpaired in these patients. The specific pattern of abnormalities after a unilateral DLPFC lesion, compared with that of the FEF lesions previously reported,

consists mainly of: (i) a bilateral increase in the percentage of errors in the antisaccade task (misdirected reflexive saccades); (ii) a bilateral increase in the variable error in amplitude, without significant decrease in the gain, in the memory-guided saccade task; and (iii) a bilateral decrease in the percentage of anticipatory saccades in the predictive task. Taken together, these results suggest that the DLPFC plays a crucial role in the decisional processes, preparing saccades by inhibiting unwanted reflexive saccades (inhibition), maintaining memorized information for ongoing intentional saccades (short-term spatial memory) or facilitating anticipatory saccades (prediction), depending upon current external environmental and internal circumstances.

Keywords: antisaccades; prediction; prefrontal cortex; saccades; spatial memory

Abbreviations: ACC = anterior cingulate cortex; DLPFC = dorsolateral prefrontal cortex; FEF = frontal eye field; fMRI = functional MRI; MGS = memory-guided saccade; PEF parietal eye field; PPC = posterior parietal cortex; SEF = supplementary eye field

Introduction

The prefrontal cortex is essential in effective and skilfully organized behaviour. One fundamental principle of the prefrontal cortex may be adaptive neural coding, since many neurons in this cortical region adapt their properties specifically to carry information, producing a dense, distributed representation of related inputs, actions, rewards and other information (for a review see Duncan, 2001). Another principle of prefrontal function is to guide or inhibit future responses that require temporal integration of events for purposeful actions. Constantinidis *et al.* (2002) recently showed, using simultaneous recordings in the monkey dorsolateral prefrontal cortex (DLPFC), inhibitory interactions between prefrontal neurons active at different time intervals. They proposed that the inhibitory function of the prefrontal cortex plays an important role in controlling the

timing of neuronal activity and shaping the temporal flow of information processing.

In humans, the role of the DLPFC in eye movement control, i.e. Brodmann area 46 (Rajkowska and Goldman-Rakic, 1995), is not yet fully understood. One reason may be the problem of finding patients with isolated lesions of this region. As shown by functional imaging, the DLPFC and the frontal eye field (FEF) in humans lie close together. Consequently, lesions often involve both regions, rendering any inferences as to their respective functions equivocal. Indeed, although eye movement studies with lesions including prefrontal structures have existed since the 1980s (Guitton *et al.*, 1985; Pierrot-Deseilligny *et al.*, 1991b; Braun *et al.*, 1992), a study testing different aspects of eye movement control in patients with lesions restricted to the DLPFC has

been lacking. Several years ago, we tested a battery of eye movement paradigms in patients with cortical lesions restricted to the FEF, showing that a distinct pattern of eye movement disorders can be attributed to FEF lesions (Rivaud *et al.*, 1994; Gaymard *et al.*, 1999; Ploner *et al.*, 1999). We report the first study of patients with selective lesions of the DLPFC tested using a battery of eye movement paradigms. A specific pattern of eye movement disturbances was found, which was clearly distinct from the ocular motor deficits previously reported with FEF lesions. A unifying hypothesis on the role of the DLPFC in saccade preparation is proposed.

Patients and methods

Patients

Three right-handed patients, two females and one male, were examined. Their mean age was 53 years (range: 34–73 years). The lesions were vascular ischaemic and remained mainly cortical, not involving the subcortical regions such as the basal ganglia and the internal capsule. Two patients had a left-sided lesion and one patient a right-sided lesion, documented by CT or MRI scan (Fig. 1). For reconstruction of the patient's lesions, we used four brain sections: +60 mm, +50 mm, +28 mm and +12 mm parallel above the anterior commissure–posterior commissure line taken from the atlas of Talairach and Tournoux (1988). The +50 mm section was chosen to show the FEF in the precentral gyrus as defined by recent functional imaging studies (Paus, 1996; Heide *et al.*, 2001). The +28 mm section was chosen to show the invariable portion of Brodmann's area 46 in the DLPFC in the middle portion of the middle frontal gyrus as defined by cytoarchitectonic criteria (Rajkowska and Goldman-Rakic, 1995). This region also shows activation during functional imaging of normal subjects performing memory-guided saccades (O'Sullivan *et al.*, 1995; Sweeney *et al.*, 1996). The other two sections (+60 mm and +12 mm) were chosen to show the extension of the lesions above and below both critical eye movement areas. The DLPFC was damaged, but the FEF was spared by the lesions in all three cases. The parietal eye field (PEF) and supplementary eye field (SEF), located at a distance from the DLPFC region, were also spared (see Discussion).

All patients were examined within the first month after the vascular accident. None of them was taking medications acting upon on the CNS. Patient 1 (age: 57 years) had a cephalalgia as the initial and unique symptom. Clinical examination was normal. On MRI, an ischaemic lesion affecting a small part of the left prefrontal region was found (Fig. 1). The remainder of the CNS was normal. After investigations, it was stated that this lesion was due to a venous thrombosis. Patient 2 (age: 34 years) had slight aphasia (difficulty in finding some words) as the initial and unique sign. The clinical examination was otherwise normal. On MRI, an ischaemic and isolated lesion of the left prefrontal region was found (Fig. 1), probably secondary to

a stenosis of the left carotid artery. Patient 3 (age: 73 years) had a slight left central facial paresis as the initial and unique clinical sign. In particular, there was no deficit in the limbs. On CT scan, there was a probable infarction of the right prefrontal region, extending, at the lower levels of the frontal lobe, into the motor area of the face (Fig. 1). No other lesions were visible. After investigations, no definite cause was found. A control group of 15 healthy subjects (mean age: 51 years; range: 36–63 years) was also examined. The subjects of both groups gave their informed consent, and the local ethics committee (Pitié-Salpêtrière) approved the study.

Methods

Eye movements were recorded by means of direct current electro-oculography in complete darkness, using four Ag–AgCl electrodes (two horizontal temporal and two vertical on one eye to control blinks). The subject's head was immobilized. The electrical signal was amplified and filtered (bandwidth: 0–100 Hz), and the spatial resolution was 0.5°. Visual cues were presented at a distance of 95 cm with red LEDs embedded in a curved ramp. LEDs were 0.15° and 5 cd/m² in luminance. Each session was preceded by 10 min of dark adaptation. The velocity threshold criterion for definition of saccades was 30°/s. Data were sampled with a frequency of 200 Hz. System calibration was performed before each paradigm. For further details, see Pierrot-Deseilligny *et al.* (1991b). The whole examination lasted ~45 min. The following paradigms were tested.

Gap task

In the gap task, reflexive visually guided saccades were tested (Fig. 2A). The central fixation point was switched off 200 ms (i.e. gap) before the onset of a lateral target, located 25° to the right or the left of the central fixation point. The subjects were instructed to fixate the central fixation point, and to look at the lateral target as soon as it appeared. The target was presented randomly to the right or left, with unpredictable timing. Left and right saccade latencies were calculated for each subject by averaging 20 measurements in each direction. The percentage of express saccades, with latency comprised between 80 and 120 ms (Fischer and Ramsperger, 1984), was also determined. Lastly, the saccade gain (amplitude of the first saccade over eccentricity of the target) was measured.

Antisaccade task

In the antisaccade task, the visual presentation was the same as in the gap task, except that the subject was instructed to look in the opposite direction to that of the suddenly appearing lateral target, without first looking at the target (Fig. 2B). Twenty trials were made in each lateral direction. The percentage of errors (misdirected saccades, i.e. reaching or simply initially directed towards the target), the latency of these misdirected saccades and the latency of correct

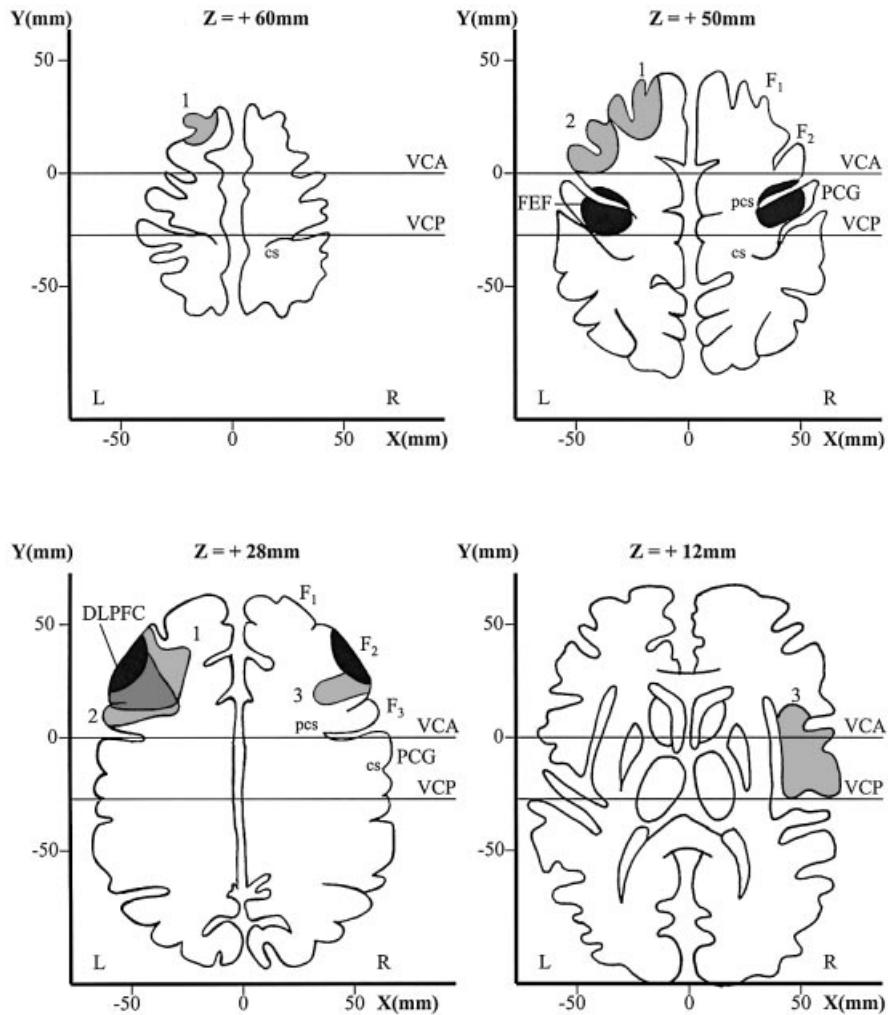


Fig. 1 Lesions of the three patients. Four transverse brain sections parallel above the anterior commissure–posterior commissure (AC–PC) line with the Talairach coordinate frame (Talairach and Tournoux, 1988) show the location of the frontal eye field (top, right), in the precentral gyrus and sulcus, and the invariable portion of Brodmann’s area 46 in the dorsolateral prefrontal cortex (DLPFC; bottom, left), at the level of the middle frontal gyrus (F_2), as black areas. Lesions of the patients are in grey (1, 2 and 3). Note that in all three patients, the lesions damaged the DLPFC but spared the FEF. cs = central sulcus; DLPFC = dorsolateral prefrontal cortex; F_1 , F_2 and F_3 = superior, middle and inferior frontal gyrus, respectively; FEF = frontal eye field; L = left; PCG = precentral gyrus; pcs = precentral sulcus; R = right; VCA = vertical anterior commissure line; VCP = vertical posterior commissure line; x, y and z, distance from the saggital plane, the coronal plane (through the anterior commissure) and the AC–PC line, respectively.

antisaccades (made in the direction opposite to the target) were determined for each direction. Furthermore, the percentage of express saccades (with latency comprised between 80 and 120 ms) among the misdirected saccades was also calculated in patients. In controls, this percentage could not be determined since the number of misdirected saccades was too small.

Overlap task

In the overlap task, the central fixation point remained switched on during the presentation of the lateral visual target

(Fig. 2C). All other conditions and measurements were the same as for the gap task.

Memory-guided saccade task

In the memory-guided saccade (MGS) task, the subject fixated a central fixation point while the lateral target was flashed for 50 ms, with unpredictable direction and eccentricity (between 10 and 30°; Fig. 2D). The central fixation point was switched off 3 s after the flashed target, which was the go signal for the subject to make a saccade to the remembered position of the flash. Then, the lateral target was switched on and the subject made a corrective saccade if necessary.

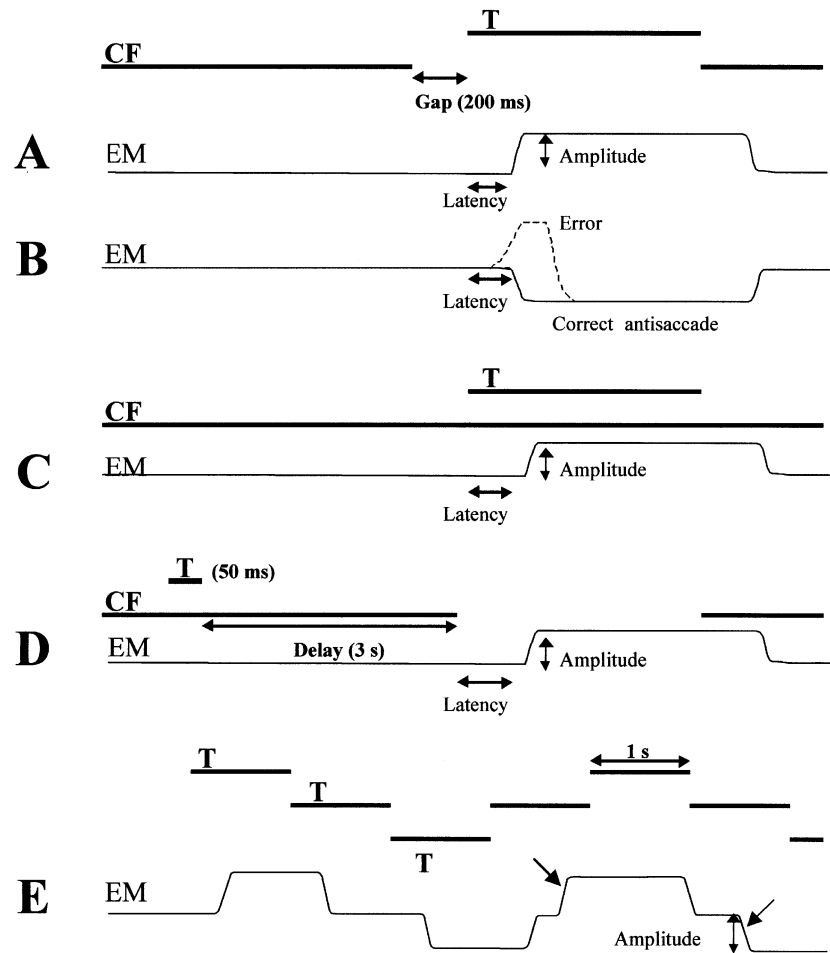


Fig. 2 Saccade paradigms. (A) Visually guided saccade with gap: latency and amplitude are measured. (B) Antisaccade, with the same stimulation as in A but with the instruction to look in the opposite direction to the target: latency of correct antisaccades and the percentage of errors (misdirected reflexive saccades) are measured. (C) Visually guided saccade with overlap, with the same instruction as in A but with the central fixation (CF) remaining switched on: latency and amplitude are measured. (D) Memory-guided saccade, with the go signal given by the extinction of the CF (after a delay of 3 s): latency and amplitude are measured. (E) Predictive saccades, with the instruction to follow the targets: the amplitude and the percentage of anticipatory saccades (oblique arrows) are measured. EM = eye movement; T = target.

Saccade latency and gain were averaged from 20 saccades in each lateral direction. Furthermore, interquartile ranges were used to describe a subject's gain variability (variable error in amplitude). For the amplitude analysis, we studied the first saccade made after the central fixation point was switched off (Pierrot-Deseilligny *et al.*, 1991b). Additional saccades just after the initial saccades were rare and did not influence MGS errors. The data on final eye positions were therefore similar to those of initial saccades and are not presented, so as to avoid redundancy.

Predictive saccade task

The subject was instructed to follow a luminous target which appeared 25° to the right, then was displaced to the centre,

25° to the left, back to the centre and finally to the original position (Fig. 2E). The target remained in each position for 1 s. Therefore, target direction, amplitude and timing were entirely predictable in this paradigm. Six such consecutive cycles were repeated three times. A saccade was considered as anticipatory, i.e. not visually guided, when latency was <70 ms (Smit and Van Gisbergen, 1989) or if it occurred even before target onset. The percentage of centrifugal anticipatory saccades was calculated from 18 saccades in each direction. The first saccade was excluded from analysis. The gain of centrifugal anticipatory saccades was also determined. The centripetal saccades, which are very different in nature from centrifugal saccades in terms of both triggering and amplitude (Findlay, 1981), were not studied.

Smooth pursuit task

In the smooth pursuit task, the subject was instructed to follow a horizontal target moving sinusoidally with peak velocities of 23°/s (0.25 Hz). The mean rightward and leftward gains (peak eye velocity over peak target velocity) were calculated from 10 consecutive cycles.

Statistical analysis

Since lesions were both left- and right-sided, we grouped the results of the patients into ipsilateral and contralateral results. In the control group, the results for rightward and leftward saccades were analysed statistically. There was no significant side difference (Mann–Whitney test) in any performance. Therefore, the left and right data were pooled for each subject.

Statistical analysis was performed using a non-parametric test (Kruskal–Wallis test) for percentages, comparing control, ipsilateral and contralateral performance. When results were statistically significant, we compared control performance with ipsilateral or contralateral performance, respectively, using Mann–Whitney test. For latency and the amplitude gain, a parametric test was used (Student's *t* test).

Results

The results of the gain in the gap, overlap and smooth pursuit tasks for controls and patients are presented in Table 1. Results were similar in both groups, with no statistically significant difference for the gain values in any of the three paradigms. Furthermore, smaller standard errors in the patient group than in controls indicate that the results in the latter were particularly homogeneous.

Table 2 shows latency values in the gap and overlap tasks. There was no statistically significant difference between the two groups, with, however, a greater variability in the patient group, as indicated by their standard errors.

The median percentage of express saccades (comprised between 80 and 120 ms) in the gap task was 8% in controls (range: 0–27%), and 42% (range: 35–48%; $P < 0.01$, Mann–Whitney test) for ipsilateral saccades and 16% (range: 6–27%; NS) for contralateral saccades in patients. This increase in the percentage of ipsilateral express saccades obviously is related to the slight decrease observed in the latency of ipsilateral saccades made in the gap task (160 ms versus 187 ms in controls, $P = 0.12$). These results were similar in the three patients, including the patient with a right-sided lesion. There is no obvious explanation for this increase in the percentage of ipsilateral express saccades or for the tendency for a decrease in ipsilateral saccade latency in the gap task.

The percentage of errors in the antisaccade task (Fig. 3, left side) was significantly increased in the patient group: the median was 86% (range: 28–100%) for ipsilateral saccades ($P = 0.002$, Mann–Whitney test) and 85% (range: 28–92%)

Table 1. Gain of the gap, overlap and smooth pursuit tasks

Gain (mean, SE)	Controls	Ipsilateral	Contralateral	<i>P</i>
Gap	0.92 (0.04)	0.92 (0.02)	0.91 (0.01)	NS
Overlap	0.94 (0.04)	0.92 (0.02)	0.96 (0.02)	NS
Smooth pursuit	0.92 (0.05)	0.95 (0.03)	0.90 (0.01)	NS

NS = not significant.

Table 2. Latency of the gap and overlap tasks

Latency (mean, SE)	Controls	Ipsilateral	Contralateral	<i>P</i>
Gap	187 (9)	160 (7)	179 (13)	NS
Overlap	257 (8)	251 (12)	281 (30)	NS

NS = not significant.

for contralateral saccades ($P = 0.002$, Mann–Whitney test), respectively. In the control group, the median percentage of errors was 8% (range: 0–17%). The latency of the few correct antisaccades (made in the opposite direction to the target) was normal (Fig. 3, right side): 270 ms (SE = 22) for ipsilateral saccades and 260 ms (SE = 22) for contralateral saccades in patients versus 280 ms (SE = 9) in controls (NS, Student's *t* test). The number of errors (misdirected saccades made towards the target) in controls was too small to be used for statistical purposes in the study of latency. However, the latency of these reflexive misdirected saccades in patients was significantly shorter than that of correct antisaccades: 223 ms (SE = 15) for ipsilateral saccades ($P < 0.01$, Student's *t* test) and 203 ms (SE = 11) for contralateral saccades ($P < 0.01$), but not as short as that observed in the gap task. Furthermore, the percentage of express saccades among these reflexive misdirected saccades was less than in the gap task ipsilaterally (median: 10%; range: 5–42%) and slightly higher contralaterally (median: 18%; range: 13–33%), therefore, without the same asymmetry as in the gap task.

For MGS, there was a bilateral, slight, not significant increase in latency [Fig. 4, left; mean: 381 ms (SE = 10) for ipsilateral saccades with $P = 0.001$, and 347 ms (SE = 5) for contralateral saccades with $P = 0.001$] in the patient group, compared with controls (mean: 321 ms, SE = 13). In the MGS task, the subjects may make a saccade to the target just after the flash, i.e. a visually triggered saccade. Such trials were excluded from the analysis of MGS. However, it could be of interest to determine the percentage of such saccadic errors since they are a reflection of the control of reflexive saccade suppression. In controls, there were 4.5% (median; range: 0–12%) of such saccades, but in patients the percentage was 42% (range: 23–53%) for ipsilateral saccades ($P < 0.01$, Mann–Whitney test) and 39% (range: 8–57%) for contralateral saccades ($P < 0.01$). Therefore, saccade suppression during the MGS task was much less efficient in these patients with a prefrontal dysfunction than in controls.

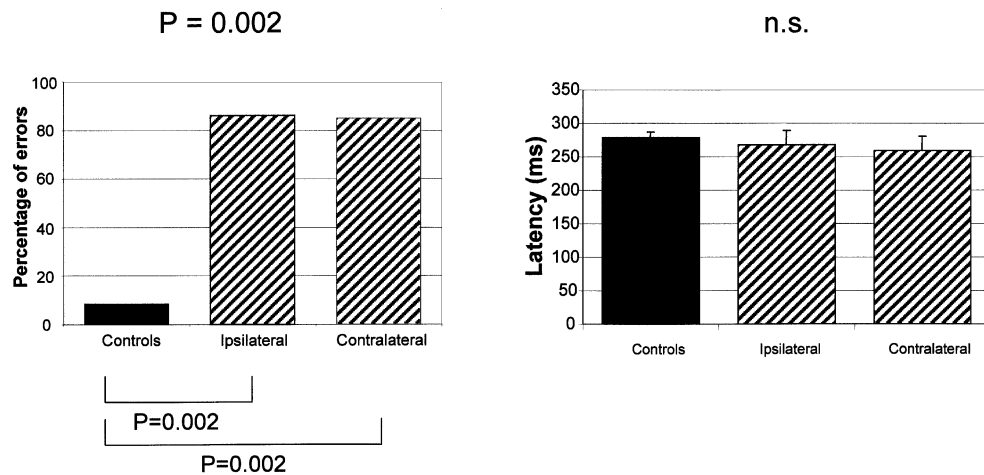


Fig. 3 Antisaccade task. On the left side, median percentage of errors (misdirected reflexive saccades made towards the target), and, on the right side, latency of correct antisaccades (made in the opposite direction to the target) (bars indicate +1 SE). Note that the percentage of errors of patients was increased bilaterally, compared with that of controls, whereas the latency of correct antisaccades was similar to that of controls. Top, Kruskal–Wallis test; bottom, Mann–Whitney test.

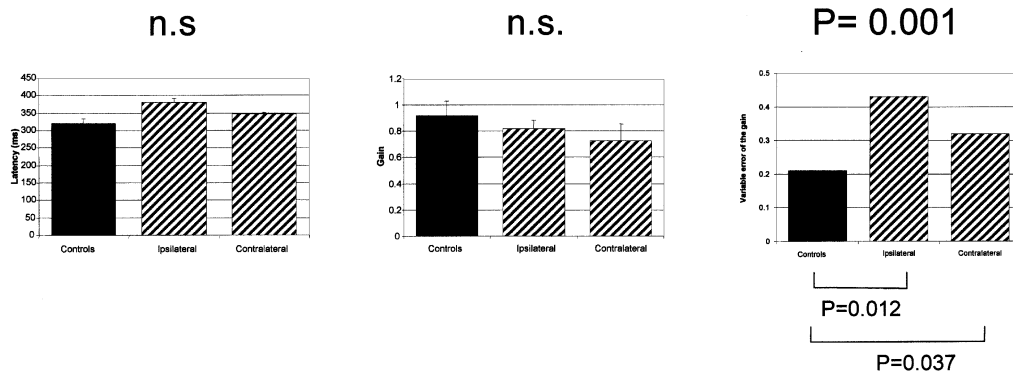


Fig. 4 Memory-guided saccades (MGS). Left, latency of MGS (bars indicate +1 SE); middle, gain of MGS; right, variable error of the gain. Note that latency of patients was only slightly increased, bilaterally, compared with that of controls, and the gain was only slightly decreased, whereas the variable error of the gain was significantly increased, bilaterally. Top, Kruskal–Wallis test; bottom, Mann–Whitney test.

In patients, the gain of MGS was 0.79 (SE = 0.05) ipsilaterally and 0.74 (SE = 0.13) contralaterally on average, compared with controls with 0.92 on average (SE = 0.02) (Fig. 4, middle), and was not significantly decreased. However, we cannot rule out the possibility that this lack of statistical significance was simply due here to the relative weakness of the sample of three patients. In contrast, the variable error of the gain (Fig. 4, right) was significantly increased, bilaterally: mean of 0.43 (interquartile range = 0.36–0.48) for ipsilateral saccades ($P = 0.012$), and of 0.32 (interquartile range = 0.23–0.34) for contralateral saccades ($P = 0.037$) compared with controls, with a mean of 0.21 (interquartile range = 0.06–0.23).

Lastly, in the predictive task (Fig. 5, left side), the percentage of anticipatory saccades was significantly decreased in the patient group: 47% (median; range = 39–52%) for contralateral saccades ($P = 0.033$) and 42% (median;

range = 27–52%) for ipsilateral saccades ($P = 0.023$). The controls made 75% (median; range = 30–100%) of anticipatory saccades. The gain of these anticipatory saccades was not different in patients and controls (Fig. 5, right side): mean of 0.72 (SE = 0.08) in controls, and mean of 0.84 (SE = 0.08) for ipsilateral saccades and 0.79 (SE = 0.05) for contralateral saccades in patients. The variability of the gain of anticipatory saccades was high in both controls and patients, with therefore no significant difference between the two groups.

In none of the paradigms were there any obvious differences in individual results between the patients with a left lesion and the patient with a right lesion.

Discussion

In these patients with a unilateral DLPFC lesion, we observed a marked impairment of antisaccades, MGS and predictive

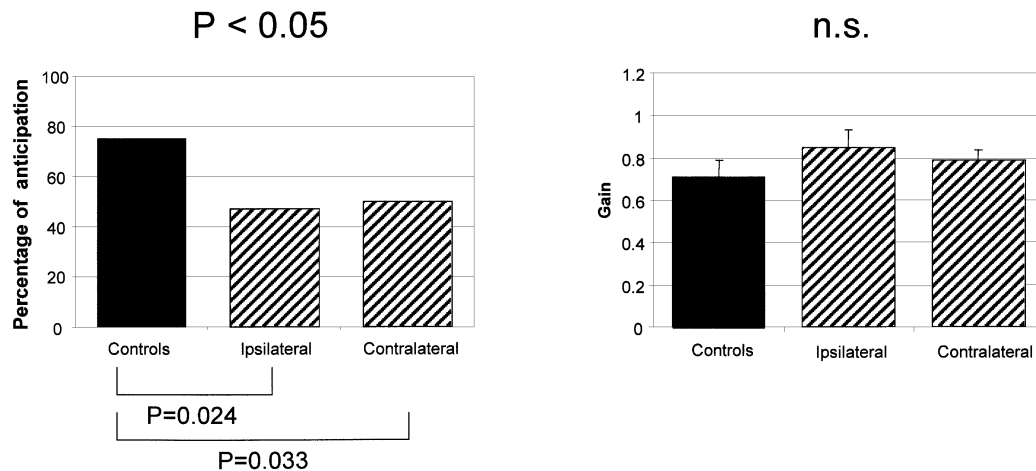


Fig. 5 Predictive saccades. Left, median percentage of anticipatory saccades; right, gain of anticipatory saccades (bars indicate +1 SE). Note that the percentage of anticipatory saccades of patients was decreased bilaterally compared with that of controls, whereas the gain of these saccades was similar to that of controls. Top, Kruskal–Wallis test; bottom, Mann–Whitney test.

saccades. Before discussing each of these abnormalities and the specific role of the DLPFC in saccade control, the normality of the other results also deserves some comments since they allow us to assert that the cortical areas triggering saccades were spared by the DLPFC lesions, in particular the nearby FEF.

Integrity of cortical areas triggering saccades

Three areas are involved in saccade triggering (Pierrot-Deseilligny *et al.*, 1995, 2002b; Leigh and Zee, 1999) (Fig. 6): the PEF, located in the intraparietal sulcus (Pierrot-Deseilligny *et al.*, 1991a; Müri *et al.*, 1996a; Perry and Zeki, 2000; Heide *et al.*, 2001; Simon *et al.*, 2002); the SEF, located in the upper part of the paracentral sulcus (Grosbras *et al.*, 1999), i.e. medially in the superior frontal gyrus; and the FEF, mainly located at the intersection between the superior frontal sulcus and the precentral sulcus, with some lateral extension in the precentral gyrus (Petit *et al.*, 1993; Paus, 1996; Heide *et al.*, 2001; Lobel *et al.*, 2001; Milea *et al.*, 2002) and anteriorly to the precentral sulcus (Blanke *et al.*, 2000; Rosano *et al.*, 2002). The PEF is involved mainly in the triggering of reflexive saccades in the gap task, since lesions affecting this area result in increased latency of such saccades (Pierrot-Deseilligny *et al.*, 1991a; Braun *et al.*, 1992; Heide and Kompf, 1998). In contrast, after lesions affecting the DLPFC, the SEF or the FEF, the latency of these saccades is not increased (Pierrot-Deseilligny *et al.*, 1991a). Lesion studies suggest that the SEF is involved mainly in the control of saccade sequences (Gaymard *et al.*, 1993) or saccades combined with body movements (Israël *et al.*, 1995), but such paradigms were not tested here. However, the SEF, like the PEF, is located at a distance from the DLPFC, and our anatomical data clearly show that these two areas were not damaged. In contrast, the FEF is located much closer to the DLPFC and, even though our anatomical study also suggests

that the FEF was not damaged in our patients, it nevertheless was important to confirm that this area was also functionally spared. The FEF is involved in the control of all intentional saccades, including MGS and predictive saccades (Rivaud *et al.*, 1994; Israël *et al.*, 1995; Gaymard *et al.*, 1999). Since MGS and predictive saccades are controlled upstream of the FEF by the DLPFC, the relatively subtle differences in the abnormalities resulting from lesions of the FEF and the DLPFC will be discussed below. The antisaccade paradigm also involves both areas, but the normality of the latency of correct antisaccades in our patients suggests that the FEF was spared (see next section). In contrast, some eye movements, such as visually guided saccades in the overlap task (Rivaud *et al.*, 1994; Gaymard *et al.*, 1999) and smooth pursuit (MacAvoy *et al.*, 1991; Rivaud *et al.*, 1994; Morrow and Sharpe, 1995; Heide *et al.*, 1996; Gaymard *et al.*, 1999), appear to be controlled more specifically by the FEF. The normality of overlap saccade latency and smooth pursuit gain in our patients are strong arguments supporting the preservation of the FEF, as well as a confirmation that these eye movements do not crucially involve the DLPFC. The involvement of the FEF in overlap task latency, but not in gap task latency, may be explained by an active disengagement of visual fixation in the former but not in the latter (Rivaud *et al.*, 1994; Gaymard *et al.*, 1999), in which fixation is already suppressed when the target appears. Lastly, it should be noted that the gain of contralateral visually guided saccades in the gap and overlap tasks was impaired in FEF lesions (Rivaud *et al.*, 1994; Gaymard *et al.*, 1999) but was normal here, which is another argument suggesting that the FEF was spared in our patients. Taken together, our anatomical and functional results suggest that not only the SEF and the PEF, but also the FEF were spared in these patients, allowing us to define, therefore, the specific spectrum of eye movement abnormalities due to isolated DLPFC lesions.

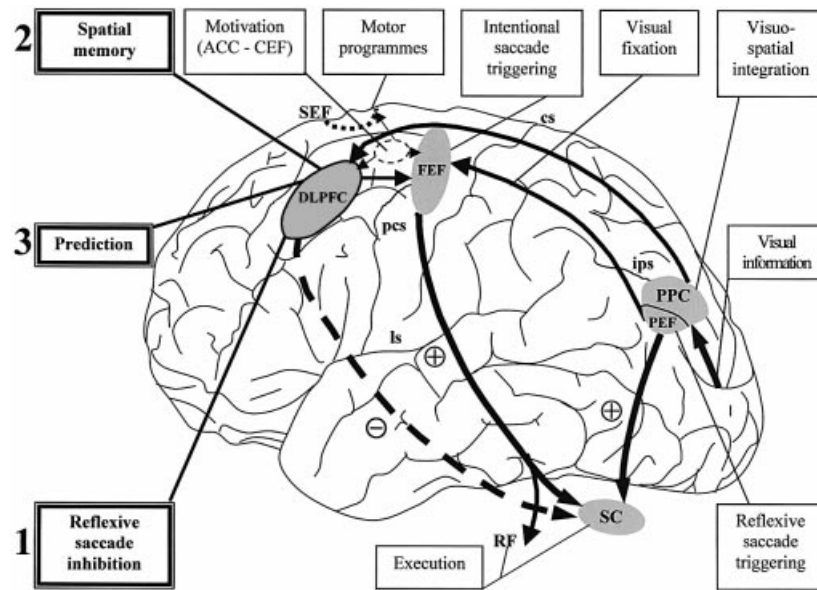


Fig. 6 Cortical areas involved in saccades. After receiving visual information in the occipital lobe and after visuospatial integration in the PPC, a saccade may be either triggered reflexively, mainly by the PEF, or triggered intentionally by the FEF, an area which also appears to be involved in active visual fixation. If a reflexive saccade must be inhibited, the DLPFC appears to play a crucial role (1). This area is also involved in short-term spatial memory (2) and prediction (3) when anticipatory saccades must be performed. With these three different actions, the DLPFC could play an important role in the decisional processes controlling ocular motor behaviour. The SEF could be involved in motor programmes including several successive saccades, or saccades combined with other body movements, whereas the CEF appears to activate all the areas controlling intentional saccades via a motivation process. ACC = anterior cingulate cortex; CEF = cingulate eye field; cs = central sulcus; DLPFC = dorsolateral prefrontal cortex; FEF = frontal eye field; ips = intraparietal sulcus; ls = lateral sulcus; pcs = precentral sulcus; PEF = parietal eye field; PPC = posterior parietal cortex; RF = brainstem reticular formation; SC = superior colliculus; SEF = supplementary eye field; 1, 2, 3 = the main actions of the DLPFC; + = saccade triggering; - = saccade inhibition.

Antisaccades

In our patients, the percentage of errors was markedly increased, bilaterally, in the antisaccade paradigm, but the latency of correct antisaccades was normal. In this paradigm, two different physiological processes are involved: (i) inhibition of unwanted reflexive visually guided saccades towards the target (i.e. the 'errors'), these errors being triggered mainly by the PEF, as already stated, when inhibition is lacking; and (ii) triggering of correct antisaccades in the opposite direction to the target, when inhibition has been effective. Since the latency of these correct antisaccades is increased after isolated FEF lesions (Rivaud *et al.*, 1994; Gaymard *et al.*, 1999), it may be deduced that the FEF is crucially involved in this second process, which is expected for the triggering of such an intentional saccade. In contrast, the FEF does not appear to be crucially involved in the first process, i.e. the inhibition of unwanted reflexive saccades, since the percentage of these saccades (the 'errors') remains normal after FEF lesions (Pierrot-Deseilligny *et al.*, 1991a; Rivaud *et al.*, 1994; Gaymard *et al.*, 1999). However, it is true that the monkey

has been shown to contain suppressive sites, i.e. cells whose stimulation does not elicit saccades but prevents saccade triggering (Burman and Bruce, 1997). Since these cells project to the rostral pole of the superior colliculus, this area could play a side role in reflexive saccade inhibition by increasing the activity of the fixation system. Nevertheless, the inhibition of reflexive saccades, which is under the control of the frontal lobe (Guitton *et al.*, 1985), appears to depend more specifically upon the DLPFC, as suggested by a previous lesion study (Pierrot-Deseilligny *et al.*, 1991a) and the results obtained using PET scan (Doricchi *et al.*, 1997) or functional MRI (fMRI) (Sweeney *et al.*, 1996; Müri *et al.*, 1998). The results of the present study fully confirm earlier findings in humans by showing, once more, with a bilateral increase in the percentage of errors, that reflexive saccade inhibition, i.e. the first physiological process involved in the antisaccade paradigm, is mainly under the control of the DLPFC. Furthermore, our results also confirm, by the normality of correct antisaccade latency, that the second physiological process involved in the antisaccade paradigm, i.e. the triggering of correct antisaccades, is not under the

control of the DLPFC. Therefore, in the antisaccade paradigm (at least with a gap), there is now cumulative evidence based on purely FEF lesions (Pierrot-Deseilligny *et al.*, 1991a; Rivaud *et al.*, 1994; Gaymard *et al.*, 1999) and purely DLPFC lesions (Pierrot-Deseilligny *et al.*, 1991a; and our present results) that the inhibition of reflexive saccades is under the control of the DLPFC and the triggering of correct antisaccades is under the control of the FEF (see also Connolly *et al.*, 2002). Yet, a degree of confusion persists in the literature on this point, mainly because, besides the activation of the DLPFC, an activation of the FEF has also been observed during the antisaccade paradigm using functional imaging (Sweeney *et al.*, 1996; Doricchi *et al.*, 1997; Müri *et al.*, 1998; Connolly *et al.*, 2002), which has sometimes led to the conclusion that this area may be involved in saccade inhibition (Cornelissen *et al.* 2002): on the basis of lesion study results, this would seem to be an erroneous interpretation, since the FEF is indeed involved in visual fixation and the triggering of correct antisaccades in the antisaccade paradigm, but this area does not appear to be crucial for saccade inhibition, at least when a gap is used. Thus, the visual fixation and/or the preparation of the triggering of correct antisaccades (Connolly *et al.*, 2002) probably generates the increase in the metabolism of the FEF observed in neuroimaging studies of the antisaccade paradigm. However, it should also be noted that an active inhibition of the FEF during this paradigm (probably originating in the DLPFC) may also result in a further increase in the metabolism of this area in such studies (Kimmig *et al.*, 2001), which does not imply, therefore, that this inhibition is generated in and starts from the FEF.

The inhibition function of the DLPFC could be exerted directly downstream on the brainstem or the superior colliculus, as suggested by experimental results (Everling *et al.*, 1999; Trappenberg *et al.*, 2001) and a human lesion study in which the superior colliculus was damaged (Pierrot-Deseilligny *et al.*, 1991c), via the direct prefronto-collicular tracts (Leichnetz *et al.*, 1981). Indeed, lesion studies suggest that the other cortical areas controlling saccades, including the FEF, are not involved in this function (see above). An exception to this is the anterior cingulate cortex (ACC), the posterior part of which could also be involved in antisaccades, as suggested by an fMRI study (Paus *et al.*, 1993) and lesion studies, (Gaymard *et al.*, 1998; Milea *et al.*, 2003a). However, the ACC could act early in saccade control, preparing all areas involved in intentional saccades, such as the FEF, the SEF and the DLPFC, but not the area mainly triggering reflexive saccades, i.e. the PEF (Gaymard *et al.*, 1998). This preparation could be due to a physiological process called motivation. With a relative lack of pre-activation of the DLPFC after an ACC lesion, the reflexive saccades under the control of the PEF could be less restrained, with a consequent increase in errors in the antisaccade paradigm. Be that as it may, the percentage of errors in the antisaccade paradigm appears to be a good marker of DLPFC

control, and is probably also the easiest to test among the saccade paradigms.

Memory-guided saccades

In our patients with a DLPFC lesion, MGS latency was slightly increased, but not significantly different from that of controls. The percentage of unwanted reflexive visually triggered saccades made just after the flash was increased, compared with controls, suggesting a relative disinhibition of reflexive saccades related to the prefrontal dysfunction (as for antisaccades, see above). The gain of MGS was moderately decreased, but not significantly different from that of controls, perhaps because of the small numbers in the patient group. In contrast, the variable error of the gain was markedly increased. The MGS paradigm is used in saccade physiology to study short-term spatial memory, which is the working memory controlling current, ongoing behaviour (Goldman-Rakic, 1996). In monkeys, electrophysiological and inactivation studies have shown that the DLPFC is involved in the control of short-term spatial memory used in MGS paradigms (Funahashi *et al.*, 1993; Roberts *et al.*, 1994; Goldman-Rakic, 1996; Sawaguchi and Iba, 2001). In humans, lesion studies have suggested that several cortical areas, including the DLPFC, are involved in MGS (Pierrot-Deseilligny *et al.*, 1991b, 1993, 1995, 2002b; Israël *et al.*, 1995). These results have been corroborated by functional imaging, showing that a large network of frontoparietal areas is active during such a paradigm (O'Sullivan *et al.*, 1995; Sweeney *et al.*, 1996; Heide *et al.*, 2001). However, recent functional imaging studies have questioned a predominant role of the DLPFC in maintenance of spatial information within this network, and suggest rather that the DLPFC may be responsible mainly for the selection of memory-guided behavioural responses, with maintenance being dependent on premotor and parietal cortices (Rowe *et al.*, 2000). It should be noted that the MGS paradigm comprises three successive phases, involving different types of physiological mechanisms (Fig. 2) (for a review see Pierrot-Deseilligny *et al.*, 2002a): (i) a first phase of perception, during which the visual stimulus (a peripheral flashed target) is presented, involving both the visual (occipital) and attentional (parietal) areas; (ii) a second phase, related to memorization (during the delay), starting after the visual stimulus presentation and under the control of the cortical area involved in spatial memory; in fact, the beginning of this second phase corresponds to visuospatial integration, a posterior parietal process occurring just after the visual stimulus presentation and allowing the subject to know the memorized position of the stimulus in relation not only to the eyes but probably also to the body; and (iii) after the go signal, the final phase of movement, during which the MGS is triggered by the frontal and parietal motor areas, and accuracy of spatial memory, reflected by that of the saccade, is measured. The results of lesion studies have shown that the accuracy of MGS is impaired after lesions affecting either the DLPFC, the posterior parietal cortex (PPC) or the FEF

(Pierrot-Deseilligny *et al.*, 1991*b*, 1993; Rivaud *et al.*, 1994; Israël *et al.*, 1995; Ploner *et al.*, 1999). More particularly, Ploner *et al.* (1999) have shown that after a pure FEF lesion, there is an increase in the systematic error in amplitude (i.e. a decrease in the gain), whereas after a lesion affecting both the FEF and the DLPFC, there is an increase both in the systematic error and in the variable error (with a dispersion of the amplitude values). Therefore, these results already suggested that the increase in the variable error was more specific to DLPFC damage and the decrease in the gain more specific to FEF damage. Our present results confirm that this observed increase in variable errors is not simply a cumulative effect of a combined FEF and DLPFC lesion, but rather a selective marker of DLPFC dysfunction. This interpretation is in line both with findings from lesion studies in monkeys (Funahashi *et al.*, 1993; Sawaguchi and Iba, 2001) and with cortical network models of spatial working memory (Compte *et al.*, 2000). In the latter, the spatial tuning of a network simulating DLPFC neurons, i.e. its variable error, critically depends on network size and increases with smaller networks. We propose that a similar phenomenon could explain the increase in variable error observed in our patients, where the size of the DLPFC network coding a distinct position in space is necessarily smaller than in healthy controls. It therefore appears reasonable to assume that space is coded differentially in the DLPFC and the FEF. This is corroborated further by the fact that the increase in MGS variable error is bilateral after a unilateral DLPFC lesion, whereas the decrease in the gain is clearly contralateral to the lesion after FEF damage (Rivaud *et al.*, 1994; Gaymard *et al.*, 1999). This means that, in humans, spatial information held in the DLPFC is less lateralized than the motor execution of MGS by the FEF. Accordingly, the patterns of abnormalities of saccade amplitude concerning the gain and the variable error are clearly different after pure FEF or DLPFC lesions.

However, although lesion studies in humans have shown that the DLPFC, the PPC and the FEF are indeed essential for the correct performance of MGS, such studies are no more able than functional imaging studies to tell us how the control of these different cortical areas is organized chronologically and which of them is more particularly involved in short-term spatial memory. We recently used transcranial magnetic stimulation (TMS)—a method with a good temporal resolution—to determine at which specific time the MGS paradigm is controlled by these different cortical areas. The results of these studies have shown that (i) the right PPC is involved before 300 ms after the appearance of the target, probably for visuospatial integration; (ii) the DLPFC is involved, bilaterally, during the memorization phase, corresponding to short-term spatial memory; and (iii) the FEF is involved in saccade triggering (Müri *et al.*, 1996*b*, 2000; Wipfli *et al.*, 2001). Therefore, the DLPFC controls short-term spatial memory in humans, as in the monkey, probably up to delays of 15–20 s, after which the medial temporal region could take over the control of medium- and long-term spatial memory (Ploner *et al.*, 1998, 2000; for a review see

Pierrot-Deseilligny *et al.*, 2002*a*). Furthermore, in a recent TMS study on the DLPFC, it was suggested that the mediation of memorized spatial information could be organized both serially (from the DLPFC to the medial temporal region) and independently in parallel (Nyffeler *et al.*, 2002, 2003). Finally, our findings clearly support the hypothesis that the function of the human DLPFC is unlikely to be restricted to selection of appropriate memory-guided responses (Rowe *et al.*, 2000), but that it is actively involved in maintenance of spatial information, as has been confirmed recently (Leung *et al.*, 2002).

Predictive saccades

Predictive saccades were also impaired in our patients, with a decrease in the percentage of anticipatory saccades but preservation of their gain. In this paradigm, in which both the location of the target and the timing of its occurrence are predictable, healthy subjects normally start to perform anticipatory saccades after a few cycles of appearance of the targets. Such anticipatory saccades are, therefore, non-visually guided saccades and also represent another type of intentional saccades. Based on studies of patients with focal FEF lesions, it has been shown that the FEF controls both the gain and the frequency of these anticipatory saccades, mainly contralaterally (Rivaud *et al.*, 1994; Gaymard *et al.*, 1999). These saccades are also disturbed in some degenerative diseases, such as Parkinson's disease (Crawford *et al.*, 1996), and after putamen lesions (Vermersch *et al.*, 1996), suggesting that subcortical structures are also important in the control of this paradigm. However, although the FEF probably triggers such intentional anticipatory saccades, it has yet to be determined which cortical area actually prepares them. Our current results suggest, for the first time in human studies, that the DLPFC is involved specifically in the control of timing of predictive saccades, by showing a decreased percentage of anticipatory saccades. This abnormality was clearly bilateral in our patients with DLPFC lesions, whereas it was mainly contralateral in patients with FEF lesions (Rivaud *et al.*, 1994). A greater delay of processing in the absence of a lateral target, possibly due to weaker spatial information, could explain the reduction in the frequency of anticipatory saccades in the predictive saccade task after a DLPFC lesion. This result is also consistent with recent functional studies showing that the DLPFC is the key structure for tasks requiring time production or memory of temporal intervals (Basso *et al.*, 2003). Thus, our results suggest that the DLPFC could be the neural basis for working memory in both spatial and temporal domains. The gain of anticipatory saccades was not affected in our patients, compared with controls, whereas it was impaired contralaterally to the lesion in FEF damage, as in all other saccade tasks (Rivaud *et al.*, 1994; Gaymard *et al.*, 1999). Therefore, in the predictive saccade task, the bilateral decrease in anticipatory saccades with preservation of the gain of these saccades appears to be specific to

Table 3. Comparison of eye movement abnormalities after DLPFC and FEF lesions

		Unilateral FEF lesions		Unilateral DLPFC lesions	
		Ipsilateral	Contralateral	Ipsilateral	Contralateral
Visually guided saccades: gap task	Latency	N	N	N	N
	Gain	N	↓	N	N
Visually guided saccades: overlap task	Latency	↑	↑	N	N
	Gain	N	↓	N	N
Antisaccades	Latency*	↑	↑	N	N
	% errors	N	N	↑	↑
Memory-guided saccades	Latency	↑	↑	N	N
	Gain	N	↓	N	N
	Variable error	N	N	↑	↑
Predictive (anticipatory) saccades	%	N	↓	↓	↓
	Gain	N	↓	N	N
Smooth pursuit	Gain	↓↓	↓	N	N

The results in the third and fourth columns are from Rivaud *et al.* (1994), Gaymard *et al.* (1999) or Ploner *et al.* (1999) and those in the fifth and sixth columns are from the current study. DLPFC = dorsolateral prefrontal cortex; FEF = frontal eye field; N = normal (or not significant); ↑ = significantly increased; ↓ = significantly decreased; ↓↓ = more marked abnormality than ↓; * Latency of correct antisaccades.

unilateral DLPFC damage and could be due mainly to the impairment of short-term spatial memory.

General considerations

It may be helpful to begin by summarizing the differences between the patterns of abnormalities observed in humans after lesions localized in the DLPFC in the present study and those previously reported after lesions localized in the FEF (Rivaud *et al.*, 1994; Gaymard *et al.*, 1999; Ploner *et al.*, 1999) (Table 3). After a unilateral DLPFC lesion, visually guided saccades and smooth pursuit are normal, whereas, after a unilateral FEF lesion, saccade latency is increased bilaterally in the overlap task, the gain is decreased contralaterally in the gap and overlap tasks, and the gain is decreased mainly ipsilaterally in smooth pursuit. In the antisaccade paradigm, exactly the opposite patterns of abnormalities exist, with a percentage of errors that is increased after a DLPFC lesion but normal after an FEF lesion, and an increased latency of correct antisaccades after an FEF lesion, but not after a DLPFC lesion. In the MGS paradigm, latency is markedly increased bilaterally after an FEF lesion, but only slightly increased after a DLPFC lesion. Furthermore, MGS accuracy is impaired contralaterally after an FEF lesion and bilaterally after a DLPFC lesion, with a marked systematic error in amplitude (decreased gain) in the former and mainly an increased variable error in amplitude in the latter. In predictive saccades, the percentage of anticipatory saccades is decreased in both cases, but more bilaterally after a DLPFC lesion, with preservation of the gain in the latter case whereas the gain is impaired contralaterally in the

former case. Thus, for the control of almost all eye movement characteristics, the FEF and DLPFC appear to act differently. Consequently, damage to these areas may be depicted on the basis of the specific ocular motor abnormalities described in our current study on the DLPFC or in our previous reports on the FEF.

How can we synthesize the multiple functions of the DLPFC in ocular motor control? A common aspect of all these functions is the involvement in the control of the short-term behaviour of ocular motor performance at different time intervals. In a first, decisional phase, the brain has to decide whether or not to inhibit a saccade, then, if appropriate, to facilitate saccade triggering such as in the predictive task, and finally to hold on to spatial information (short-term working memory). Furthermore, in a recent fMRI study, it was shown that the DLPFC is strongly involved when the subject has to make a self-selection of the direction (left or right) of a forthcoming intentional visually guided saccade (Milea *et al.*, 2003b), which represents another type of decisional process. In simple terms, the DLPFC has to interfere at the right moment during ongoing motor behaviour, which confirms, on the functional level, the proposed shaping of the temporal flow of information processing of the prefrontal cortex (Constantinidis *et al.*, 2002). In contrast, the FEF appears to have a more executive role in saccade physiology, controlling the triggering of all intentional saccades, the amplitude of contralateral saccades, and is also active during visual fixation and smooth pursuit.

In conclusion, the results of the current study in patients with lesions restricted to the DLPFC reveal a distinct pattern of ocular motor disturbances with mainly an impaired

inhibition of reflexive saccades, impaired spatial working memory and impaired adaptation of future behaviour, such as in prediction.

References

- Basso G, Nichelli P, Wharton CM, Peterson M, Grafman J. Distributed neural systems for temporal production: a functional MRI study. *Brain Res Bull* 2003; 59: 405–11.
- Blanke O, Spinelli L, Thut G, et al. Location of the human frontal eye field as defined by electrical stimulation: anatomical, functional and electrophysiological characteristics. *Neuroreport* 2000; 11: 1907–13.
- Braun D, Weber H, Mergner TH, Schulte-Monting J. Saccadic reaction times in patients with frontal and parietal lesions. *Brain* 1992; 115: 1359–86.
- Burman DD, Bruce CJ. Suppression of task-related saccades by electrical stimulation in the primate's frontal eye field. *J Neurophysiol* 1997; 77: 2252–67.
- Compte A, Brunel N, Goldman-Rakic PS, Wang XJ. Synaptic mechanisms and network dynamics underlying spatial working memory in a cortical network model. *Cereb Cortex* 2000; 10: 910–23.
- Connolly JD, Goodale MA, Menon RS, Munoz DP. Human fMRI evidence for the neural correlates of preparatory set. *Nat Neurosci* 2002; 5: 1345–52.
- Constantinidis C, Williams GV, Goldman-Rakic PS. A role for inhibition in shaping the temporal flow of information in prefrontal cortex. *Nat Neurosci* 2002; 5: 175–80.
- Cornelissen FW, Kimmig H, Schira M, et al. Event-related fMRI responses in the human frontal eye fields in a randomized pro- and antisaccade task. *Exp Brain Res* 2002; 145: 270–4.
- Crawford T, Goodrich S, Henderson L, Kennard C. Predictive responses in Parkinson's disease: manual key presses and saccadic eye movements to regular stimulus events. *J Neurol Neurosurg Psychiatry* 1989; 52: 1033–42.
- Doricchi F, Perani D, Incoccia C, et al. Neural control of fast-regular saccades and antisaccades: an investigation using positron emission tomography. *Exp Brain Res* 1997; 116: 50–62.
- Duncan J. An adaptive coding model of neural function in prefrontal cortex. *Nat Rev Neurosci* 2001; 2: 820–9.
- Everling S, Dorris NC, Klein RM, Munoz DP. Role of primate superior colliculus in preparation and execution of anti-saccades and pro-saccades. *J Neurosci* 1999; 19: 2740–54.
- Findlay JM. Spatial and temporal factors in the predictive generation of saccadic eye movements. *Vision Res* 1981; 21: 347–54.
- Fischer B, Ramsperger E. Human express saccades: extremely short reaction times of goal directed eye movements. *Exp Brain Res* 1984; 57: 191–5.
- Funahashi S, Bruce CJ, Goldman-Rakic PS. Dorsolateral prefrontal lesions and oculomotor delayed-response performance evidence for 'mnemonic scotomas'. *J Neurosci* 1993; 13: 1479–97.
- Gaymard B, Rivaud S, Pierrot-Deseilligny C. Role of the left and right supplementary motor areas in memory-saccade sequences. *Ann Neurol* 1993; 34: 404–6.
- Gaymard B, Rivaud S, Cassarini JF, Plonet C, Pierrot-Deseilligny C. Effects of anterior cingulate cortex lesions on ocular saccades in humans. *Exp Brain Res* 1998; 120: 173–83.
- Gaymard B, Ploner CJ, Rivaud-Péchéoux S, Pierrot-Deseilligny C. The frontal eye field is involved in spatial short-term memory but not in reflexive saccade inhibition. *Exp Brain Res* 1999; 129: 288–301.
- Goldman-Rakic PS. Regional and cellular fractionation of working memory. *Proc Natl Acad Sci USA* 1996; 93: 13473–80.
- Grosbras MH, Lobel E, Van de Moortele PF, Le Bihan D, Berthoz A. An anatomical landmark for the supplementary eye fields in human revealed with functional magnetic resonance imaging. *Cereb Cortex* 1999; 9: 705–11.
- Guioton D, Buchtel HA, Douglas RM. Frontal lobe lesions in man cause difficulties in suppressing reflexive glances and in generating goal-directed saccades. *Exp Brain Res* 1985; 58: 455–72.
- Heide W, Kömpf D. Combined deficits of saccades and visuo-spatial orientation after cortical lesions. *Exp Brain Res* 1998; 123: 164–71.
- Heide W, Kurzdin K, Kömpf D. Deficits of smooth pursuit eye movements after frontal and parietal lesions. *Brain* 1996; 119: 1951–69.
- Heide W, Binkofski F, Seitz RJ, et al. Activation of frontoparietal cortices during memorized triple-step sequences of saccadic eye movements: an fMRI study. *Eur J Neurosci* 2001; 13: 1177–89.
- Israël I, Rivaud S, Gaymard B, Berthoz A, Pierrot-Deseilligny C. Cortical control of vestibular-guided saccades in man. *Brain* 1995; 118: 1169–83.
- Kimmig H, Greenlee MW, Gondan M, Schira M, Kassubek J, Mergner T. Relationship between saccadic eye movements and cortical activity as measured by fMRI: quantitative and qualitative aspects. *Exp Brain Res* 2001; 141: 184–94.
- Leichnetz GR, Spencer RF, Hardy SGP, Astruc J. The prefrontal corticotectal projection in the monkey: an anterograde and retrograde horseradish peroxidase study. *Neuroscience* 1981; 6: 1023–41.
- Leigh RJ, Zee DS. *The neurology of eye movements*. 3rd edn. New York: Oxford University Press; 1999.
- Leung HC, Gore JC, Goldman-Rakic PS. Sustained mnemonic response in the human middle frontal gyrus during on-line storage of spatial memoranda. *J Cogn Neurosci* 2002; 14: 659–71.
- Lobel E, Kahane P, Leonards U, et al. Localization of the human frontal eye fields: anatomical and functional findings from functional magnetic resonance imaging and intracerebral electrical stimulation. *J Neurosurg* 2001; 95: 804–15.
- MacAvoy MG, Gottlieb JP, Bruce CJ. Smooth-pursuit eye movement representation in the primate frontal eye field. *Cereb Cortex* 1991; 1: 95–102.
- Milea D, Lobel E, Lehericy S, et al. Intraoperative frontal eye field

- stimulation elicits ocular deviation and saccade suppression. *Neuroreport* 2002; 13: 1359–64.
- Milea D, Lehericy S, Rivaud-Péchoux S, et al. Antisaccade deficit after anterior cingulate cortex resection. *Neuroreport*. 2003a; 14: 283–7.
- Milea D, Lobel E, Lehericy S, et al. Frontal correlates of decision where to look. *J Neurosci*. In press 2003b.
- Morrow MJ, Sharpe JA. Deficits of smooth-pursuit eye movement after unilateral frontal lobe lesions. *Ann Neurol* 1995; 37: 443–51.
- Müri RM, Iba-Zizen MT, Derosier C, Cabanis E, Pierrot-Deseilligny C. Location of the human posterior eye field with functional magnetic resonance imaging. *J Neurol Neurosurg Psychiatry* 1996a; 60: 445–8.
- Müri RM, Vermersch AI, Rivaud S, Gaymard B, Pierrot-Deseilligny C. Effects of single-pulse transcranial magnetic stimulation over the prefrontal and posterior parietal cortices during memory-guided saccades in humans. *J Neurophysiol* 1996b; 76: 2102–6.
- Müri RM, Heid O, Nirkko AC, et al. Functional organisation of saccades and antisaccades in the frontal lobe in humans: a study with echo planar functional magnetic resonance imaging. *J Neurol Neurosurg Psychiatry* 1998; 65: 374–7.
- Müri RM, Gaymard B, Rivaud S, Vermersch A, Hess CW, Pierrot-Deseilligny C. Hemispheric asymmetry in cortical control of memory-guided saccades. A transcranial magnetic stimulation study. *Neuropsychologia* 2000; 38: 1105–11.
- Nyffeler T, Pierrot-Deseilligny C, Felblinger J, Mosimann UP, Hess CW, Müri RM. Time-dependant hierarchical organization of spatial working memory: a transcranial magnetic stimulation study. *Eur J Neurosci* 2002; 16: 1823–7.
- Nyffeler T, Pierrot-Deseilligny C, Pflugshaupt T, von Wartburg R, Hess CW, Müri RM. Parallel and serial processing components in memory-guided saccade control. A TMS study. *Neuroreport*. In press 2003.
- O'Sullivan EP, Jenkins IH, Henderson L, Kennard C, Brooks DJ. The functional anatomy of remembered saccades: a PET study. *Neuroreport* 1995; 6: 2141–4.
- Paus T. Location and function of the human frontal eye field: a selective review. *Neuropsychologia* 1996; 34: 475–83.
- Paus T, Petrides M, Evans AC, Meyer E. Role of the human anterior cingulate cortex in the control of oculomotor, manual, and speech responses: a positron emission tomography study. *J Neurophysiol* 1993; 70: 453–69.
- Perry RJ, Zeki S. The neurology of saccades and covert shifts in spatial attention. An event-related fMRI study. *Brain* 2000; 123: 2273–88.
- Petit L, Orssaud C, Tzourio N, Salamon G, Mazoyer B, Berthoz A. PET study of voluntary saccadic eye movements in humans: basal ganglia–thalamocortical system and cingulate cortex involvement. *J Neurophysiol* 1993; 69: 1009–17.
- Pierrot-Deseilligny C, Rivaud S, Gaymard B, Agid Y. Cortical control of reflexive visually guided saccades. *Brain* 1991a; 114: 1473–85.
- Pierrot-Deseilligny C, Rivaud S, Gaymard B, Agid Y. Cortical control of memory-guided saccades in man. *Exp Brain Res* 1991b; 83: 607–17.
- Pierrot-Deseilligny C, Rosa A, Masmoudi K, Rivaud S, Gaymard B. Saccade deficits after a unilateral lesion affecting the superior colliculus. *J Neurol Neurosurg Psychiatry* 1991c; 54: 1106–9.
- Pierrot-Deseilligny C, Israël I, Berthoz A, Rivaud S, Gaymard B. Role of the different frontal lobe areas in the control of the horizontal component of memory-guided saccades in man. *Exp Brain Res* 1993; 95: 166–71.
- Pierrot-Deseilligny C, Rivaud S, Gaymard B, Müri RM, Vermersch AI. Cortical control of saccades. *Ann Neurol* 1995; 37: 557–67.
- Pierrot-Deseilligny C, Müri RM, Rivaud-Péchoux S, Gaymard B, Ploner CJ. Cortical control of spatial memory in humans: the visuo-oculomotor model. *Ann Neurol* 2002a; 52: 10–9.
- Pierrot-Deseilligny C, Ploner CJ, Müri RM, Gaymard B, Rivaud-Péchoux S. Effects of cortical lesions on saccadic eye movements in humans. *Ann NY Acad Sci* 2002b; 956: 216–29.
- Ploner CJ, Gaymard B, Rivaud S, Agid Y, Pierrot-Deseilligny C. Temporal limits of spatial working memory in humans. *Eur J Neurosci* 1998; 10: 794–7.
- Ploner CJ, Rivaud-Péchoux S, Gaymard BM, Agid Y, Pierrot-Deseilligny C. Errors of memory-guided saccades in humans with lesions of the frontal eye field and the dorsolateral prefrontal cortex. *J Neurophysiol* 1999; 82: 1086–90.
- Ploner CJ, Gaymard B, Rivaud-Péchoux S, et al. Lesions affecting the parahippocampal cortex yield spatial memory deficits in humans. *Cereb Cortex* 2000; 10: 1211–6.
- Rajkowska G, Goldman-Rakic PS. Cytoarchitectonic definition of prefrontal areas in the normal human cortex. II. Variability in locations of areas 9 and 46 and relationship to the Talairach Coordinate System. *Cereb Cortex* 1995; 5: 323–37.
- Rivaud S, Müri RM, Gaymard B, Vermersch AI, Pierrot-Deseilligny C. Eye movement disorders after frontal eye field lesions in humans. *Exp Brain Res* 1994; 102: 110–20.
- Roberts AC, De Salvia MA, Wilkinson LS, et al. 6-Hydroxydopamine lesions of the prefrontal cortex in monkeys enhance performance on an analog of the Wisconsin Card Sort Test: possible interactions with subcortical dopamine. *J Neurosci* 1994; 14: 2531–44.
- Rosano C, Krisky CM, Welling JS, et al. Pursuit and saccadic eye movement subregions in human frontal eye field: a high-resolution fMRI investigation. *Cereb Cortex* 2002; 12: 107–15.
- Rowe JB, Toni I, Josephs O, Frackowiak RS, Passingham RE. The prefrontal cortex. Response selection or maintenance within working memory? *Science* 2000; 288: 1656–60.
- Sawaguchi T, Iba M. Prefrontal cortical representation of visuospatial working memory in monkeys examined by local inactivation of muscimol. *J Neurophysiol* 2001; 86: 2041–53.
- Simon O, Mangin JF, Cohen L, Le Bihan D, Dehaene S. Topographical layout of hand, eye, calculation, and language-related areas in the human parietal lobe. *Neuron* 2002; 33: 475–87.
- Smit AC, Van Gisbergen JAM. A short-latency transition in saccade

dynamics during square-wave tracking and its significance for the differentiation of visually-guided and predictive saccades. *Exp Brain Res* 1989; 76: 64–74.

Sweeney JA, Mintun MA, Kwee S, et al. Positron emission tomography study of voluntary saccadic eye movements and spatial working memory. *J Neurophysiol* 1996; 75: 454–68.

Talairach J, Tournoux P. Co-planar stereotaxic atlas of the human brain. Stuttgart: Thieme; 1988.

Trappenberg TP, Dorris NC, Munoz DP, Klein RM. A model of saccade initiation based on the competitive integration of exogenous and endogenous signals in the superior colliculus. *J Cogn Neurosci* 2001; 13: 256–71.

Vermersch AI, Müri RM, Rivaud S, et al. Saccade disturbances after bilateral lentiform nucleus lesions in humans. *J Neurol Neurosurg Psychiatry* 1996; 60: 179–84.

Wipfli M, Felblinger J, Mosimann UP, Hess CW, Schlaepfer TE, Müri RM. Double-pulse transcranial magnetic stimulation over the frontal eye field facilitates triggering of memory-guided saccades. *Eur J Neurosci* 2001; 14: 571–5.

*Received October 11, 2002. Revised February 4, 2003.
Accepted February 5, 2003*