

Nephrol Dial Transplant (2005) 20: 2557–2560

doi:10.1093/ndt/gfi019

Advance Access publication 2 August 2005

Case Report

Early renal failure after domino hepatic transplantation using the liver from a compound heterozygous patient with primary hyperoxaluria

Stefan Farese¹, Nicolas Trost¹, Daniel Candinas² and Uyen Huynh-Do¹

¹Division of Nephrology and Hypertension, and ²Department of Visceral and Transplantation Surgery, University of Bern Medical School, Inselspital, Bern, Switzerland

Abstract

Background. To cover the shortage of cadaveric organs, new approaches to expand the donor pool are needed. Here we report on a case of domino liver transplantation (DLT) using an organ harvested from a compound heterozygous patient with primary hyperoxaluria (PHO), who underwent combined liver and kidney transplantation. The DLT recipient developed early renal failure with oxaluria. The time to the progression to oxalosis with renal failure in such situations is unknown, but, based on animal data, we hypothesize that calcineurin inhibitors may play a detrimental role.

Methods. A cadaveric liver and kidney transplantation was performed in a 52-year-old male with PHO. His liver was used for a 64-year-old patient with a non-resectable, but limited cholangiocarcinoma.

Results. While the course of the PHO donor was uneventful, in the DLT recipient early post-operative, dialysis-dependent renal failure with hyperoxaluria developed. Histology of a kidney biopsy revealed massive calcium oxalate crystal deposition as the leading aetiological cause.

Conclusions. DLT using PHO organs for marginal recipients represents a possible therapeutic approach regarding graft function of the liver. However, it may negatively alter the renal outcome of the recipient in an unpredictable manner, especially with concomitant use of cyclosporin. Therefore, we suggest that, although DLT should be promoted, PHO organs are better excluded from such procedures.

Keywords: calcium oxalate; cyclosporin; domino liver; primary hyperoxaluria; renal failure; transplantation

Introduction

In the domino procedure, the liver harvested from a patient undergoing a hepatic transplantation to correct an inherited metabolic disorder is used as a donor organ for a subsequent graft in a second liver recipient. Thus, it allows the shortage of cadaveric organs to be overcome and expands the donor pool. Organs with a single protein dysfunction, but normal tissue anatomy, may be acceptable for patients with advanced hepatic malignancies or for aged recipients. Until now, this approach has been successfully performed in several cases of familial amyloid polyneuropathy (FAP) [1].

Primary hyperoxaluria (PHO) is a rare autosomal recessive disorder with a variable phenotype. The liver-specific deficiency of alanine-glyoxylate aminotransferase (AGT) results in hepatic overproduction of oxalate, systemic calcium oxalate deposits in bone, heart, vessels and nerves, hyperoxaluria and end-stage renal disease after years to decades [2].

Here we report on a patient with a locally advanced cholangiocarcinoma, who underwent domino liver transplantation (DLT) using the liver from an adult donor with compound heterozygous PHO who subsequently developed renal failure with massive renal calcium oxalate deposits within a few days after surgery.

Case

Donor history

A 52-year-old man with dialysis-dependent end-stage renal disease (ESRD) and normal hepatic function was selected as a candidate for kidney transplantation.

Of note in his medical history were several episodes of calcium oxalate nephrolithiasis with repeated extracorporeal shock wave lithotripsy treatments in

Correspondence and offprint requests to: Stefan Farese, MD, Division of Nephrology and Hypertension, University of Bern Medical School, Inselspital, Freiburgstrasse 15, 3010, Berne, Switzerland. Email: stefan.farese@insel.ch

the past 12 years and recurrent urinary tract infections. In order to obtain a better control of the infectious complications and in the presence of residual stones in the renal pelvis, the left kidney was removed at the age of 49 years. Despite the lower incidence of urinary tract infections after nephrectomy, renal function progressively worsened and chronic haemodialysis was started in the same year. Nine months later, a first kidney transplantation (cadaver graft, 1 DR match, immunosuppression with cyclosporin A, steroids and MMF) was performed, complicated by primary delayed graft function and systemic cytomegalovirus infection. Only 3 months later, the transplanted kidney was removed because of graft failure, and chronic intermittent haemodialysis treatment was re-established. Histopathological analysis of the explanted graft showed diffuse deposition of oxalate crystals in the renal parenchyma. Additional careful histological reassessment of the left kidney, which had been removed 3 years earlier, also showed multiple calcium oxalate depositions.

The clinical suspicion of PHO was proved by genetic analysis, demonstrating the loss-of-function G508A mutation. This mutation represents one of >30 known mutations [2] of the AGXT gene (encoding AGT) and accounts for ~25% of the mutant alleles in PHO type I patients. The other mutant allele was not specified (compound heterozygous mutation).

Twenty-eight months later, as a suitable cadaveric donor became available, the patient underwent a combined liver/kidney transplantation. Hepatic work-up prior to transplantation included liver tests, viral serology, magnetic resonance imaging (MRI) and duplex sonography. In the absence of any structural and functional deficiency other than the compound heterozygous PHO mutation and because of the long latency period until development of ESRD, we considered using his liver for DLT in a compatible patient with a non-resectable but limited cholangiocarcinoma. The donor gave his written consent prior to transplantation for this procedure. Modified hepatectomy followed by standard orthotopic liver transplantation and renal transplantation in the right iliac fossa was performed in the PHO patient. At a follow-up of 5 months, the post-transplantation course of the domino donor was uneventful, with good function of the liver and kidney graft although marked oxaluria was present.

Domino recipient history

A 64-year-old man was suffering from a locally advanced, recurrent (segments IV/VIII) and presently not resectable cholangiocarcinoma. Two years earlier, at initial diagnosis, he underwent bisegmental (II/III) hepatic resection followed by an adjuvant gemcitabine, then an oxaliplatin/fluorouracil/leucovorin regimen. Since prognosis with this type of neoplasm is poor and conventional liver transplantation in this setting confers a high risk of recurrence and is not a standard listing criterion, the patient was informed about

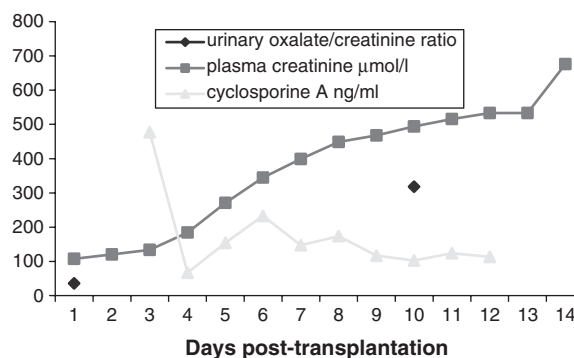


Fig. 1. Creatinine ($\mu\text{mol/l}$, normal range 59–104), urine oxalate excretion ($\mu\text{mol/l/mmol}$ creatinine, normal range 15–32) and cyclosporin A trough levels (ng/ml) in the domino recipient.

the possibility of DLT and gave his written consent for such a procedure. Tumour assessment prior to transplantation included liver tests, MRI, colono- and gastroscopy and chest X-ray. As a co-morbid condition, the patient presented with a mild renal insufficiency (creatinine clearance 63 ml/min) without proteinuria or haematuria, and the kidney appeared normal on ultrasound and nuclear magnetic resonance evaluation. Thus, in the absence of other nephrotoxic conditions, the mild renal insufficiency [glomerular filtration rate (GFR) 63 ml/min] was interpreted as a consequence of now controlled, yet long-standing arterial hypertension. Consequently, no further evaluations such as renal biopsy were performed prior to transplantation, and a diagnosis of suspected nephroangiosclerosis was given.

Orthotopic hepatic transplantation into the domino recipient was performed without any technical problems, the cold ischaemia time was 4 h and 40 min. The initial immunosuppressive therapy consisted of high dose steroids and cyclosporin A (Figure 1). The post-operative course was uneventful for wound healing and hepatic function, but was complicated by a rapid decline of renal function (Figure 1). Concurrently, we noted a marked increase of oxaluria (Figure 1) and a rapidly progressive sonographic hyperechogenicity of the renal parenchyma, suggestive of renal oxalate deposition. All possible causes of a secondary hyperoxaluria were excluded (diarrhoea, increased dietary oxalate intake). Despite early hyperhydration and administration of alkaline agents, thiazide diuretics and high-dose pyridoxine (a cofactor of AGT), further renal oxalate deposition could not be prevented, as shown by a renal biopsy 18 days after transplantation. Progression to dialysis-dependent organ failure occurred within 12 days post-operatively. At a follow-up of 4 months and in the presence of a newly developed chest wall metastasis, the patient was switched from cyclosporin A to sirolimus and a palliative treatment with gemcitabine was started. Despite calcineurin inhibitor-free immunosuppression, renal function did not recover and the patient remained on chronic, ambulant haemodialysis with normal liver function. He died

8 months after transplantation from a bacterial pneumonia.

Discussion

DLT represents one of several ways to overcome the shortage of cadaveric organs and expands the donor pool in particular circumstances. The purpose of such a procedure is to harvest an organ with a single protein defect for a marginal recipient with compromised long-term prognosis. Therefore, the natural course of the 'transplanted disease' should be longer than the expected post-transplant survival. Performing a DLT does not create an additional risk for the domino donor [1]. The principal technical issue in DLT is the sectioning of the suprahepatic vena cava, and so providing an adequate cuff for both the donor and the explanted liver. In the literature, most cases of DLT are described using organs from patients with FAP [1]. In FAP, the structure of transthyretin, a liver-derived plasma protein, is abnormal and its accumulation causes symptomatic disease after a latency of 30–40 years.

In our case, the liver of a compound heterozygous PHO patient was used. PHO is a rare autosomal recessive disease that results from endogenous overproduction of oxalic acid, as opposed to secondary hyperoxaluria, which is induced by increased intestinal absorption or excessive dietary intake of oxalate.

In type I PHO, which represents the most common form, the activity of the liver-specific peroxisomal enzyme AGT is low or absent. One-half of the patients show no detectable AGT activity, whereas the other half have variable enzyme activity ranging from 2 to 48% [2,3]. Interestingly, even patients with residual activity may not differ phenotypically from those without activity, a fact that has been attributed to a mistargeting of the enzyme to the mitochondria instead of the peroxisomes [2,3]. As a consequence of the altered AGT activity, urinary excretion of oxalate and, in most cases of type I PHO, also glycolate is increased. Since oxalate is freely filtered at the glomerular level, it is present at high concentrations in the proximal tubule, where it can act as a predisposing factor for urinary stone formation. Apart from deposition of calcium oxalate crystals in the renal parenchyma, and thereby induction of a foreign body reaction, high oxalate concentrations in the tubular fluid have direct toxic effects on tubular cells, probably by promoting the production of free radicals [4]. This mechanism may directly contribute to the rapid deterioration of renal function observed in PHO patients in contrast to the slower decline in renal function associated with nephrocalcinosis of other origins.

Currently we found only two published cases in the literature reporting a DLT harvesting PHO organs [5,6]. In one case, a split graft was used in a neonate with fulminant hepatic failure as a bridge to definitive liver transplantation within 4 months. The authors

report early, but transient deterioration of renal function and signs of early nephrocalcinosis in a CT scan 3 months after DLT. The other case reports a 69-year-old male with hepatitis C-related cirrhosis and a multifocal hepatocellular carcinoma who received the liver of a PHO donor. Recovery was uneventful, but hyperoxaluria was observed and renal function worsened from a creatinine clearance of 95 ml/min (pre-operative) to 43 ml/min at a follow-up of 8 months. In both cases, a cyclosporin-containing immunosuppressive regimen was used. In a third, unpublished case (Dr G. Mentha, Geneva, Switzerland, personal communication), the DLT recipient has a good liver function at a follow-up of 5 years without relapse of the initial hepatocellular carcinoma, but also developed dialysis-dependent ESRD. In our case, dialysis-dependent renal failure of the native kidneys developed 12 days after transplantation and was histologically proved to be associated with massive deposits of calcium oxalate crystals in the renal parenchyma.

Supersaturation of the plasma with calcium oxalate and subsequent systemic oxalate deposition occur earlier in the course of renal insufficiency in PHO patients compared with non-PHO patients with hyperoxaluria and renal failure. Calcium oxalate saturation increases markedly at a GFR of <45 and <8 ml/min, respectively, in these patients [2]. Since our recipient had a GFR well above these limits, mobilization of pre-existing systemic oxalate deposits after transplantation seems to be less probable as an explanation for the deleterious course. When the transplantation of a PHO organ to a non-PHO patient causes a suddenly released oxalate load that is high enough to cause rapid renal failure, and when this problem is preventable by forced fluid intake is not known to us. The only comparable published case is cited above [6], where renal function declined over a much longer period.

In the presence of a previously stable kidney function over decades in the compound heterozygous PHO donor, one could speculate about a possible (enhanced) toxicity of the cyclosporin-containing immunosuppressive regimen as a reason for the rapid decline in the renal function of our DLT recipient. Since it is well known that calcineurin inhibitors can negatively alter GFR, the rapid oxalate deposition in the kidney may be explained by a reduced GFR in the presence of the additional transplanted 'oxalate load'. Additionally, there is evidence that calcineurin inhibitors may induce renal tubular acidosis, another lithogenic condition associated with hypocitraturia and calcinosis of the renal parenchyma. On the other hand, Selvam and Adhirai demonstrated in a rat model that cyclosporin *per se* induced hyperoxaluria, and administration of the drug to hyperoxalic rats potentiated the deposition of calcium oxalate crystals by different mechanisms in renal parenchyma. First, damaged cell membranes enhanced the nucleation of calcium oxalate crystals at a lower supersaturation, and secondly, cyclosporin treatment in these animals resulted in stimulating production of calcium oxalate-binding proteins that can act as a nucleus for crystallization.

Of note, renal and liver tissues of the cyclosporin-treated hyperoxaluric animals were depleted of antioxidants such as reduced glutathione, vitamin E and C, and showed increased lipid peroxidation from membrane damage of the cells. In these experiments, the excessive, cyclosporin-induced crystal deposition was prevented by administration of the antioxidant vitamin E [7–9], suggesting an oxidative stress-related mechanism.

Patients with PHO undergoing kidney transplantation alone for ESRD have been shown to have impaired graft survival compared with control groups [2,10]. To our knowledge, it is not known if calcineurin inhibitors, by inducing hyperoxaluria or promoting intrarenal nucleation of calcium oxalate, may contribute to the impaired outcome after renal transplantation in this population. Since hyperoxaluria *per se* promotes the formation of free radicals, we hypothesize that the combination with an antioxidant-depleting calcineurin inhibitor in our DLT recipient could have played a role in the rapid progression of renal failure. Whether our PHO donor lost his first renal graft by a cyclosporin-induced mechanism, by mobilization of the systemic oxalate deposits after transplantation or both is not clear.

As a conclusion, based on our case report and the limited published data, we suggest that PHO organs should not be used for DLT. The heterogeneity of the disease, the poor correlation between severity and biochemical parameters as well as the increasing number of known AGXT gene mutations (whose significance is not clearly understood) may produce an unpredictable course after transplantation and immunosuppression, even when organs from compound heterozygous donors with a long latency period to symptomatic disease are used. In this setting, calcineurin inhibitors, apart from their well known vasoconstriction-mediated nephrotoxicity, may play a specific role in increasing intrarenal calcium oxalate deposition and thereby damaging the kidneys.

Finally, PHO in our DLT donor was diagnosed only after a first unsuccessful renal transplantation. Therefore, nephrologists and urologists treating young adults with nephrolithiasis should remain vigilant in order to not overlook PHO and prevent a delay in diagnosis of the disease.

Conflict of interest statement. None declared.

References

1. Azoulay D, Samuel D, Castaing D *et al.* Domino liver transplants for metabolic disorders: experience with familial amyloidotic polyneuropathy. *J Am Coll Surg* 1999; 189: 584–593
2. Leumann E, Hoppe B. The primary hyperoxalurias. *J Am Soc Nephrol* 2001; 12: 1986–1993
3. Danpure CJ, Jennings PR, Fryer P *et al.* Primary hyperoxaluria type I: genotypic and phenotypic heterogeneity. *J Inherit Metab Dis* 1994; 17: 487–499
4. Scheid C, Koul H, Hill WA *et al.* Oxalate toxicity in LLC-PK1 cells: role of free radicals. *Kidney Int* 1996; 49: 413–419
5. Casas-Melley AT, Thomas PG, Krueger LJ *et al.* Domino as a bridge to definitive liver transplantation in a neonate. *Pediatr Transplant* 2002; 6: 249–254
6. Donckier V, Nakadi I EI, Closset J *et al.* Domino hepatic transplantation using the liver from a patient with primary hyperoxaluria. *Transplantation* 2001; 17: 1346–1348
7. Selvam R, Adhirai M. Vitamin E pretreatment prevents cyclosporine A-induced crystal deposition in hyperoxaluric rats. *Nephron* 1997; 75: 77–81
8. Adhirai M, Selvam R. Effect of cyclosporine on liver antioxidants and the protective role of vitamin E in hyperoxaluria in rats. *J Pharm Pharmacol* 1998; 50: 501–505
9. Adhirai M, Selvam R. Effect of cyclosporine A on tissue lipid peroxidation and membrane bound phosphatases in hyperoxaluric rat and the protection by vitamin E pretreatment. *Jpn J Med Sci Biol* 1997; 50: 9–17
10. Cibrik DM, Kaplan B, Arndorfer JA *et al.* Renal allograft survival in patients with oxalosis. *Transplantation* 2002; 74: 707–10

Received for publication: 5.4.05

Accepted in revised form: 21.6.05