



ELSEVIER

European Journal of Cardio-thoracic Surgery 19 (2001) 940–942

EUROPEAN JOURNAL OF
CARDIO-THORACIC
SURGERYwww.elsevier.com/locate/ejts

Case report

Constrictive tuberculous pericarditis in a HIV-positive patient

Friedrich S. Eckstein^{a,*}, Michael K. Bohlmann^a, Mary-Claude Balmer^b, Thierry P. Carrel^a^a*Clinic for Cardiovascular Surgery, University Hospital, Inselspital, Berne, Switzerland*^b*Department of Pathology, University Hospital, Inselspital, Berne, Switzerland*

Received 13 November 2000; received in revised form 28 March 2001; accepted 28 March 2001

Abstract

Constrictive pericarditis is a relatively rare clinical manifestation nowadays. We present the case of an HIV-positive patient with constrictive calcified pericarditis due to an infection with *Mycobacterium tuberculosis*. Pericardectomy was performed. The therapeutical approach is discussed and the literature is reviewed. © 2001 Elsevier Science B.V. All rights reserved.

Keywords: Constrictive pericarditis; Tuberculosis; HIV; Cardiac surgery

1. Introduction

Constrictive pericarditis is a relatively rare clinical manifestation nowadays but may be caused by infectious diseases, radiation, rheumatoid disease and sarcoidosis or may appear late following trauma or after cardiac surgery. We report an unusual case for Western countries of a HIV-positive patient with constrictive calcified tuberculous pericarditis as stage of an advanced extrapulmonary tuberculosis.

2. Materials and methods

A 37-year-old man from Angola was admitted to a peripheral hospital with fever and dyspnea. At clinical examination major findings were enlarged axillary lymph nodes, and clinical signs of beginning right heart insufficiency with visible congested jugular veins, abdominal distension and tachycardia. Chest radiography did not show any major pathologic findings. Screening for all common infections in African patients revealed HIV disease (stage C3) and tuberculosis with a multiresistant mycobacterium; the latter was diagnosed by a biopsy of a cervical lymph node. Echocardiography and computed tomography (CT) showed multiple masses adherent to the pericardium with a maximum size of 75 × 43 mm leading to severe compression of the left and right ventricle (Fig. 1). The patient was treated with a triple antiviral (Lamivudin 150 mg and Zidovudin 300 mg twice daily respectively, Efavir-

enz 600 mg daily) combined with an anti-tuberculous therapy (Clarithromycine 500 mg twice daily, Ethambutol 900 mg daily, Isoniazid 300 mg daily; Pyrazinamid 2000 mg daily and Levofloxacin 250 mg daily). Steroid therapy (Prednisolon 50 mg daily) was added for 10 weeks to reduce the clinical symptoms. Viremia disappeared and the CD4 + count improved from 74/ml to 208/ml. Repeated CT scans and echocardiography showed slight increase of pericardial masses with signs of liquefaction and central necrosis in the major tuberculomas. To prevent impairment of the cardiac tamponade on the development of a constrictive pericarditis, pericardectomy was found to be indicated. Median sternotomy was performed and severe adhesions of the pericardium with the heart were released. This was followed by a slight rise in arterial (from 80 to 100 mmHg) and decrease in central venous pressure (from 16 to 11 mmHg). A majority of the tuberculomas could be completely removed. Small parts of the tuberculomas had to be left in situ because of pericardial infiltration in the region of both phrenic nerves. Chest closure was performed in a standard fashion.

3. Results

Histologic examination of the pericardium revealed granulomatous inflammation with areas of necrosis and Langerhans giant cell reaction. However no acid-fast bacilli could be detected by Ziehl–Neelsen staining. Therefore DNA was extracted from paraffin sections and amplified by polymerase chain reaction (PCR) with the IS6110 primers (specific for the *Mycobacterium tuberculosis* complex) and the speci-

* Corresponding author. Tel.: +41-31-6322111; fax: +41-31-6322919.
E-mail address: friedrich.eckstein@insel.ch (F.S. Eckstein).

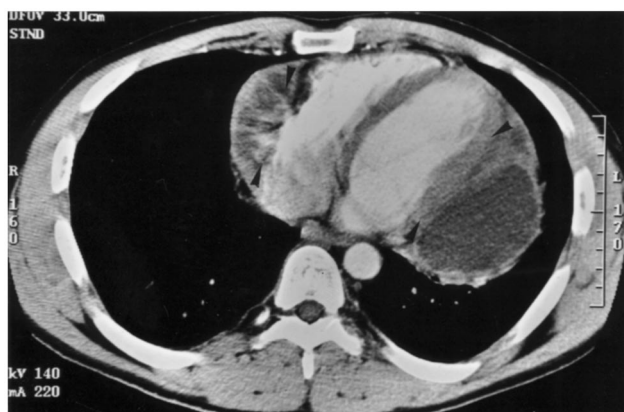

Fig. 1. CT showed multiple masses adherent to the pericardium leading to severe compression of the left and right ventricle (arrow heads).

fic 12-base pairs PCR product was detected by agarose gel electrophoresis (Fig. 2). In comparison results were compatible with tuberculosis.

The further postoperative course was uneventful. The patient was discharged from hospital under antiviral and tuberculostatic therapy. He is currently asymptomatic and doing well while pursuing his normal daily activities.

4. Discussion

Constrictive pericarditis is a chronic inflammatory process that involves both fibrous and serous layers of the pericardium and that leads to pericardial thickening with consecutive compression of the ventricles. This results in impairment of diastolic filling and reduces cardiac function [1]. Our patient did not exhibit all clinical signs of chronic pericarditis but an impressive compression of both ventricles was seen during the operation. Constrictive pericarditis is best treated by pericardiectomy since cardiac tamponade may appear shortly. Hospital mortality after pericardiectomy is low (up to 5% [2]) and long term results after the operation are good. Subtotal pericardiectomy from phrenic nerve to phrenic nerve as carried out in our patient has comparable results in survival and freedom from reoperation [3].

An increasing incidence of tuberculosis has been observed in many countries; this disease is now the leading infectious cause of death world wide, being responsible for three million deaths annually (WHO, World Health Report 2000, Geneva). In some non-industrialized African countries as e.g. Malawi, there has been a dramatic increase in cases of tuberculosis as well as changes in disease pattern related to the HIV epidemic. The number of cases increased from 657 in 1986 to 2,734 in 1995, and the proportion of cases with extra-pulmonary tuberculosis rose from 11% in 1986 to 33% in 1995. Of those who were tested, 72% of adults with smear-positive pulmonary tuberculosis and 64% of children with tuberculosis were found to be HIV-seropositive [4]. Therefore infection with HIV has emerged as the

most important predisposing factor for developing overt tuberculosis in people co-infected with *Mycobacterium tuberculosis*. In these patients tuberculous pericardial effusion is a common problem and one of the major cardiac complications in the course of HIV [5] leading to cardiac tamponade in few patients [6] that has to be drained. Surprisingly our patient did not develop major signs of chronic tuberculous pericarditis except for dyspnea. Adjuvant therapy with steroids significantly decreases the risk of developing constrictive pericarditis in the first year after diagnosis of pericardial effusion [7]. Although steroids had been introduced with constrictive pericarditis already present, our patient improved clinically from this therapy.

The presented case demonstrates that the rare combination for European countries of HIV-infection and tuberculosis may be observed especially in patient from countries with high prevalence of these diseases. After diagnosis constrictive pericarditis as a known complication of tuberculous pericarditis was successfully treated by pericardiectomy to prevent cardiac tamponade. Constrictive pericarditis in an HIV-patient was only found once [8] leading to the conclusion that young patients with classical clinical signs of tuberculosis should be screened for HIV. When clinical signs of possible pericardial and cardiac involvement appear, echocardiography or CT scan should be performed to exclude constrictive pericarditis.

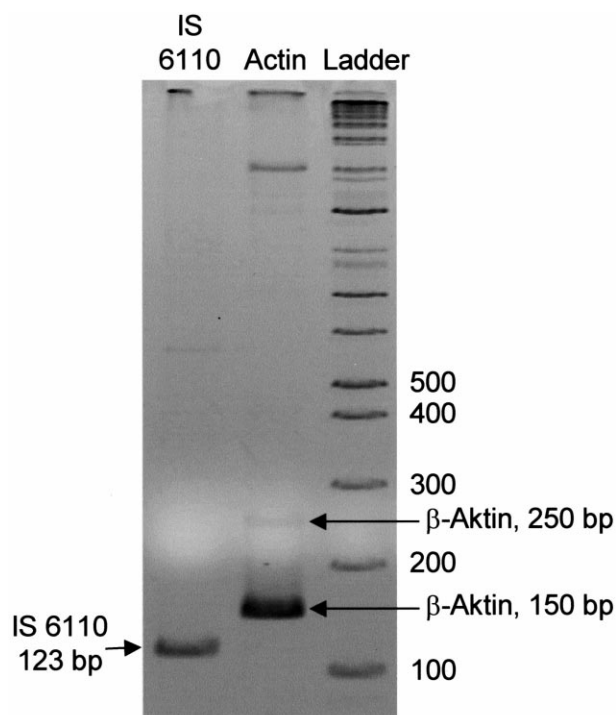


Fig. 2. Gel electrophoretic analysis of PCR amplification products, generated with primers specific for IS 6110 and for β -actin (expected product size: 150 bp and 250 bp).

References

- [1] Kirklin JW, Barrat-Boyes BG. *Cardiac Surgery*. Second Edition. New York: Churchill Livingstone, 1993. pp. 1683–1693.
- [2] DeValeria PA, Baumgartner WA, Casale AS, Greene PS, Cameron DE, Gardner TJ, Gott VL, Watkins L, Reitz BA. Current indications, risks, and outcome after pericardiectomy. *Ann Thorac Surg* 1991;52(2):219–224.
- [3] Nataf P, Cacoub P, Dorent R, Jault F, Bors V, Pavie A, Cabrol C, Gandjbakhch I. Results of subtotal pericardiectomy for constrictive pericarditis. *Eur J Cardio-thorac Surg* 1993;7(5):252–255.
- [4] Harries AD, Parry C, Nyongonya Mbewe L, Graham SM, Daley HM, Maher D, Salaniponi FM, Nyangulu DS. The pattern of tuberculosis in Queen Elizabeth Central Hospital, Blantyre, Malawi: 1986–1995. *Int J Tuberc Lung Dis* 1997;1(4):346–351.
- [5] Chen Y, Brennessel D, Walters J, Johnson M, Rosner F, Raza M. Human immunodeficiency virus-associated pericardial effusion: report of 40 cases and review of the literature. *Am Heart J* 1999;137(3):516–521.
- [6] Drona F, Suzacq C. Pericardial tuberculosis complicated with heart tamponade as presentation form of acquired immunodeficiency syndrome. *Rev Clin Esp* 1997;197(7):502–506.
- [7] Chen KY, Liaw YS, Kao HL, Yang PC, Luh KT. Constrictive pericarditis in patients with tuberculous pericarditis. *J Formos Med Assoc* 1999;98(9):599–605.
- [8] Hakim JG, Matenga JA, Siziya S. Myocardial dysfunction in human immunodeficiency virus infection: an echocardiographic study of 157 patients in hospital in Zimbabwe. *Heart* 1996;76(2):161–165.