



ELSEVIER

European Journal of Cardio-thoracic Surgery 13 (1998) 200–202

EUROPEAN JOURNAL OF
CARDIO-THORACIC
SURGERY

How to do it

Protective subpleural blanketing of intrathoracic esogastric anastomosis after esophagectomy

A. Spiliopoulos, J.H. Robert *, N. Murith, G. Chassot

Unit of thoracic surgery, Clinic of cardiovascular and thoracic surgery, University Hospital, CH-1211, Geneva 14, Switzerland

Received 27 May 1997; received in revised form 13 October 1997; accepted 19 November 1997

Abstract

Esophagectomy followed by intrathoracic anastomosis is threatened by leakage which may prove all the more serious that mediastinal contamination is extensive. In the technique presented, the esogastric anastomosis is slipped under the upper mediastinal pleura which is kept intact, after the azygos vein has been ligated and divided. This pleural 'blanket' may act as an efficient barrier against potential digestive spillage into the mediastinum. © 1998 Elsevier Science B.V. All rights reserved.

Keywords: Intrathoracic; Esogastric; Anastomosis

Surgery for intrathoracic esophageal carcinoma is seldom rewarded by lasting survivals [1]. Moreover, survival can be dramatically shortened by early postoperative complications [2], such as anastomotic leakage, which occurs in 5–10% of cases. This appears particularly dangerous [3] when it originates from an anastomosis lying unprotected in the mediastinum, as is usually the case [4] (cervical esogastric anastomoses seem to reduce the death toll of this complication [5] but are not as often resorted to).

This report describes a useful and easy-to-do adjunct to the standard Ivor–Lewis procedure which may reduce the consequences of potential anastomotic leaks: the intrathoracic esogastric anastomosis is placed in the posterior mediastinum and is blanketed under the upper mediastinal pleura, which is kept intact, and acts as an efficient barrier against potential digestive spillage.

1. Description of the procedure

The abdominal and most of the right chest steps are those of a classic Ivor–Lewis procedure [4]. Both diaphragmatic crura are divided, most of the greater omentum is excised, and a gastroplasty is performed with a GIA-55 stapler (Auto Suture, Höri, Switzerland), together with a pylorotomy (occasionally an extramucosal pyloroplasty).

A right posterolateral thoracotomy is performed in the fifth intercostal space. The azygos vein is doubly ligated and excised, and the mediastinal pleura above it gently detached from the underlying proximal esophagus using a blunt-tipped clamp (Fig. 1). This creates a 'pleural tent' under which the esogastric anastomosis will be placed (Fig. 2).

After the tumor and the esophagus have been excised, the gastric tube to which the lesser curvature is still attached is then drawn into the thorax and an end-to-side anastomosis performed with a PCEEA 28 mm stapler (Auto Suture, Höri, Switzerland). The end of the gastric tube is cut at least 2 cm above the anastomosis with a TA-60 stapler (Ethicon, Spreiten-

* Corresponding author. Tel.: +41 22 3727875; fax: +41 22 3727880.

bach, Switzerland). The anastomosis is then slipped under the pleural tent and the gastric tube fixed to the adjacent pleura with a dozen separated stitches (Fig. 2). The posterior and inferior chest drain is placed in contact with the gastroplasty and is left in place until the postoperative radio-opaque swallow has shown the anastomosis to be tight.

2. Results

This technique has been used in 43 consecutive patients with esophageal cancer over the last five years. Meglumine diatrizoate (Gastrografin®, Schering Suisse, Schlieren, Switzerland) swallow performed within ten days of surgery has revealed no anastomotic leakage, with the possible exception of a patient who suffered an extended and eventually lethal necrosis of his gastroplasty.

Two other patients died, the first of cardiac arrhythmia, the second of ARDS. Morbidity affected 17 patients, mostly due to pulmonary complications. Finally, three patients required successful endoscopic dilation of anastomotic stenoses which appeared within the first three months.

For comparison purposes, we retrieved data pertaining to 46 consecutive Ivor–Lewis operations which were performed in our department for squamous cell carcinoma of the esophagus between 1977 and 1988, i.e. prior to the use of the pleural tent. Nine patients suffered anastomotic leaks (six of them fatal), and eight patients in all died postoperatively (17%).

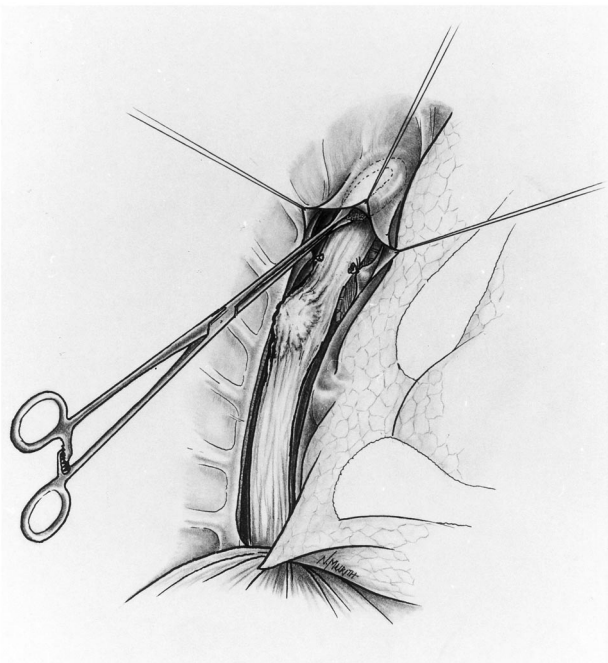


Fig. 1. Preparation of the pleural tent. The azygos vein has been doubly ligated and excised.

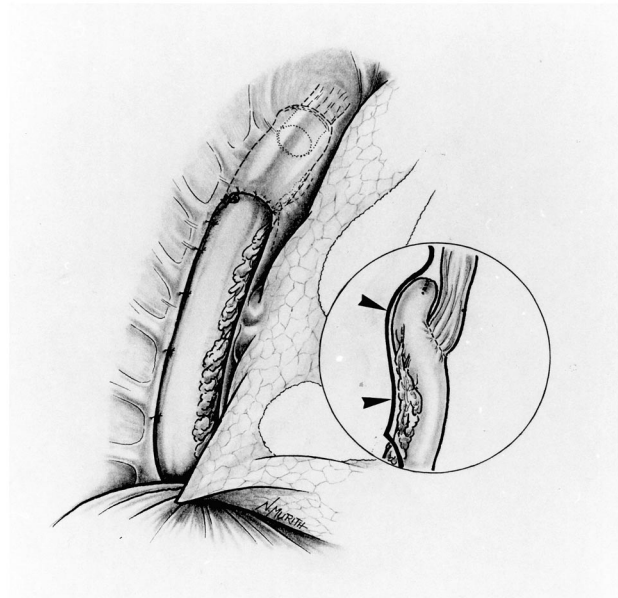


Fig. 2. Lateral view after completion of the esogastric anastomosis. Inset: anterior view; arrows = mediastinal pleura.

3. Comments

Esogastric anastomoses are threatened by leakage. Apart from omentum which is almost invariably resorted to in one way or another (to hook up the gastric tube to the mediastinum [3,6], for instance, or to help bury the gastric staple line), few if any anatomical structures of the mediastinum lend themselves to anastomotic reinforcement. Performing anastomoses at the cervical level is frequently advocated in view of the lower morbidity and mortality caused by anastomotic leaks. The artifice described herein, however, should not discourage surgeons from performing esophagectomies with intrathoracic anastomoses, provided of course the slightly more extensive excision afforded by cervical re-establishment [7] is not warranted for other reasons. In spite of the obvious absence of randomization in both series presented, use of the pleural tent described herein does seem to diminish the incidence of anastomotic leakage (nine in 46 in the first period versus only one in 43 in the second).

Finally, end-to-side esogastric anastomoses may help prevent reflux, a known complication of esophageal substitutions with stomach [8]. Although not documented by postoperative pH metries, this anti-reflux effect may be optimized by the pleural tent described herein, which keeps the anastomosis flat and maintains its valve-like configuration (Fig. 2, inset).

Acknowledgements

Many thanks to Joan and Marcel Robert and to Joan Robert-Yap for reviewing the manuscript.

References

- [1] Turnbull ADM, Ginsberg RJ. Options in the surgical treatment of esophageal carcinoma. *Chest Surg Clin North Am* 1994;4:315–29.
- [2] Infante M, Valente M, Andreani S, Catanese C, Dal Fante M, Pizetti P, Giudice G, Basilico M, Spinelli P, Ravasi G. Conservative management of esophageal leaks by transluminal endoscopic drainage of the mediastinum or pleural space. *Surgery* 1996;119:46–50.
- [3] Wilson SE, Stone R, Scully M, Ozeran L, Benfield JR. Modern management of anastomotic leak after esophagogastrectomy. *Am J Surg* 1982;144:95–101.
- [4] Bains MS. Ivor Lewis esophagectomy. *Chest Surg Clin North Am* 1995;5:515–26.
- [5] Ségol P, Salame E, Bonvalot S, Maurel J, Gignoux M. Technique actuelle des plasties gastriques en chirurgie œsophagienne. *Ann Chir Paris* 1996;50:13–20.
- [6] Fekete F, Breil P, Ronsse H, Tossen JC, Langonnet F. EEA stapler and omental graft in esophagogastrectomy. *Ann Surg* 1981;193:825–30.
- [7] Chasseray VM, Kiroff GK, Buard JL, Launois B. Cervical or thoracic anastomosis for esophagectomy for carcinoma. *Surg Gynecol Obstet* 1989;169:55–62.
- [8] Postlethwait RW. Colonic interposition for esophageal substitution. *Surg Gynecol Obstet* 1983;156:377–83.