

The role of intercostal nerve preservation in pain control after thoracotomy[†]

Olga Koop^a, Andreas Gries^a, Stefan Eckert^b, Susanne Ellermeier^b, Beatrix Hokschi^c,
Detlev Branscheid^a and Morris Beshay^{a,*}

^a Division of General Thoracic Surgery, Center of Pulmonary Diseases, Evangelic Hospital Bielefeld, Bielefeld, Germany

^b Institute of Anesthesia, Intensive Care and Pain Therapy, Evangelic Hospital Bielefeld, Bielefeld, Germany

^c Division of General Thoracic Surgery, University Hospital, Bern, Switzerland

* Corresponding author. Division of General Thoracic Surgery, Center of Pulmonary Diseases, Evangelic Hospital Bielefeld, Burgsteig 13, Bielefeld 33617, Germany. Tel: +49-521-77277499; fax: +49-521-77277498; e-mail: morris.beshay@evkb.de (M. Beshay).

Received 9 March 2012; received in revised form 14 May 2012; accepted 30 May 2012

Abstract

OBJECTIVES: Pain control after thoracotomy is an important issue that affects the outcome in thoracic surgery. Intercostal nerve preservation (ICNP) has increased interest in the outcomes of conventional thoracotomy. The current study critically evaluates the role of preservation of the intercostal nerve in early and late pain control and its benefit in patients undergoing thoracotomy.

METHODS: Data obtained prospectively between January 2006 and December 2010 by a study colleague at our division of General Thoracic Surgery were retrospectively analysed. There were 491 patients who underwent thoracotomy. Eighty-one patients were excluded from the study due to incompatible data. Patients were divided into two groups according to the intercostal nerve state: Group I consisted of patients with ICNP and Group II consisted of patients with intercostal nerve sacrifice.

RESULTS: Group I consisted of 288 patients [206 male (71%), $P < 0.001$, mean age 66 years]. Group II consisted of 122 patients [79 male (64%), $P = 0.001$, mean age 66 years]. There was less use of opiate in Group I ($P = 0.019$). Early mobilization of the patients was significantly higher in Group I ($P = 0.031$). The rate of pneumonia and re-admission to the intensive care unit was higher in Group II ($P = 0.017$ and 0.023 , respectively). The rate of pain-free patients at discharge was significantly higher in Group I ($P = 0.028$). A 2-week follow-up after hospital discharge showed parasternal hypoesthesia to be more in Group II ($P = 0.034$). Significant patient contentment in Group I was noticed ($P = 0.014$). Chronic post-thoracotomy pain (CPTP) was higher in Group II ($P = 0.016$).

CONCLUSIONS: ICNP without harvesting an intercostal muscle flap achieves excellent outcomes in controlling acute post-thoracotomy pain and CPTP. ICNP is an effective, simple method to perform, and it should be considered as standard in performing thoracotomy.

Keywords: Thoracotomy • Pain control • Post-thoracotomy pain • Intercostal nerve preservation

INTRODUCTION

It is mandatory to perform thoracotomy in most patients suffering from lung cancer or other intrathoracic diseases. However, thoracotomy is associated with considerable pain and morbidity. Unfortunately, it is one of the most painful surgical incisions currently used. The main source of pain after thoracotomy is probably from injury to the intercostal nerve [1]. During thoracotomy, the intercostal nerve is routinely damaged [2] either during performing the incision, through compression of the retractor, or sometimes during closure of the thoracotomy. Neural pain is one of the most persistent severe pains [3, 4]. Failure to inspire deeply before a forceful exhalation results in an ineffective cough, which in turn promotes retention of secretion, leading to airway closure and atelectasis. Thus, patients with limited lung

functions are usually candidates for reintubation [5]. Therefore, pain control after thoracotomy is an important issue to avoid serious postoperative complications [6]. Providing good pain control after thoracotomy would not only help to avoid many postoperative complications, but also better control the chronic postthoracotomy pain (CPTP). Chronic post-thoracotomy pain syndrome (CPTPS) is a continuous dysaesthetic burning and aching in the general area of the incision that persists at least 2 months after thoracotomy and can occur in about 60% of patients. Again, the most likely cause of CPTPS is intercostal nerve damage [3, 7]. The first reference to CPTPS was in 1944 by US Army surgeons who noted chronic intercostal pain in men who had had a thoracotomy for chest trauma during the Second World War [8]. From their neurological examinations, they concluded that intercostal nerve damage was responsible and that there was no satisfactory treatment of damaged intercostal nerves and thus CPTP. They recommended careful handling of the nerves and avoidance of any operative technique that would

[†]Presented at the 18th World Congress, World Society of Cardio-Thoracic Surgery, Kos Island, Greece, 30 April–3 May 2008, and the 16th European Conference on General Thoracic Surgery, Bologna, Italy, 8–11 June 2008.

result in unnecessary injury. Multiple incisions and approaches, as well as various methods for pain management, have been tried, with varied success [9, 10]. Harvesting an intercostal muscle flap to protect the nerve from damage was reported to be effective for pain control after thoracotomy [11, 12]. The goal of the present study was to analyse whether the intercostal nerve preservation (ICNP) without intercostal muscle flap is associated with reasonable pain control, including the experience of chronic pain.

PATIENTS AND METHODS

Study design

The inclusion criteria for the study were all patients undergoing thoracotomy between January 2006 and December 2010 at the Division of General Thoracic Surgery, who performed reliable visual analogue scale (VAS) for pain. All patients underwent thoracotomy through the same surgeon or under his supervision. Clinical records of all patients were prospectively collected using a standardized data set and definitions. A database containing detailed information on preoperative risk factors, diagnosis, operative details, pain management, postoperative course, morbidity and mortality outcomes was constructed. For the purpose of this study, patients were divided into two groups; Group I included patients with ICNP and Group II included patients with intercostal nerve sacrifice (ICNS). The data of both groups were retrospectively analysed. Preoperative characteristics, postoperative outcome, pain score, methods of pain control and rate of chronic pain were compared in both groups.

Reasons for intercostal nerve sacrifice

Since a few years previously, we have adopted ICNP during performing a thoracotomy in all patients. This was not possible in a subgroup of patients due to one or more of the following reasons: (i) massive pleural adhesions, (ii) outstanding pleuritis making identification of the nerve impossible, (iii) intercostal artery bleeding, (iv) stage III pleural empyema, (v) tumour infiltration of the thoracic wall or (vi) during extrapleural pneumonectomy.

Exclusion criteria

The following patients were excluded from the study: (i) all patients with thoracoscopic surgery, (ii) median sternotomy, (iii) emergency thoracotomy, (iv) rethoracotomy, (v) long stay at the intensive care unit (ICU), (vi) patients with preoperative thoracic pain, (vii) patients with unreliable VAS and (viii) patients who are lost to the follow-up.

Surgical techniques

Thoracotomy. After a double lumen tracheal intubation, the patient was placed in a standard lateral position, and the arm on the operated side was positioned above the head (90° flexion at the shoulder and the elbow joints). The usual thoracotomy incision was deepened in the subcutaneous fat and the lowest

fibres of the pectoralis major muscle were divided. The fibres of the serratus anterior muscle were divided backwards along its direction. The periosteum over the lower edge of the fifth rib was opened using a cautery. The periosteum was pulled down on the lower edge of the rib to protect the nerve (Fig. 1). The chest was entered under the lower edge of the rib. Through direct visualization of the nerve, this technique ensures the preservation of the nerve and the vessels (Fig. 1). A thick pad of towels was used to protect the intercostal compartment from direct retractor compression. In some patients, the cartilage of the rib was divided 2 cm away from the sterno-costal joint, to insure better exposure.

Closure of thoracotomy. Two 24F and 28F soft chest tubes were placed through a separate small incision in the sixth intercostal space. Closure of the thoracotomy was done by light adaptation of the divided periosteum and intercostal muscles to the above related rib going over the upper edge of both corresponding ribs using PDS II® loop. Muscular, subcutaneous and skin closure were done as usual.

Pain control

All our patients were considered candidates for thoracic epidural analgesia (TEA) except those with signs of active infection. Pain control through TEA was achieved through a standard protocol using Sufentanil (Sufenta epidural® 5 µg/ml injection solution, JANSSEN-CILAG GmbH, Neuss, Germany) in combination with Bupivacain local anaesthetic (Carbostesin®, 0.5%/ml, AstraZeneca, Germany). In addition, 1 g Metamizol-Natrium 1H₂O (Novalgin® Sanofi-Aventis Deutschland GmbH, Frankfurt, Germany) with normal saline solution (NaCl 0.9%) was given 3–4 times intravenously over the first 48 h postoperatively. Epidural catheters were removed between the third and the fourth postoperative day in all patients. Patients who did not receive TEA were managed either using patient controlled analgesia or Oxycodon 10 mg tablets (Oxygesic® Mundipharma, Limburg, Germany) combined with non-steroidal anti-inflammatory drugs (NSAID). All patients were provided with VAS to record their pain score on a chart from 0 to 10 (0 = no pain, 10 = unbearable pain).

Statistical analysis

SPSS for Windows was used for statistical analysis (SPSS 8.0 for Windows, SPSS Inc., Chicago, IL, USA). Univariate analysis was performed using the χ^2 test for qualitative, and the Mann-Whitney *U*-test for quantitative, data. Variables considered significant at the level of a *P*-value <0.01 on univariate analysis were subjected to multivariate, forwards, stepwise, binary, logistic regression analysis to detect their weight as predictors. Statistical significance was defined by *P*-value <0.05. Odds ratios (ORs) and their 95% confidence intervals (CIs) were added to provide an additional measure of statistical significance. Nagelkerke's pseudo *R*² values were used to provide an approximation of the goodness-of-fit of the logistic models. Intercorrelations were calculated to be able to rule out the possibility of multicollinearity between the various pain variables. Correlations were modest, ranging from 0.05 to 0.34, signalling that multicollinearity was not a problem. Analyses were done

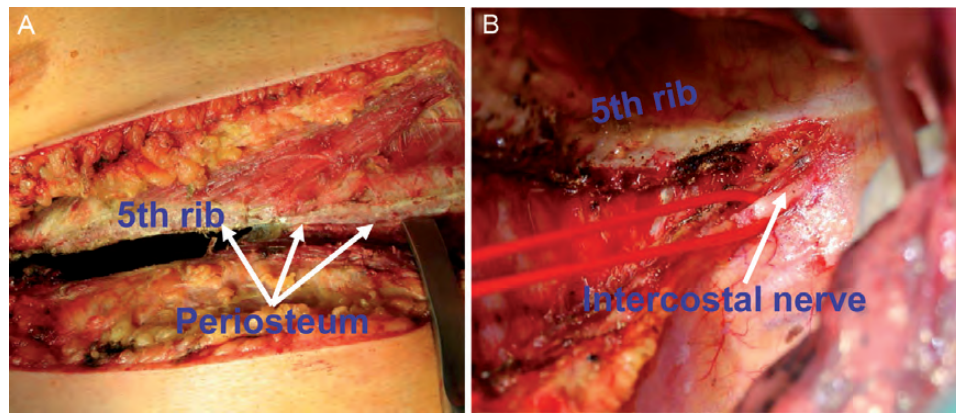


Figure 1: Antero-lateral thoracotomy (A) showing an intact intercostal nerve (B).

Table 1: Patient characteristics

Characteristics	Group I	Group II
Sex		
Male	206	79
Female	82	43
Nicotine abuse	201	98
Preoperative pulmonary function		
Vital capacity	81%	87%
Forced expiratory volume in 1 second	77%	79%
Body mass index	28	27
Race		
Caucasian	72%	72%
Asian	20%	18%
Others	8%	10%
Social status		
Married	89%	85%
Single	11%	15%
Comorbidity		
Chronic obstructive lung diseases	<i>n</i> = 70	<i>n</i> = 38
Arterial hypertension	<i>n</i> = 33	<i>n</i> = 25
Atrial fibrillation	<i>n</i> = 19	<i>n</i> = 6
Coronary heart diseases	<i>n</i> = 13	<i>n</i> = 5
Myocardial infarction	<i>n</i> = 5	<i>n</i> = 2
Diabetes mellitus	<i>n</i> = 6	<i>n</i> = 9
Chronic renal failure	<i>n</i> = 10	<i>n</i> = 4
Gastrointestinal ulcer	<i>n</i> = 3	<i>n</i> = 2
Gastrointestinal tumour	<i>n</i> = 4	<i>n</i> = 3

separately for women and men, as well as for patients from different geographical origins. Results of Caucasian males would dominate those of Asian females due to their high proportion in the data.

Results

Patient data

Between January 2006 and December 2010, 491 patients underwent thoracotomy at our institution through the same surgeon or under his supervision. Eighty-one patients were excluded from the study due to incomplete data. Patient characteristics are summarized in Table 1. Group I consisted of 288 patients [206 male (71%), $P < 0.001$, mean age 66 years] who received

Table 2: Operative procedures

Procedure	Group I	Group II
Pneumonectomy	36	13
Extended pneumonectomy	12	4
Lobectomy	123	44
Bilobectomy	18	7
Sleeve lobectomy	21	6
Segmentectomy	22	11
Wedge resection	14	4
Pleurectomy	35	26
Thymectomy	7	4
Evacuation of haemothorax	3	7
Closure of thoracic duct	1	0

thoracotomy with ICNP. Group II consisted of 122 patients [79 male (64%), $P = 0.001$, mean age 69 years] who underwent thoracotomy with ICNS. The procedures done were comparable in both groups (Table 2). Preoperative TEA was performed in 241 patients (83%) in Group I and in 94 patients (77%) in Group II.

Operative procedures

The operative procedures in all patients are summarized in Table 2. All operative procedures in both groups were performed either with the same surgeon ($n = 310$) or under his supervision ($n = 100$). There was no significant difference in the operation time in both groups (136 min in Group I vs 144 min in Group II).

Statistical difference

Perioperative events are summarized in Table 3. There was less use of opiate in Group I ($P = 0.019$) (Fig. 2). Similarly, there were less doses of non-steroidal anti-inflammatory drugs (NSAID) used in Group I, but it showed no statistical significance ($P = 0.061$). The visual analogue score was significantly higher in Group II patients ($P = 0.002$; Fig. 3). Early mobilization of the patients was significantly better in Group I ($P = 0.031$). There was less atelectasis in Group I ($P = 0.002$). The rate of pneumonia and re-admission to the ICU was higher in Group II ($P = 0.017$ and 0.023, respectively). The mean hospital stay was longer in Group

Table 3: Perioperative events

	Group I (%)	Group II (%)
Intraoperative bleeding	1	0
Blood transfusion	5	3
Pneumonia	2	11
Cardiovascular	3	6
Reoperation	1	2
Readmission to ICU	1	9
Atelectasis	1	4
Cardiovascular	3	6

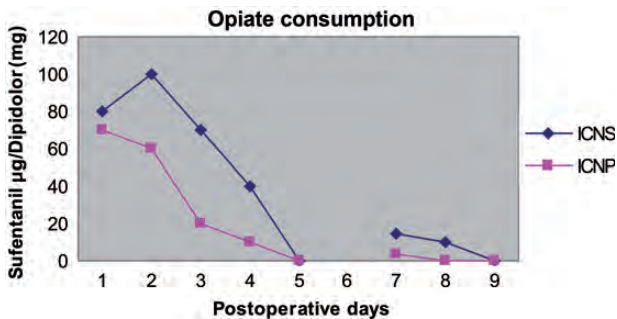


Figure 2: Time course of daily opiate (Sufentanil) consumption in combination with Bupivacain over the TEA. The extended period of observation after removal of the epidural catheter is indicated by a break in the x-axis and was covered with Piritramid and non-steroidal anti-inflammatory drugs.

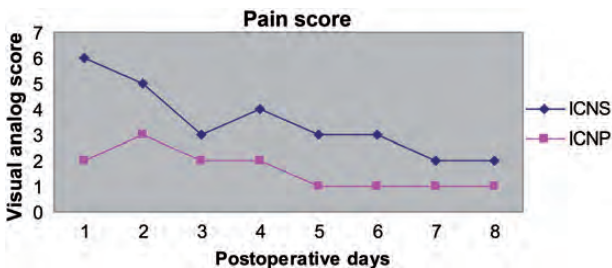


Figure 3: Postoperative mean pain score of the visual analogue scale (VAS).

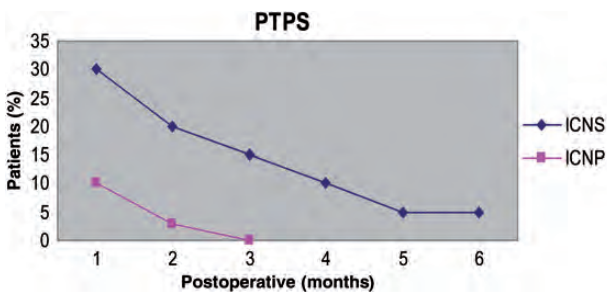


Figure 4: PTPS is higher and long-lasting in patients with ICNS.

II (11 days) than in Group I (8 days) ($P=0.037$). The rate of pain-free patients at the time of hospital discharge was significantly higher in Group I ($P=0.028$). An follow-up 2 weeks after hospital discharge showed more thoracic wall hypoesthesia in Group II ($P=0.034$). Significant patient contentment in Group I was noticed ($P=0.014$). Three- and 6-month postoperative follow-ups showed less post-thoracotomy pain syndrome (PTPS) in

Group I ($P=0.016$; Fig. 4). There was no statistical difference related co-morbidity as well as all of the following factors: (i) anterolateral compared with lateral thoracotomy OR of 0.43 (95% CI 0.11–0.72); (ii) diagnosis with OR of 0.22 (95% CI 0.14–0.42); (iii) sex or social status OR of 0.38 (95% CI 0.21–0.63); (iv) race OR of 0.86 (95% CI 0.19–0.92).

DISCUSSION

Pain after thoracotomy can be very intense and can lead to severe postoperative cardio-pulmonary complications, particularly in patients with limited lung functions [13]. Several methods of pain management are currently employed to provide relief of post-thoracotomy pain. Each of the methods, however, is associated with specific problems and side effects [14]. According to anatomical and physiological considerations, intercostal nerve damage seems to be the most important factor in PTPSs [4]. The single best approach to chronic pain is to prevent it. This can be achieved by avoiding intercostal nerve damage and achieving optimal postoperative pain control [15]. In contrast to the technique described by Cerfolio *et al.* [11], we noticed less pain in the group of patients who underwent preservation of the intercostals nerve without harvesting an intercostals muscle flap. Although harvesting an intercostals muscle flap is easy, it is time-consuming, and we do not always see an indication for the flap to be done. The same authors reported later, in 2008 [12], their experience with harvesting the intercostals muscle flap, but without distal division, and they showed a better pain control in that group. Our technique is much simpler where the intercostals muscles are released only from the lower edge of the rib and then protected with a thick pad of towels prior to the application of the retractor. The author did not report the effect of their technique on CPTP, which is an important issue. Our results suggested that this method is effective in pain control, particularly CPTP. Conventional analgesia with intravenous administration of opiate with or without NSAID often does not result in satisfactory pain relief [6, 16], and as per definition, it has no effect on CPTPS. Regional analgesia such as TEA is preferred over systemic analgesics. Although it is effective when correctly placed, is an invasive, time-consuming method. Moreover, it is not suitable for all patients and carries potential risks and limitations such as dural perforation, bleeding, infection, hypotension and bradycardia, as well as urinary retention and motor loss [17, 18]. TEA has no or less effect on controlling CPTP. Cryoanalgesia was reported to be effective on PTPC but it is associated with local atrophy of the muscle and sometimes changes of the skin sensation [14, 19]. Intercostal nerve blocks are time-consuming and often require repeated blocks. They also carry the risk of inducing pneumothorax and local anaesthetic toxicity [20]. Continuous intrapleural or intercostal local anaesthetics infusion, although avoiding the need for repeated blocks, increase the risk of toxicity [11]. Pain relief through nerve section and phenol ablation is no longer recommended due to the incidence of neuroma formation and permanent damage to the nerves with the consequence of muscle atrophy [21]. PTPS is often more difficult to manage than acute postoperative pain [14, 22]. There are many patients suffering from severe to moderate pain over a long period of time after thoracotomy, although they receive a combined analgesic and anti-epileptic drugs. For example, the incidence of long-term post-thoracotomy pain has been reported to be 80% at 3 months, 75% at 6 months and

61% at 1 year after surgery; the incidence of severe pain is 3–5% of patients [23, 24]. It has been demonstrated that posterolateral thoracotomy is behind the anterolateral thoracotomy or thoracoscopic surgery in terms of postoperative pulmonary function and walking capacity [25]. This is our experience also. Therefore, we usually perform muscle-sparing anterolateral or lateral thoracotomy whenever possible. ICNP is not an alternative method to aggressive perioperative pain management through an interdisciplinary approach, but it is an easy, feasible method, without side effects, to help control not only acute pain, but most important, to reduce the rate of CPTPS. Prospective randomized studies are needed to confirm these results.

LIMITATIONS

Although a prospective data collection was done, this study was conducted by a retrospective method of analysis, and due to the differences in the number of patients between both groups, some assumption of this work may be affected by a selection bias. The records of the patients with concomitant diseases were analysed, which showed in some cases no specifications for the degree or stage of that disease, for example CHD, COPD and emphysema. Therefore, the results in this study need to be supported with prospective randomized studies.

ACKNOWLEDGEMENTS

The authors thank the team of intensive care medicine as well as the pain management team at our hospital for their cooperation and data collection. We also thank Fritsch and Olivarez for their effort in collecting and organizing patient data.

Conflict of interest: none declared.

REFERENCES

- [1] Jara FM, Yap A, Toledo-Pereyra LH, Magilligan DJ Jr. The role of surgery in primary osteomyelitis of the chest wall. *J Thorac Cardiovasc Surg* 1979;77:147–50.
- [2] Rogers ML, Henderson L, Mahajan RP, Duffy JP. Preliminary findings in the neurophysiological assessment of intercostal nerve injury during thoracotomy. *Eur J Cardiothorac Surg* 2002;21:298–301.
- [3] d'Amours RH, Riegler FX, Little AG. Pathogenesis and management of persistent postthoracotomy pain. *Chest Surg Clin N Am* 1998;8:703–22.
- [4] Gotoda Y, Kambara N, Sakai T, Kishi Y, Kodama K, Koyama T. The morbidity, time course and predictive factors for persistent post-thoracotomy pain. *Eur J Pain* 2001;5:89–96.
- [5] Ballantyne JC, Carr DB, deFerranti S, Suarez T, Lau J, Chalmers TC *et al.* The comparative effects of postoperative analgesic therapies on pulmonary outcome: cumulative meta-analyses of randomized, controlled trials. *Anesth Analg* 1998;86:598–612.
- [6] Simpson BR, Parkhouse J, Marshall R, Lambrechts W. Extradural analgesia and the prevention of postoperative respiratory complications. *Br J Anaesth* 1961;33:628–41.
- [7] Katz J. Cryoanalgesia for postthoracotomy pain. *Ann Thorac Surg* 1989;48:5–8.
- [8] Blades B, Dugan DJ. War wounds of the chest observed at the Thoracic Surgery Centre, Walter Reed General Hospital. *J Thorac Surg* 1944;13:294–306.
- [9] Kavanagh BP, Katz J, Sandler AN. Pain control after thoracic surgery. *Anesthesiology* 1994;81:737–59.
- [10] Kaiser AM, Zollinger A, De Lorenzi D, Largiadèr F, Weder W. Prospective, randomized comparison of extrapleural versus epidural analgesia for postthoracotomy pain. *Ann Thorac Surg* 1998;66:367–72.
- [11] Cerfolio RJ, Bryant AS, Patel B, Bartolucci AA. Intercostal muscle flap reduces the pain of thoracotomy: a prospective randomized trial. *J Thorac Cardiovasc Surg* 2005;130:987–93.
- [12] Cerfolio RJ, Bryant AS, Maniscalco LM. A nondivided intercostal muscle flap further reduces pain of thoracotomy: a prospective randomized trial. *Ann Thorac Surg* 2008;85:1901–6; discussion 1906–7.
- [13] Katz J, Jackson M, Kavanagh BP, Sandler AN. Acute pain after thoracic surgery predicts long-term post-thoracotomy pain. *Clin J Pain* 1996;12:50–5.
- [14] Moorjani N, Zhao F, Tian Y, Liang C, Kaluba J, Maiwand MO. Effects of cryoanalgesia on post-thoracotomy pain and on the structure of intercostal nerves: a human prospective randomized trial and a histological study. *Eur J Cardiothorac Surg* 2001;20:502–7.
- [15] Hazelrigg SR, Cetindag IB, Fullerton J. Acute and chronic pain syndromes after thoracic surgery. *Surg Clin North Am* 2002;82:849–65.
- [16] Dahl JB, Kehlet H. Non-steroidal anti-inflammatory drugs: rationale for use in severe postoperative pain. *Br J Anaesth* 1991;66:703–12.
- [17] James EC, Kolberg BS, Iwen GW, Gellatly TA. Epidural analgesia for post-thoracotomy patients. *J Thorac Cardiovasc Surg* 1981;82:898–903.
- [18] Logas WG, El-Baz N, El-Ganzouri A, Cullen M, Staren E, Faber LP *et al.* Continuous thoracic epidural analgesia for postoperative pain relief following thoracotomy: a randomized prospective study. *Anesthesiology* 1987;67:787–91.
- [19] Evans PJD, Lloyd JW, Green CJ. Cryoanalgesia: the response to alterations in freeze cycle and temperature. *Br J Anaesth* 1981;53:1121–27.
- [20] Dettterbeck FC. Efficacy of methods of intercostal nerve blockade for pain relief after thoracotomy. *Ann Thorac Surg* 2005;80:1550–9.
- [21] Gaster RN, Davidson TM, Rand RW. Comparison of nerve regeneration rates following controlled freezing or crushing. *Arch Surg* 1971;103:378–83.
- [22] Katz J, Kavanagh BP, Sandler AN, Nierenberg H, Boylan JF, Friedlander M *et al.* Preemptive analgesia. Clinical evidence of neuroplasticity contributing to postoperative pain. *Anesthesiology* 1992;77:439–46.
- [23] Perttunen K, Tasmuth T, Kalso E. Chronic pain after thoracic surgery: a follow-up study. *Acta Anaesthesiol Scand* 1999;43:563–7.
- [24] Kalso E, Perttunen K, Kaasinen S. Pain after thoracic surgery. *Acta Anaesthesiol Scand* 1992;36:96–100.
- [25] Nomori H, Horio H, Naruke T, Suemasu K. Posterolateral thoracotomy is behind limited thoracotomy and thoracoscopic surgery in terms of postoperative pulmonary function and walking capacity. *Eur J Cardiothorac Surg* 2002;21:155–6.