

**CARDIOVASCULAR FLASHLIGHT**

doi:10.1093/eurheartj/ehs201

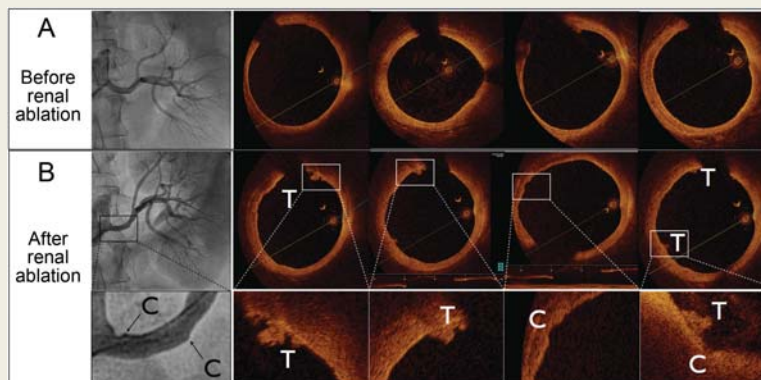
Online publish-ahead-of-print 26 September 2012

**Optical coherence tomography findings in renal denervation****Stéphane Cook\*, Jean-Jacques Goy, and Mario Togni**

Department of Cardiology, University and Hospital Fribourg, Fribourg 1708, Switzerland

\* Corresponding author. Tel: +41 26 4268130, Fax: +41 26 4268135, Email: [stephane.cook@unifr.ch](mailto:stephane.cook@unifr.ch)

Percutaneous catheter-based renal denervation is an emerging technique to treat severe and 'resistant' arterial hypertension. We report the case of a 56-year-old woman who was considered as 'resistant' hypertensive despite being treated with four antihypertensive drugs (including one diuretic) and was referred for percutaneous catheter-based renal denervation to our institution. The procedure was performed in accordance with the manufacturer's protocol, under general anaesthesia and after having given the patient 500 mg of aspirin and 5000 IU of heparin. Briefly, six, 2-min low-power RF ablations were performed within the main stem of each renal artery with the first ablation spot being located distally and subsequent ablations performed by moving proximally in the vessel lumen. Renal angiograms and optical coherence tomography (OCT) imaging (DragonFly catheter, LightLab Imaging) were performed before (*Panel A*) and after (*Panel B*) the procedure. Pre-procedural renal angiogram and OCT findings were normal. Post-procedural renal angiograms demonstrated irregularities at spots where radio-frequency energy was delivered (C, cavity). Optical coherence tomography imaging confirmed the presence of small cavities (C) and revealed small thrombi (T) attached to these areas.



Small cavities or renal artery irregularities occur immediately following the RF ablation or cryoablation. The exact nature of this phenomenon remains largely unknown. Since these cavities usually disappear early after the procedure, a vasoactive component with perilesional oedema should be considered. Endovenous heat-induced thromboses are frequently encountered after RF ablation or cryoablation of atrial fibrillation and justify a prolonged antithrombotic regimen. To date, these findings have not been reported after renal RF ablation.

As reflected by these results, OCT imaging performed after RF renal ablation identifies (i) morphological effects on the renal artery vessel wall (post-procedural cavities) and (ii) small thrombi within the renal artery. These effects need to be taken into account in patients undergoing renal ablation.