

Geometric models of the aortic and pulmonary roots: suggestions for the Ross procedure[☆]

Denis Berdajs^{*}, Gregor Zünd, Ulrich Schurr, Colette Camenisch,
Marko I. Turina, Michele Genoni

Department of Cardiovascular Surgery, University Hospital Zürich, Rämistrasse 100, 8091 Zürich, Switzerland

Received 23 April 2006; received in revised form 27 October 2006; accepted 31 October 2006; Available online 1 November 2004

Abstract

Objective: To discuss geometric factors, which may influence long-term results relating to homograft competence following the Ross procedure, we describe the 3D morphology of the pulmonary and aortic roots. **Materials:** Measurements were made on 25 human aortic and pulmonary roots. Inter-commissural distances and the heights of the sinuses were measured. For geometrical reconstruction the three commissures and their vertical projections at the root base were used as reference points. **Results:** In the pulmonary root, the three inter-commissural distances were of similar dimensions (17.9 ± 1.6 mm, 17.5 ± 1.4 mm and 18.6 ± 1.5 mm). In the aortic root, the right inter-commissural distance was greatest (18.8 ± 1.9 mm), followed by the non-coronary (17.4 ± 2.0 mm) and left coronary sinus commissures (15.2 ± 1.9 mm). The mean height of the left pulmonary sinus was greatest (20 ± 1.7 mm) followed by the anterior (17.5 ± 1.4 mm) and right pulmonary sinus (18 ± 1.66 mm). In the aortic root, the height of the right coronary sinus was the greatest (19.4 ± 1.9 mm) followed by the heights of the non-coronary (17.7 ± 1.8 mm) and left coronary sinus (17.4 ± 1.4 mm). Measured differences between parameters determine the tilt angle and direction of the root vector. The tilt angle in the pulmonary root averaged 16.26° , respectively; for the aortic roots, it was 5.47° . **Conclusions:** Herein we suggest that the left pulmonary sinus is best implanted in the position of the right coronary sinus, the anterior pulmonary in the position of the non-coronary sinus and the right pulmonary sinus in the position of the left coronary sinus. In this way, the direction of the pulmonary root vector will be parallel to that of the aortic root vector.

© 2007 European Association for Cardio-Thoracic Surgery. Published by Elsevier B.V. All rights reserved.

Keywords: Ross procedure; Aortic root; Pulmonary root; Reconstruction of the aortic root

1. Introduction

The anatomy of the heart valves were initially described by Gross and Kugel [1] and Lewis and Grant [2] in the first half of the 20th century. Both publications defined the morphology of the aortic and pulmonary valve, and were the basis for recent publications focusing on the relationship between the morphology and physiology of the arterial roots.

The present renaissance of reconstructive surgery on the aortic valve has required new perspectives on aortic root morphology. To deal with this, the term aortic root was invented, and defined as a physiological and morphological unit composed of the aortic valve and the outflow tract of the left ventricle [3]. However, given the use of the pulmonary root for the aortic valve, a method developed by Ross [4], the question of the suitability of the pulmonary valve in the aortic position has become more relevant. Recently, a great deal of

attention has been paid to every facet of this procedure. To actively affect the planning and outcome of the Ross procedure, techniques other than initially proposed subcoronary implantation have been used [5,6]. However, literature discussing the long-term results of the Ross procedure has reported significant dilatation of the pulmonary autograft [7]. With respect to this phenomenon, it has been suggested that geometric mismatch between the aortic and pulmonary roots is a major cause of valve insufficiency after this operation [8].

To clarify which geometric factors may impact homograft competence in the aortic position, we described the three-dimensional geometric anatomy of the arterial roots. To allow for better interpretation of the 3D pattern, the term root vector was invented. This mathematical parameter accurately describes both the direction and the asymmetry of the arterial roots.

2. Material and methods

The structure of the aortic and pulmonary roots was examined in 25 preserved (4% formaldehyde) normal human specimens (ages between 25 and 55 years). The preservation

[☆] Presented at the joint 17th Annual Meeting of the European Association for Cardio-thoracic Surgery and the 11th Annual Meeting of the European Society of Thoracic Surgeons, Vienna, Austria, October 12–15, 2003.

^{*} Corresponding author. Tel.: +41 255 11 11; fax: +41 255 44 49.

E-mail address: denis.berdajs@usz.ch (D. Berdajs).

procedure was undertaken under diastolic pressures, with closed leaflets, in this way the symmetric expansion of the arterial root components was achieved. In all cases, the anatomy of the heart was normal. For each root, six reference points were used to determine the geometric pattern of the root. Three commissures were defined as the highest points of the roots and were projected onto the arterial root base. The projection points are found in the inter-valvular triangles, and were defined as the basal points of the arterial roots. The linear distances between the three sinutubular and three basal points were measured. Obtained parameters were used for reconstruction of the geometric models. Both in the aortic and pulmonary roots, the inter-commissural distances and the height of the sinuses were measured. The sinus heights were defined as the distance between the sinutubular junction and the aortic root base. To define the direction of the arterial root vector, the geometric models were established by interconnecting the commissural and basal marking points. In order to estimate the tilt angle and the direction of the arterial roots, a frame of reference was introduced.

2.1. Geometric model of the aortic root

In the aortic root, the three commissures were labelled 'As', 'Rs' and 'Ls', where 's' corresponds to the sinutubular junction. The 'A' corresponds to the anterior commissure, situated between the right and left coronary sinuses. The 'R' corresponds to the right commissure between the right and non-coronary sinuses and the 'L' to the left commissure placed between the left and non-coronary sinuses. The basal points, thus being direct projections of the commissures were labelled as 'Ab', 'Rb' and 'Lb', where the 'b' corresponds to the basal position. The 'Ab' was found in the posterior inter-valvular triangle, the 'Rb' in the right and the 'Lb' in the left inter-valvular triangle (Fig. 1). The deepest point of the right sinus was chosen as the origin of the 3D frame of reference, and assigned the coordinates (0, 0, 0). The origin was positioned in the middle of the 'AbRb' stretch (Fig. 1). To estimate the tilt angle of the aortic root, the Δh and the height (Vs) of the sinutubular 'AsRsLs' were calculated (Fig. 1). Δh was defined as the difference between the height of the left sinus (hl) and the right inter-valvular triangle (ho) (Fig. 1). One can see that the heights of the sinutubular (' Δ AsRsLs') and basal triangles (' Δ AbRbLb'), Vs (sinutubular) and Vb (basal), are positioned in the positive quadrant of the x–y plane. Projecting these two parameters onto each other, a right-angle triangle is obtained. This triangle is also positioned in the x–y plane and is defined by the aforementioned heights and Δh . The angle in front of Δh is the tilt angle between the sinutubular and basal planes in the aortic root and thus may be considered as the tilt angle of the root. This parameter was calculated using the rules applied to a right-angle triangle (Fig. 1).

2.2. Geometric model of the pulmonary root

In the pulmonary root, the three commissures were referred to as 'Ls', 'Rs' and 'Ps', where 'L' corresponds to the left commissure positioned between the left and

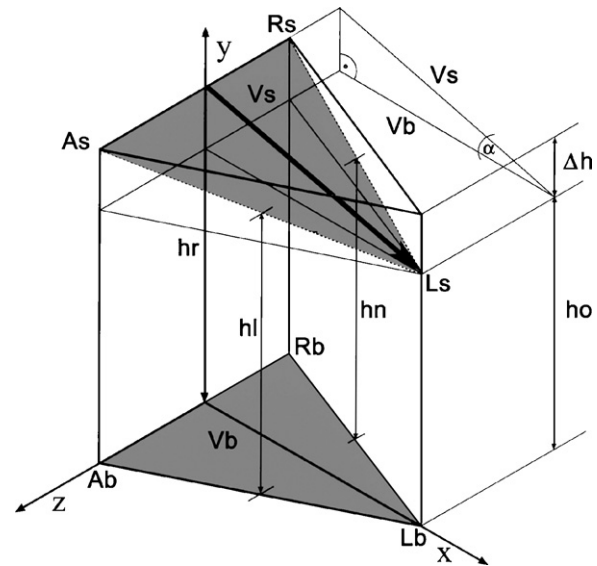


Fig. 1. Geometric model of the aortic root. The 'AsRsLs' triangle is positioned in the sinutubular junction. The three edges correspond to the anterior (As), right (Rs) and left (Ls) commissures. The triangle at the aortic root base is marked by the 'AbRbLb' triangle, the basal points correspond to the vertical projection of the three commissures into the root base. The 'hr' corresponds to the height measured in the right sinus; 'hl' and 'hn' to the heights obtained in the left and non-coronary sinuses, respectively. The 'ho' is the height of the left inter-valvular triangle. The ' Δh ' is calculated as the difference between 'hr' and 'ho'. The 'Vs' is height of the 'AsRsLs' triangle. The tilt angle between the basal and sinutubular triangles corresponds to the ' α ' angle. It was calculated according to the rules of a right-angle triangle. The tilt angle of the aortic root is 5.47°.

anterior sinuses. The 'R' to the right commissure and 'P' to the posterior commissure positioned between the left and right pulmonary sinuses. The basal points found in the inter-valvular triangles, were labelled 'Lb', 'Rb' and 'Pb'. The 'Lb' was found in the left inter-valvular triangle, 'Rb' in the right and 'Pb' in the posterior inter-valvular triangle (Fig. 2). The deepest point of the left pulmonary sinus was chosen as the origin of the 3D frame of reference, with the coordinates (0, 0, 0). This point was positioned in the middle of the 'PbLb' stretch (Fig. 1). To estimate the tilt angle of the pulmonary root, the Δh and the height (Vs) of the sinutubular triangle ('PsLsRs') were calculated (Fig. 1). Δh height was defined as the difference between the height of the left sinus (hl) and the right inter-valvular triangle (ho) (Fig. 2). One can see that the heights, Vs and Vb, are positioned in the positive quadrant of the x–y plane. Projecting these two parameters onto each other, a right-angle triangle is obtained. This triangle is also positioned in the x–y plane, and is defined by the aforementioned heights and Δh . The angle in front of Δh is the tilt angle of the pulmonary root, which was calculated by using the rules applied to a right-angle triangle (Fig. 2).

2.3. Statistical analysis of data

Non-parametric analysis of variance was conducted on the inter-commissural distances, the sinus volumes and the sinus heights. Mean values and standard deviations were obtained.

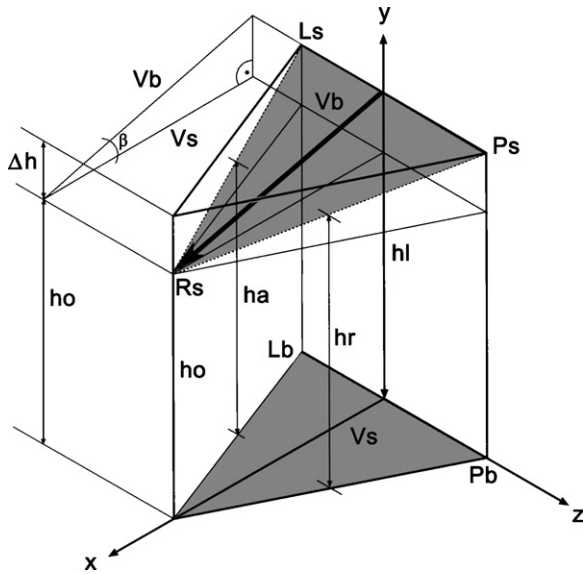


Fig. 2. Geometric model of the pulmonary root. The 'PsLsRs' triangle is found at the level of the sinutubular junction and is defined by the posterior (Ps), left (Rs) and right (Rs) commissures. The triangle at the aortic root base is marked by the 'PbLbRb' triangle, where the basal points correspond to projection of the commissures onto the inter-valvular triangles. By interconnecting the aforementioned points, a 3D model of the pulmonary root is obtained. 'hl' corresponds to the height measured in the left sinus; 'ha' and 'hr' to the heights obtained in the anterior and in the right pulmonary sinuses, respectively. 'ho' is the distance between 'Rs' and 'Rb'. 'Δh' is calculated as the difference between 'hl' and 'ho'. 'Vs' is the height of the 'PsLsRs' triangle, also calculated. One can observe that the tilt angle between the basal and sinutubular triangles corresponds to the 'β' angle in the triangle, which is defined by 'Δh' and 'Vs'. The 'β' angle is calculated according to the rules of a right-angle triangle. The tilt angle of the pulmonary root is 16.26°.

3. Results

3.1. Geometric model of the aortic root

The inter-commissural distances in the aortic root were seen as; in the right coronary sinus 18.8 mm (SD 1.9), in the non-coronary sinus 17.4 mm (SD 2.0) and in the left coronary sinus 15.2 mm (SD 1.9) (Table 1). The mean heights of the right, non-coronary and left coronary sinuses were 19.4 mm (SD 1.9), 17.7 mm (SD 1.8) and 17.4 mm (SD 1.4), respectively (Table 1). The volumes of each sinus were measured directly and showed the following pattern: the volume of right coronary sinus was 1.6 ml (SD 0.3), of the non-coronary sinus 1.33 ml (SD 0.27) and of the left coronary sinus 1.04 ml (SD 0.23) (Table 1). The angle of the aortic root, which is defined by Vs, Vb and Δh, was placed in the x–y

plane (Fig. 1). Using the current mathematical rules for right-angle triangles, the angle between the sinutubular junction and aortic root base was calculated, using the following equation: $\Delta h = Vs \sin \alpha$, where Vs defines the height of the sinutubular triangle ('LsPsRs') (Fig. 1). After rearrangement, the tilt angle of the aortic root was 5.47°.

3.2. Geometric model of the pulmonary root

The mean heights of the left, anterior and right sinuses were 20 mm (SD 1.7), 18 mm (1.67) and 18 mm (1.66), respectively (Table 1). The inter-commissural distances were seen to be; left sinus 17.9 mm (SD 1.62), anterior sinus 17.5 mm (SD 1.36) and right pulmonary sinus 18.6 mm (SD 1.47) (Table 1). The angle of the pulmonary root, defined by Vs, Vb and Δh, was placed in the x–y plane (Fig. 2). By means of the current mathematical rules for right-angle triangles, the tilt angle of the root was calculated using the following equation: $\Delta h = Vs \sin \beta$, where Vs defines the height of the 'PsLsRs' triangle (Fig. 2). After rearrangement, the tilt angle of the pulmonary root was 16.26°.

3.3. Definition of the vectors

According to the mathematical definition of the vector in the Euclidian space, the geometrical models of the aortic and pulmonary roots were defined as geometrical vectors. This was described as quantity being positioned in the three-dimensional space having a direction, magnitude, beginning and endpoint. Vector was depicted as an arrow having its beginning point, end point and tilt angle. In the aortic root the vector was positioned in the sinutubular plane. The origin was positioned in the middle of the 'AsBs' stretch and its end point was the left commissure. The direction in the x–y plane was defined by the tilt angle between the sinutubular and basal plane. Analogue to this definition of the aortic root the direction and the position of the pulmonary root vector was defined. Its origin was found in the middle of the 'LsPs' stretch. The arrow terminated in the right commissure.

4. Discussion

Aortic valve replacement using a pulmonary homograft is a complex procedure which providing very good functional results in most patients. Negligible valve-related morbidity, freedom from anticoagulation, and the ability to accommodate growth make it a valid therapeutic modality in infants and children with aortic root disease. Furthermore,

Table 1
Comparison of data measured in the aortic and pulmonary root

	Pulmonary root			Aortic root		
	LPS	APS	RPS	RCS	NCS	LCS
Height of the sinuses (mm)	20 ± 1.7	18 ± 1.67	18 ± 1.66	19.4 ± 1.9	17.7 ± 1.8	17.4 ± 1.4
Inter-commissural distances (mm)	17.9 ± 1.6	17.5 ± 1.4	18.6 ± 1.5	18.8 ± 1.9	17.4 ± 2.0	15.2 ± 1.9
Volume of the sinuses (ml)	1.76 ± 0.2	1.61 ± 0.31	1.44 ± 0.3	1.6 ± 0.3	1.33 ± 0.27	1.04 ± 0.23

The mean values and the standard deviations were obtained. The dimensions of the sinus within the aortic and pulmonary roots were statistically different ($p < 0.005$), as were the parameters compared between the aortic and pulmonary sinuses ($p < 0.005$).

LPS: left pulmonary sinus; APS: anterior pulmonary sinus; RPS: right pulmonary sinus; RCS: right coronary sinus; LCS: left coronary sinus; NCS: non-coronary sinus.

because of the excellent quality of life associated with the Ross procedure, the procedure is increasingly being performed in adults. However, as there are several valid treatment options in adults, close scrutiny of any potential adverse effects of the Ross procedure within this age group is mandatory. It has become apparent that pulmonary homograft insufficiency may be a relatively common problem [9]. Furthermore, reports of early and late dilatation of the autograft are gathering [10,11].

Dilatation of the pulmonary autograft is the most common complication after a Ross procedure. According to published literature, this affects nearly one-third of patients [12,13]. David et al. [8] postulated that dilatation of the pulmonary autograft occurs because of a mismatch between the diameters of the annulus and the sinutubular junction of the aortic and pulmonary roots. This especially was true among patients with bicuspid or other congenital malformations of the aortic root. However, even addressing this discrepancy in diameter, via surgical corrections at the annulus and sinutubular junction, has not prevented late dilatation of the homograft. Furthermore, it was conjectured that geometric mismatch between the aortic and pulmonary roots causes aortic insufficiency in patients with tricuspid aortic valves. Despite there being no morphological or physiological data, the authors believed that spatial geometry may influence the dilatation of the neo-aortic root, they were suggesting positioning the left pulmonary sinus into the position of the left coronary sinus as most functional implantation [8]. In recent literature, no evidence of superior haemodynamic performance of homografts associated with implantation of the left pulmonary sinus into the position of the left coronary sinus has been found. Consequently, it seems that neither the suggested orientation nor the plication of the annulus impacts recently the late dilatation of the neo-aortic root. Thus, we believe that the geometrical orientation of the aortic and pulmonary root sinuses may recently influence the function of the pulmonary root.

In the study herein, the three-dimensional structures of the aortic and pulmonary roots are described in detail.

The 3D structure of each root was approached as a geometric model; and, in order to define the direction of the defined 3D models, they were adjusted into a 3D frame of reference. The direction of the roots was defined by the asymmetry of the sinus. This natural asymmetrical structure was mathematically described with root vector being positioned between the highest and deepest points of the sinutubular junction. In the case of the aortic root, the vector runs from the highest point of the right coronary sinus towards the left commissure, consequently the direction may be described as left-posterior (Fig. 3). In the case of the pulmonary root, the root vector also begins in the highest point of the left coronary sinus, but it runs towards the right pulmonary commissure, in contrast to the aortic root, so that the vector exhibits a right-anterior position (Fig. 3). Considering this situation (Fig. 3), one can note the directions of the aortic and pulmonary root vectors are opposite. Furthermore, positioning the two geometric models into a common frame of reference, it was observed that the two vectors are parallel. Based upon our morphological data, we believe it is advisable to implant the pulmonary homograft in such a way as to match the natural geometric asymmetry of the pulmonary

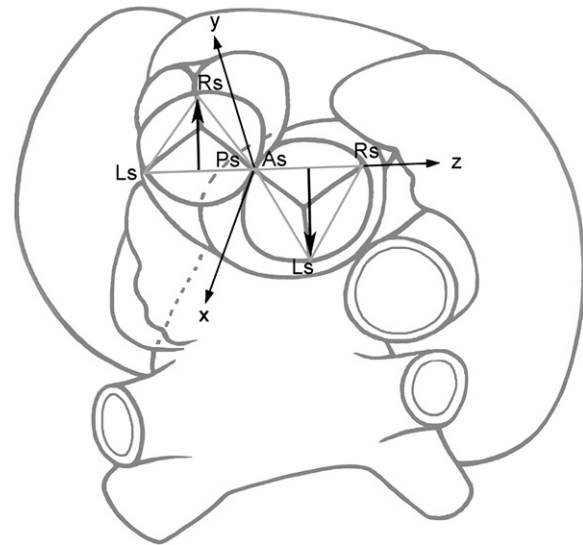


Fig. 3. Superior view of the aortic and pulmonary roots. Only the sinutubular triangles in the aortic ('AsRsLs') and pulmonary roots ('PsLsRs') are indicated. The root vectors were positioned parallel to each other in opposite directions. The common frame of reference was positioned with its origin slightly between the posterior commissure of the pulmonary and the anterior commissure of the aortic roots. The x-axis runs towards the left atrium, the z-axis towards the right auricle and the y-axis is perpendicular to the 'x-z' plane. Note that the stretch 'LsPs' of the pulmonary root and the stretch 'AsRs' of the aortic root are positioned along the z-axis. Note in this orientation, the directions of the root vectors are opposite, but parallel.

root to the asymmetry of the aortic root. Consequently, one must implant the largest pulmonary sinus (the left pulmonary sinus) in the position of the largest sinus of the aortic root (the right coronary sinus); the anterior pulmonary sinus should be located in the position of the non-coronary sinus; and the smallest sinus of the pulmonary root, that is, the right pulmonary sinus, should be in the position of the smallest sinus of the aortic root, the left coronary sinus. Aligning the graft in this manner, the direction and position of the pulmonary root vector in the aortic position will be congruent with the position and direction of the native aortic root vector.

The data herein was achieved by measurements performed on the preserved arterial roots. The procedure was performed under diastolic pressure condition with closed leaflets. It is a fact that the preservation procedure changes the native anatomy of the root causing a symmetrical decreasing of all parameters; however, the process preserves the geometrical relations between the measured components. In this study, for reconstruction of the 3D models only a comparison of the measured static parameters was considered. It is true that during the cardiac cycle the aortic and pulmonary roots show dynamical changes; however, we believe that the systolic expansion and diastolic relaxation do not influence the relative comparison of the parameters. One should be aware, discussing the long-term results of the Ross procedure, both geometrical and haemodynamical factors must be taken into the account. Reviewing the relevant literature, no previous studies were found to include both the factors and their influence on the long-term results. In this study, we have been able to give some assumptions regarding the role of the well-described asymmetry of both roots on the outcome of the Ross procedure.

However, our limitations are very clear, approaching the Ross procedure in this way we were not able to prove the impact of the recommended orientation on the clinical outcomes. To achieve appropriate imputes regarding the clinical importance of our suggestion, we believe further clinical and haemodynamical studies must be carried out.

References

- [1] Gross L, Kugel MA. Topographic anatomy of the valves in the human heart. *Am J Pathol* 1931;7:445–73.
- [2] Lewis T, Grant RT. Observations relating to the subacute infective endocarditis. *Heart* 1923;10:21–99.
- [3] Robicsek F. Leonardo Da Vinci and the sinuses of valsava. *Ann Thorac Surg* 1991;52:328–35.
- [4] Ross DN. Replacement of aortic and mitral valves with a pulmonary autograft. *Lancet* 1967;2:956–8.
- [5] Elkins RC, Knott-Craig CJ, Ward KE, Lane MM. The Ross operation in children: 10-year experience. *Ann Thorac Surg* 1998;65:496–502.
- [6] Simon-Kupilik N, Bialy J, Moidl R, Kasimir MT, Mittlböck M, Seebacher G, Wolner E, Simon P. Dilatation of the autograft root after the Ross operation. *Eur J Cardiothorac Surg* 2002;21(3):470–3.
- [7] David TE, Omran A, Ivanov J, Armstrong S, de Sa M, Sonnenberg B, Webb G. Dilatation of the pulmonary autograft after the Ross procedure. *J Thoracic Cardiovascular Surg* 2000;119:210–20.
- [8] David TE, Omran A, Webb G, Rakowski H, Armstrong S, Sun Z. Geometrical mismatch of the aortic and pulmonary roots causes aortic insufficiency after the Ross procedure. *J Thorac Cardiovascular Surg* 1996;112:1231–9.
- [9] Carr-White GS, Kilner PJ, Hon JFK, Rutledge T, Edwards S, Burman ED, Pennell DJ, Yacoub MH. Incidence, location, pathology and significance of pulmonary homograft stenosis after the Ross operation. *Circulation* 2001;104(Suppl. 1):I-16–20.
- [10] Hokken RB, Bogers AJJ, Taams MA, Schiks-Berghout MB, van Herwerden LA, Roelandt JR, Bos E. Does the pulmonary autograft in the aortic position in adults increase in diameter? An echocardiographic study. *J Thorac Cardiovasc Surg* 1997;113(4):667–74.
- [11] Chambers JC, Somerville J, Stone S, Ross DN. Pulmonary autograft procedure for valve disease: long-term results of the pioneer series. *Circulation* 1997;96:2206–14.
- [12] Luciani GB, Casali G, Favaro A, Prioli MA, Barozzi L, Santini F, Mazzucco A. Fate of the aortic root late after Ross operation. *Circulation* 2003;108(Suppl. II):II-61–7.
- [13] Simon-Kupilik N, Bialy J, Moidl R, Kasimir MT, Mittlböck M, Seebacher G, Wolner E, Simon P. Dilatation of the pulmonary autograft root after the Ross operation. *Eur J Cardiothorac Surg* 2002;21:470–3.