

vivo and also the fragility of the organism during processing in the laboratory.

This is the first case report of disseminated *S. vasiformis* infection with endocardial and myocardial involvement confirmed by postmortem examination.

**Tom Solano,¹ Bridget Atkins,² Evanthia Tambosis,²
Stephen Mann,³ and Thomas Gottlieb²**

Departments of ¹Intensive Care, ²Infectious Diseases and Microbiology, and ³Anatomical Pathology, Concord Hospital, Sydney, Australia

Prevalence and Clinical Significance of Splenomegaly in Asymptomatic Human Immunodeficiency Virus Type 1–Infected Adults

In a prospective cohort study of 70 consecutive, asymptomatic human immunodeficiency virus type 1 (HIV-1)–infected adults, splenomegaly was found by physical examination in 23% of patients and by ultrasound in 66%. Patients with concomitant liver disease had a higher prevalence of splenomegaly (RR 1.84; $P < .001$). During a 1-year follow-up of 66 patients, splenomegaly at enrollment was not predictive of any clinical event, and splenomegaly was not associated with a higher risk of developing AIDS during a median follow-up of 6.1 years.

Splenomegaly is a frequent finding among HIV-infected adults [1, 2]. It has been found in up to 70% in a postmortem study [3]. However, little is known about the prevalence and clinical significance of this finding in asymptomatic patients. Previous studies have often been biased by referral and included patients in different stages of HIV infection [1, 4–6]. Therefore, we conducted a prospective observational study among asymptomatic HIV-1–infected outpatients.

Our outpatient clinic is one of the 7 centers of the Swiss HIV Cohort Study (SHCS). Within this community-based cohort study, HIV-infected individuals aged ≥ 16 years are followed at 6-month intervals according to standardized criteria that have been described elsewhere [7].

Patients were eligible for the present study if they were in Centers for Disease Control and Prevention (CDC) stage A [8] or if they had thrombocytopenia as the only HIV-associated clinical manifestation. During a 4-month period in 1993, all

References

- Holland J. Emerging zygomycoses of humans: *Saksenaea vasiformis* and *Apo-physomyces elegans*. *Curr Top Med Mycol* **1997**;8:27–34.
- Ellis DH, Kaminski GW. Laboratory identification of *Saksenaea vasiformis*: a rare cause of zygomycosis in Australia. *Sabouraudia* **1985**;23:137–40.
- Wilson M, Robson J, Pyke CM, McCormack JG. *Saksenaea vasiformis* breast abscess related to a gardening injury. *Aust N Z J Med* **1998**;28:845–6.
- Torell J, Cooper BH, Helgeson NG. Disseminated *Saksenaea vasiformis* infection. *Am J Clin Pathol* **1981**;76:116–21.
- Hay RJ, Campbell CK, Marshall WM, Rees BI, Pincott J. Disseminated zygomycosis (mucormycosis) caused by *Saksenaea vasiformis*. *J Infect* **1983**;7:162–5.

consecutive patients in CDC stage A underwent ultrasonographic evaluation of spleen size. Sonography was performed only once. Seventy-six patients were eligible, of which 70 were analyzed (5 did not consent to the examination, and 1 patient had had a splenectomy).

Patients underwent physical examination by their physicians (who were aware of the study) and underwent ultrasonography the same day. Sonography was always done by the same examiner, who was not aware of the results of the clinical examination. Clinical splenomegaly was present if the spleen was palpable. Splenomegaly was defined by ultrasound as a spleen with a long axis ≥ 120 mm [9]. Sociodemographic data and laboratory values were extracted from the SHCS database and from patients' charts. Clinical events were recorded prospectively for 1 year after the examination to evaluate the clinical importance of splenomegaly.

Of the 70 patients in our cohort, 50 (71%) were male and 20 were female; the median age was 31 years (range, 21–51 years). With respect to the mode of HIV-1 transmission, 26 patients were men who have sex with men, 22 were heterosexual, and 20 were injection drug users; 2 were infected by other modes of transmission. Peripheral lymphadenopathy was found in 40 patients (58%). The median CD4 cell count was 417 cells/ μ L (range, 35–890 cells/ μ L). Seven patients (10%) had platelet counts $< 125 \times 10^9$ cells/L. Twenty-nine patients (41%) had liver disease, defined as positive hepatitis B surface antigen, positive hepatitis C serology, or alanine aminotransferase (ALT) levels above the upper normal limit; 24 (83%) of those 29 had positive serology for hepatitis C.

Statistical analyses included single table analysis, unpaired *t* test and univariate regression analysis, Kaplan-Meier estimates, and Cox's regression analysis; all of these were performed using Epi Info 6 (CDC; Atlanta, GA) and Stata 6 software (Stata, College Station, TX).

Splenomegaly was found in 14 patients (23%) by clinical examination and in 46 (66%) by ultrasound examination (figure 1). Median spleen size was 125 mm (range, 92–197 mm). In 2 of the 14 patients with clinical splenomegaly, this finding was not confirmed by ultrasound. An enlarged spleen was suspected

Informed consent was obtained from all patients.

Grant support: This study was financed by the Swiss Federal Office of Public Health (3600.010.1).

Reprints or correspondence: Dr. H. Furrer, Division of Infectious Diseases, University Hospital, Inselspital PKT2 B, CH-3010 Bern, Switzerland (hansjakob.furrer@insel.ch).

Clinical Infectious Diseases 2000;30:943–5

© 2000 by the Infectious Diseases Society of America. All rights reserved.
1058-4838/2000/3006-0022\$03.00

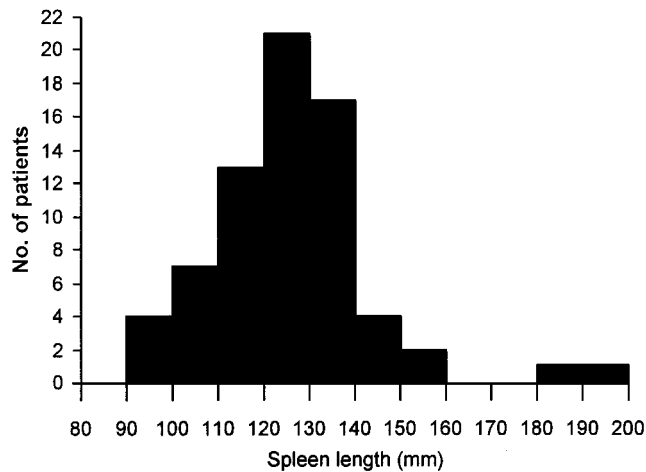


Figure 1. Histogram of long spleen axis (spleen length) measured by ultrasound in 70 consecutive patients who were infected with HIV but were asymptomatic.

clinically only in 12 (26%) of 46 patients with splenomegaly by using ultrasound.

Spleen size in patients without palpable spleens was significantly smaller than that in patients with palpable spleens (mean spleen length \pm SD, 120 \pm 13 mm vs. 140 \pm 25 mm; $P = .001$). A box plot of the spleen size for the two groups is shown in figure 2.

The prevalence of splenomegaly was higher in patients with liver disease (90%) than in those without it (48%; RR, 1.84; 95% CI, 1.3–2.6; $P < .001$). Among patients with a positive serology for hepatitis C, splenomegaly was found in 22 (92%) of 24. Presence of peripheral lymphadenopathy was not associated with splenomegaly (RR, 0.9; 95% CI, 0.6–1.3). Of the 7 patients with thrombocytopenia, 4 had splenomegaly (RR, 0.86; 95% CI, 0.4–1.7). There was no correlation between CD4 count and spleen size ($r = .03$; $P = .8$).

Four participants were lost to follow-up during the following 12 months. Of the remaining 66 patients (94%), 14 had progression of HIV-1 infection according to CDC criteria. Twelve patients had a stage B event (candida stomatitis, 7 patients; multisegmental herpes zoster, 2; oral hairy leukoplakia, 2; and unexplained weight loss, 1). Two participants progressed to stage C (1 had recurrent episodes of bacterial pneumonia and 1 had *Pneumocystis carinii* pneumonia).

Patients with progression of HIV-infection during the 1-year follow-up did not have a higher prevalence of splenomegaly (RR, 1.1; 95% CI, 0.72–1.55; $P = 1.0$), but had lower CD4 cell counts (median 325 cells/ μ L vs. 460 cells/ μ L, $P = .01$) at study entry.

Sixty-six patients were followed further within the framework of the SHCS, and AIDS-defining events and death were recorded. Data were assessed at the last follow-up visit at our

center. Median follow-up was 74 months (interquartile range, 60–76 months). Seven patients died during the extended follow-up; 6 of those 7 had had splenomegaly at baseline. The causes of death were AIDS related (4 patients), suicide (1), narcotic drug overdose (1), and subarachnoid hemorrhage (1). Fourteen patients progressed to AIDS, of whom 12 had had splenomegaly at baseline. One patient, whose spleen was 130 mm long at enrollment, had a non-Hodgkin's lymphoma diagnosed 29 months later.

Kaplan-Meier estimates for AIDS-free survival did not show a significant difference between patients with or without splenomegaly at baseline (log rank test, $P = .12$). In a Cox's regression analysis that included baseline CD4 count, age, and splenomegaly, the hazard ratio for patients with splenomegaly for developing AIDS was not significantly different than it was for patients without splenomegaly at baseline (hazard ratio 3.0; 95% CI, 0.66–13.5; $P = .15$).

In summary, we found splenomegaly (defined as a spleen with a long axis ≥ 120 mm) in two-thirds of consecutive asymptomatic HIV-1 infected patients in our study. The sociodemographic characteristics of study participants were similar to those of asymptomatic HIV-infected patients seen in our clinic, and to the entire asymptomatic SHCS population, as well as to the asymptomatic HIV-1-infected patients in Switzerland [10]. Thus, our study sample appeared to be representative of asymptomatic HIV-1-infected patients in Switzerland and less biased by referral than were previous study populations that addressed the frequency of splenomegaly in HIV-1-infected adults.

Our findings confirm the observations made by others [11], that clinical examination alone is a poorly sensitive, but reasonably specific method for detection of moderate splenomeg-

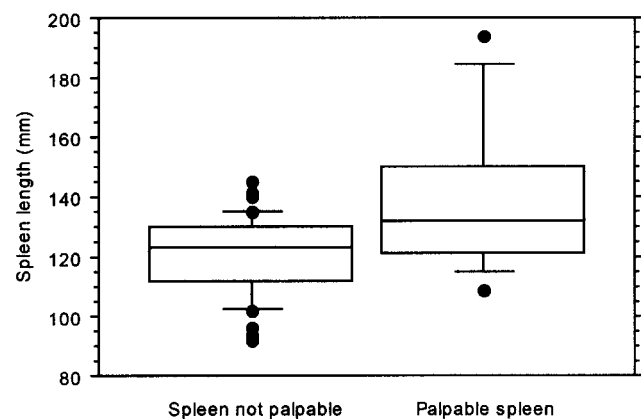


Figure 2. Box plot of measurements of the long axis of the spleen in patients without (left) and with (right) palpable spleen. Horizontal lines indicate the 25th, 50th (median), and 75 percentiles; vertical brackets indicate the 10th and 90th percentiles, dots (●) indicate values below the 10th or above the 90th percentiles.

aly [12]. The prevalence of sonographic splenomegaly was higher in patients with liver disease, which was mostly due to chronic hepatitis C (HCV) infection in our population. Chronic HCV infection without HIV infection can lead to isolated splenomegaly in about one-fourth of the patients [13], whereas it was a nearly universal feature in our patients who were co-infected with HIV-1 and HCV. In contrast, splenomegaly was not associated with peripheral lymphadenopathy or with grade of immunodeficiency, as measured by CD4 cell counts. Thrombocytopenia was not definitively associated with splenomegaly, but the number of patients with low platelet counts in our study was too small to draw definitive conclusions.

To date, the clinical importance of splenomegaly in asymptomatic HIV-1-infected individuals has remained unclear. We were able to follow >90% of the patients for at least 1 year. Splenomegaly was not associated with progression of HIV infection. Furthermore, during a 1-year follow-up period no patient developed HIV-associated opportunistic infections or malignancies or other non-HIV-related diseases known to be typically preceded by or associated with splenomegaly.

A great concern when splenomegaly is found is that it might be non-Hodgkin's lymphoma. One patient in our series developed this disease 29 months after enrollment in the study. It is unlikely that the moderately enlarged spleen at enrollment was an early manifestation of this malignant disease. On the basis of our data, it does not seem warranted to perform invasive studies to rule out non-Hodgkin's lymphoma in otherwise asymptomatic HIV-infected persons with splenomegaly.

During a median follow-up of >6 years, progression to AIDS was not associated with splenomegaly at baseline. Plasma HIV RNA levels were not available at baseline. Therefore, we could not analyze an association of splenomegaly with the most important prognostic marker [14] and could not correct for it in our Cox's regression analysis. Our population was too small to find even moderate associations between splenomegaly and progression to AIDS. Furthermore, the follow-up was extended into a period where combination antiretroviral therapies became available and these agents had a major influence on morbidity and mortality in HIV-infected persons [15]. Therefore, we were not able to study the natural history of HIV infection with regard to splenomegaly in our cohort.

Extensive evaluation, beyond a search for hepatitis C infection, is not warranted in asymptomatic HIV-1-infected individuals with an incidental finding of splenomegaly. Conversely, given the high prevalence of splenomegaly in asymptomatic HIV-infected adults, HIV infection should be part of the differential diagnosis of otherwise unexplained splenomegaly in adults with unknown serostatus of HIV infection.

Acknowledgements

Members of the Swiss HIV Cohort Study are as follows: M. Battagay (Co-Chairman of the Scientific Board), E. Bernasconi, Ph. Bürgisser,

M. Egger, P. Erb, W. Fierz, M. Flepp (Chairman of the Group Clinics), P. Francioli (President), H. Furrer, P. Grob, B. Hirschel (Chairman of the Scientific Board), B. Ledergerber, L. Matter (Chairman of the Group Laboratories), A. Meynard, M. Opravil, F. Paccaud, G. Pantaleo, L. Perrin, W. Pichler, J.-C. Piffaretti, M. Rickenbach (Head of the Data Center), P. Sudre, J. Schupbach, A. Telenti, P. Vernazza, and R. Weber.

Hansjakob Furrer, for the Swiss HIV Cohort Study
*Division of Infectious Diseases, University Hospital,
Bern, Switzerland*

References

- Smith FJ, Mathieson JR, Cooperberg PL. Abdominal abnormalities in AIDS: detection at US in a large population. *Radiology* **1994**;192:691-5.
- Luthen R, Niederau C. Sonographische befunde bei HIV-patienten. *Bildgebung* **1995**;62:271-80.
- Ansovini R, Barbolini G, Migaldi M, Botticelli L, De Rienzo B. Splenomegalia da AIDS e problematiche siderotiche connesse. *Pathologica* **1998**;90:133-9.
- Radin R. HIV infection: analysis in 259 consecutive patients with abnormal abdominal CT findings. *Radiology* **1995**;197:712-22.
- Erdozain JC, Gonzalez GM, Pintado V, et al. Ecografia abdominal en el paciente con infeccion por el virus de la inmunodeficiencia humana (VIH): utilidad diagnostica en la valoracion de la patologia medico-quirurgica asociada. *Ann Med Interna* **1995**;12:115-21.
- Zambetti EF, Haramati LB, Jenny-Avital ER, Borczuk AC. Detection and significance of splenomegaly on chest radiographs of HIV-infected outpatients. *Clin Radiol* **1999**;54:34-7.
- Ledergerber B, von Overbeck J, Egger M, Lüthy R. The Swiss HIV cohort study: rationale, organization and selected baseline characteristics. *Soz Präventivmed* **1994**;39:387-94.
- Centers for Disease Control and Prevention. 1993 revised classification system for HIV infection and expanded surveillance case definition for AIDS among adolescents and adults. *MMWR Morb Mortal Wkly Rep* **1992**;41(RR-17):1-19.
- Dardenne AN. The spleen. In: Cosgrove D, Meire H, Dewbury K, eds. *Abdominal and general ultrasound*. Edinburgh: Churchill Livingstone, **1993**:351-65.
- Bundesamt für Gesundheit, Gebhardt M. AIDS und HIV in der Schweiz: epidemiologische situation ende 1996. Bern, Bundesamt für Gesundheit, Epidemiologie und Infektionskrankheiten, **1997**
- Grover SA, Barkun AN, Sackett DL. Does this patient have splenomegaly? *JAMA* **1993**;270:2218-21.
- Tamayo SG, Rickman LS, Mathews WC, et al. Examiner dependence on physical diagnostic tests for the detection of splenomegaly: a prospective study with multiple observers. *J Gen Intern Med* **1993**;8:69-75.
- Meijer K, Haagsma EB, Kok T, Schirm J, Smid WM, van der MJ. Natural history of hepatitis C in HIV-negative patients with congenital coagulation disorders. *J Hepatol* **1999**;31:400-6.
- Mellors JW, Munoz A, Giorgi JV, et al. Plasma viral load and CD4⁺ lymphocytes as prognostic markers of HIV-1 infection. *Ann Intern Med* **1997**;126:946-54.
- Egger M, Hirschel B, Francioli P, et al. Impact of new antiretroviral combination therapies in HIV infected patients in Switzerland: prospective multicentre study. *BMJ* **1997**;315:1194-9.