

Nephrol Dial Transplant (2011) 26: 562–565

doi: 10.1093/ndt/gfq444

Advance Access publication 23 July 2010

Renal vein obstruction and orthostatic proteinuria: a review

Marta B.M. Mazzoni^{1,*}, Lisa Kottanatu^{2,*}, Giacomo D. Simonetti³, Monica Ragazzi^{2,3}, Mario G. Bianchetti², Emilio F. Fossali¹ and Gregorio P. Milani²

¹Emergency Unit, Clinica Pediatrica De Marchi, Foundation IRCCS Ca' Granda Ospedale Maggiore Policlinico, Milan, Italy,

²Division of Pediatrics, Mendrisio and Bellinzona Hospitals, and University of Bern, Bern, Switzerland and ³Pediatric Nephrology, University Children's Hospital Bern and University of Bern, Bern, Switzerland

Correspondence and offprint requests to: Mario G. Bianchetti; E-mail: mario.bianchetti@me.com

*These authors contributed equally to the work.

Abstract

Objectives. The cause of orthostatic proteinuria is not clear but may often relate to obstruction of the left renal vein in the fork between the aorta and the superior mesenteric artery (= renal nutcracker). However, reports dealing with proteinuria only marginally refer to this possible cause of orthostatic proteinuria. We analysed the corresponding literature.

Results. Five reports addressed the frequency of renal nutcracker in 229 subjects with orthostatic proteinuria. Their age ranged between 5.2 and 17 years (female-to-male ratio: 0.96:1.00). Imaging studies demonstrated renal nutcracker in 156 (68%) subjects. Renal nutcracker was also demonstrated in 9 anecdotal reports for a total of 53 subjects with postural proteinuria. Very recently, 13 Italian subjects with orthostatic proteinuria associated with renal nutcracker were reassessed 6 years after the initial diagnosis: in nine subjects, both orthostatic proteinuria and renal nutcracker had disappeared; in three, both orthostatic proteinuria and renal nutcracker had persisted; and in one, orthostatic proteinuria had persisted unassociated with renal nutcracker.

Conclusions. These data provide substantial support for renal nutcracker as a common cause of orthostatic proteinuria.

Keywords: Doppler; proteinuria; renal vein abnormalities; ultrasonography

Background

Increased amounts of protein in the urine, either coupled with haematuria or isolated, may be an indicator of renal disease [1]. Orthostatic proteinuria is a non-pathological form of isolated proteinuria (Table 1), which is characterized by the presence of protein in urine samples collected in the upright position and its absence in samples collected

in the supine position [1]. It affects 2–5% of children or young adults with asymptomatic proteinuria, but a recent report suggested a very high incidence of $\geq 15\%$ in children between 6 and 18 years of age [2].

Three mechanisms have been traditionally implicated in isolated orthostatic proteinuria [1–3]. First, since in healthy individuals, proteinuria increases upon standing (although protein excretion remains normal), in some cases, orthostatic proteinuria might reflect an excessive physiologic response. Second, because there are sometimes subtle glomerular lesions in kidney biopsy specimens from individuals with orthostatic proteinuria, these lesions, in combination with a haemodynamic abnormality, might lead to orthostatic proteinuria. Third, orthostatic proteinuria might result from higher than normal release of norepinephrine and angiotensin II upon standing [1–3].

Nathan, 50 years ago [4], and especially Shintaku *et al.*, 20 years ago [5], first associated orthostatic proteinuria with a compression of the left renal vein in the fork between the superior mesenteric artery and the aorta. In this review, we address the literature published since 1991 with potential relevance in the role of left renal vein entrapment in the pathogenesis of isolated orthostatic proteinuria. We also address the literature that associates increased amounts of protein in the urine with uncommon causes of renal vein obstruction.

Orthostatic proteinuria associated with meso-aortic left renal vein entrapment

Five reports [6–10] specifically addressed the frequency of left renal vein obstruction (Figure 1) in a total of 229 subjects (Asian, $n = 205$; European, $n = 24$) with orthostatic proteinuria. Their ages ranged between 5.2 and 17 years (mean age: 12 years) with a female-to-male ratio of 0.96:1.00. Renal ultrasonic imaging and Doppler flow scanning demonstrated a compression of a pre-aortic left renal vein in the fork between the abdominal aorta and the proximal superior mesenteric artery, close to its

Table 1. Characteristic clinical and laboratory features in orthostatic proteinuria

Clinical characteristics	
• Age:	school age, adolescence, young adulthood
• Gender:	female \geq male
• Body habitus:	slender
• Posture ^a :	lordotic (= sway back)
• Physical examination:	normal (with emphasis on blood pressure measurement, evaluation for edema, rashes and, in childhood, growth status)
Laboratory investigations	
• Blood:	haemoglobin (or packed cell) (or total protein) normal
• Urine:	
– Office urine:	absent haematuria (by microscopy or reagent strip), positive reagent strip test for protein and pathologically increased total protein-to-creatinine ratio ^b
– First morning urine:	negative test for protein with the reagent strip and normal total protein-to-creatinine ratio ^b

^aOrthostatic proteinuria has also been termed in the past as lordotic albuminuria.

^bReference: <30 mg/mmol or <0.20 mg/mg.

origin, in 156 (68%) subjects (female-to-male ratio of 1.26:1.00) aged between 6.0 and 17 years (mean age: 13 years). In these reports, the diagnosis of left renal vein entrapment was made by ultrasound when the antero-posterior diameter at the hilar portion divided by that at the aorto-mesenteric portion (= diameter ratio) was >4.00 [10], >4.16 [6], >4.20 [8], or >5.00 [7]. The diagnosis was also made by Doppler examination, when the peak flow velocity at the aorto-mesenteric portion divided by that at the hilar portion (= flow velocity ratio) was >3.98 [6], >4.00 [8,10] or >5.00 [7].

In nine further anecdotal reports, renal ultrasonic imaging and Doppler flow scanning of the left renal vein demonstrated a normal anatomy and compression of the left renal vein in the fork between the abdominal aorta and the

proximal superior mesenteric artery close to its origin in 53 further subjects (Asian, $n = 22$; European, $n = 32$) with orthostatic proteinuria [11–19]. Their ages ranged between 5.2 and 21 years (median: 13 years) with a female-to-male ratio of 1.33:1.00.

In a large subset of the cases of orthostatic proteinuria, the diagnosis of renal vein entrapment was made by Doppler ultrasound and confirmed by multi-detector computed tomography ($n = 29$), magnetic resonance angiography ($n = 6$) or phlebography ($n = 8$).

Interestingly, the left kidney was documented as the source of proteinuria by ureteral catheterization in two Korean girls with orthostatic proteinuria and left renal vein entrapment [16]. A kidney biopsy, performed in three subjects with orthostatic proteinuria and left renal vein entrapment, failed to show significant abnormalities [15,17,19].

Orthostatic proteinuria remitted in an 18-year-old man and in a 14-year-old girl with meso-aortic left renal vein entrapment following percutaneous stent implantation [12] and surgical downward transposition of the renal vein respectively. Furthermore, in a Korean adolescent with meso-aortic left renal vein nutcracker phenomenon, orthostatic proteinuria disappeared on drug management with a converting enzyme inhibitor [15]. Very recently, 13 Italian subjects (nine female and four male subjects) with orthostatic proteinuria associated with the characteristic renal ultrasonic imaging (diameter ratio >4.00) and Doppler flow scanning (flow velocity ratio >4.00) features of meso-aortic left renal vein entrapment were reassessed 6 or more years after the initial diagnosis: in nine subjects both orthostatic proteinuria and left renal vein entrapment had disappeared, in three both orthostatic proteinuria and left renal vein entrapment had persisted, and in one orthostatic proteinuria had persisted unassociated with left renal vein entrapment [17].

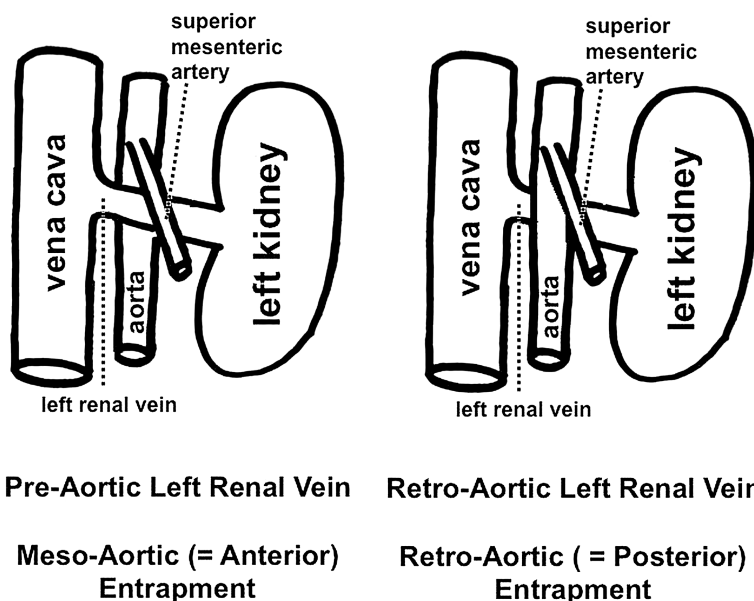


Fig. 1. Anatomy of the left renal vein. The left panel depicts the normal anatomy with a pre-aortic and the right panel an anomalous anatomy with a retro-aortic renal vein. The latter anomaly is seen in approximately 3% of individuals. More rarely (approximately 1% of individuals), both a pre-aortic and a retro-aortic left renal vein are seen: this anomaly, which is not depicted in the figure, is termed circum-aortic left renal vein. Obstruction of a normal, pre-aortic renal vein in the fork between the superior mesenteric artery and the aorta is termed meso-aortic (or anterior) left renal vein entrapment. Obstruction of a retro-aortic left renal vein between the aorta and the vertebral column is termed retro-aortic (or posterior) left renal vein entrapment.

Taken together, the literature reveals left renal vein entrapment in approximately two-thirds of the subjects with orthostatic proteinuria, demonstrates that, in subjects with orthostatic proteinuria and left renal vein entrapment, the left kidney is the source of proteinuria and indicates that orthostatic proteinuria tends to persist in subjects with persisting and to remit in those with remitting left renal vein entrapment. In conclusion available literature provides substantial support for entrapment of the left renal vein as the most common cause of orthostatic proteinuria (Table 2).

Proteinuria associated with other causes of renal vein entrapment

Orthostatic proteinuria was demonstrated in an 11-year-old Turkish boy with retro-aortic left renal vein entrapment [20]. In a group of 22 Turkish subjects aged between 24 and 78 years with retro-aortic left renal vein (Figure 1), the left renal vein diameters were narrower than in subjects with pre-aortic left renal vein: in two (9%) of these subjects, urinalysis revealed the presence of mild isolated proteinuria [21]. Unfortunately, the clinical significance of proteinuria was not further evaluated, and no split urine collection to establish the possible diagnosis of orthostatic proteinuria was performed.

In a 14-year-old female presenting with elevated nighttime urinary protein excretion without additional clinical symptoms, imaging studies revealed a large splenic cyst and secondary compression of the pre-aortic left renal vein. Removal of the cyst resulted in resolution of proteinuria [22].

In a 40-year-old female transplant donor with orthostatic proteinuria and a kink in the left renal vein, proteinuria resolved following left nephrectomy for transplantation [23].

Taken together, these observations indicate that, in very rare instances, increased amounts of protein in the urine are also associated with uncommon causes of renal vein obstruction.

Table 2. Link between orthostatic proteinuria and left renal vein entrapment: current pros and cons

Pros

- Renal ultrasound Doppler imaging discloses left renal vein entrapment in 156 of 229 subjects with orthostatic proteinuria (and in no more than 3–5% of healthy controls)
- Renal ultrasound Doppler imaging discloses left renal vein entrapment in 53 further patients with orthostatic proteinuria
- Both renal ultrasound Doppler imaging and more sophisticated diagnostic techniques disclose renal vein entrapment in 41 subjects with orthostatic proteinuria
- Left kidney documented as the source of proteinuria by ureteral catheterization in two subjects with orthostatic proteinuria and left renal vein entrapment
- Orthostatic proteinuria persists in subjects with persisting left renal vein entrapment ($n = 3$) and remits following repair ($n = 2$) or spontaneous remission ($n = 9$) of left renal vein entrapment

Cons

- Left renal vein entrapment disclosed in no more than 209 subjects with orthostatic proteinuria
- Imaging studies mostly (80%) performed in Asian subjects with orthostatic proteinuria
- Comparability and reproducibility of Doppler ultrasound imaging rather poor

Proteinuria and left renal vein entrapment in familial Mediterranean fever

Doppler ultrasonography and computed tomography revealed entrapment of the left renal vein also noted in an 11-year-old girl with persistent, non-orthostatic proteinuria, familial Mediterranean fever and a kidney biopsy without amyloid deposition [24].

Conclusions

Recent reports dealing with the management of proteinuria only marginally refer to renal vein obstruction as a cause of isolated orthostatic proteinuria. Our review indicates that entrapment of the left renal vein is the most important cause of orthostatic proteinuria. The major limitations of the assumption relate to the small number of cases in the literature, to the rather poor comparability and reproducibility of Doppler ultrasound imaging [25,26] and to the fact that most reports did not focus on the differences between subjects with and without renal vein entrapment with regard to body fat, blood pressure, renal function and protein excretion.

Orthostatic proteinuria (Table 1) is suspected in asymptomatic individuals, usually tall, thin and with an increased forward curve of the lower back presenting with isolated, mostly mild to moderate proteinuria that is discovered during routine examination [1–3]. A normal physical examination and an accurately collected first morning urine sample with normal proteinuria establish the diagnosis [1]. A Korean group recently recommended diagnostic imaging using multi-detector computed tomography in orthostatic proteinuria [7]. Considering that the cancer risk attributable to radiation from an abdominal computed tomography is non-negligible, especially in childhood, we strongly advise against the use of computed tomography in this non-pathological condition [27]. At our institutions, we advise either no imaging studies or renal ultrasonic imaging with Doppler flow scanning in asymptomatic individuals with isolated postural proteinuria.

In anecdotal reports, orthostatic proteinuria remitted following repair of renal vein entrapment or on drug management with a converting enzyme inhibitor. However, considering the almost always benign prognosis and the mostly self-remittent course, we do not advise any treatment in this condition [28].

Conflict of interest statement. None declared.

References

1. Mahan JD, Turman MA, Mentser MI. Evaluation of hematuria, proteinuria, and hypertension in adolescents. *Pediatr Clin North Am* 1997; 44: 1573–1589
2. Brandt JR, Jacobs A, Raissy HH *et al.* Orthostatic proteinuria and the spectrum of diurnal variability of urinary protein excretion in healthy children. *Pediatr Nephrol* 2010; 25: 1131–1137
3. Milani GP, Bianchetti MG, Bozzani S *et al.* Body mass index modulates postural proteinuria. *Int Urol Nephrol* 2010; 42: 513–515

4. Nathan H. Observations on aberrant renal arteries curving around and compressing the renal vein; possible relationship to orthostatic proteinuria and to orthostatic hypertension. *Circulation* 1958; 18: 1131–1134
5. Shintaku N, Takahashi Y, Akaishi K *et al.* Entrapment of left renal vein in children with orthostatic proteinuria. *Pediatr Nephrol* 1990; 4: 324–327
6. Cho BS, Choi YM, Kang HH *et al.* Diagnosis of nut-cracker phenomenon using renal Doppler ultrasound in orthostatic proteinuria. *Nephrol Dial Transplant* 2001; 16: 1620–1625
7. Cho BS, Suh JS, Hahn WH *et al.* Multidetector computed tomography findings and correlations with proteinuria in nutcracker syndrome. *Pediatr Nephrol* 2010; 25: 469–475
8. Park SJ, Lim JW, Cho BS *et al.* Nutcracker syndrome in children with orthostatic proteinuria: diagnosis on the basis of Doppler sonography. *J Ultrasound Med* 2002; 21: 39–45
9. Park YH, Choi JY, Chung HS *et al.* Hematuria and proteinuria in a mass school urine screening test. *Pediatr Nephrol* 2005; 20: 1126–1130
10. Ragazzi M, Milani G, Edefonti A *et al.* Left renal vein entrapment: a frequent feature in children with postural proteinuria. *Pediatr Nephrol* 2008; 23: 1837–1839
11. Barbey F, Venetz JP, Calderari B *et al.* Protéinurie orthostatique et phénomène de compression de la veine rénale gauche (nutcracker syndrome). *Presse Méd* 2003; 31: 883–885
12. Basile A, Tsetis D, Calcara G *et al.* Percutaneous nitinol stent implantation in the treatment of nutcracker syndrome in young adults. *J Vasc Interv Radiol* 2007; 18: 1042–1046
13. Ekim M, Ozçakar ZB, Fitoz S *et al.* The “nutcracker phenomenon” with orthostatic proteinuria: case reports. *Clin Nephrol* 2006; 65: 280–283
14. Fitoz S, Ekim M, Ozçakar ZB *et al.* Nutcracker syndrome in children: the role of upright position examination and superior mesenteric artery angle measurement in the diagnosis. *J Ultrasound Med* 2007; 26: 573–580
15. Ha TS, Lee EJ. ACE inhibition can improve orthostatic proteinuria associated with nutcracker syndrome. *Pediatr Nephrol* 2006; 21: 1765–1768
16. Lee SJ, You ES, Lee JE *et al.* Left renal vein entrapment syndrome in two girls with orthostatic proteinuria. *Pediatr Nephrol* 1997; 11: 218–220
17. Milani GP, Mazzoni MB, Burdick L *et al.* Postural proteinuria associated with left renal vein entrapment: a follow-up evaluation. *Am J Kidney Dis* 2010; 55: e29–e31
18. Takahashi Y, Sano A, Matsuo M. An ultrasonographic classification for diverse clinical symptoms of pediatric nutcracker phenomenon. *Clin Nephrol* 2005; 64: 47–54
19. Wang L, Yi L, Yang L *et al.* Diagnosis and surgical treatment of nutcracker syndrome: a single-center experience. *Urology* 2009; 73: 871–876
20. Ekim M, Bakkaloglu SA, Tumer N *et al.* Orthostatic proteinuria as a result of venous compression (nutcracker phenomenon)—a hypothesis testable with modern imaging techniques. *Nephrol Dial Transplant* 1999; 14: 826–827
21. Yagci B, Tavasli B, Karabulut N *et al.* Clinical significance and renal haemodynamics of incidentally detected retroaortic left renal vein: assessment with venous Doppler sonography. *Br J Radiol* 2008; 81: 187–191
22. Faizan MK, Finn LS, Paladin AM *et al.* A 14-year-old girl with recumbent proteinuria. *Pediatr Nephrol* 2002; 17: 379–381
23. Devarajan P. Mechanisms of orthostatic proteinuria: lessons from a transplant donor. *J Am Soc Nephrol* 1992; 4: 36–39
24. Ozcan A, Gonul II, Sakallioglu O *et al.* Nutcracker syndrome in a child with familial Mediterranean fever (FMF) disease: renal ultrastructural features. *Int Urol Nephrol* 2009; 41: 1047–1053
25. Mikkonen RH, Kreula JM, Virkkunen PJ. Reproducibility of Doppler ultrasound measurements. *Acta Radiol* 1996; 37: 545–550
26. Mikkonen RH, Kreula JM, Virkkunen PJ. Reliability of Doppler ultrasound in follow-up studies. *Acta Radiol* 1998; 39: 193–199
27. Brenner D, Elliston C, Hall E *et al.* Estimated risks of radiation-induced fatal cancer from pediatric CT. *AJR Am J Roentgenol* 2001; 176: 289–296
28. Milani G, Fossali EF, Bianchetti MG. Re: Wang *et al.*: Diagnosis and surgical treatment of nutcracker syndrome: a single-center experience (Urology 2009; 73: 871–876). *Urology* 2009; 74: 476–477

Received for publication: 12.5.10; Accepted in revised form: 2.7.10

Nephrol Dial Transplant (2011) 26: 565–572

doi: 10.1093/ndt/gfq433

Advance Access publication 20 July 2010

Does urinary stone composition and morphology help for prediction of primary hyperparathyroidism?

Hassan Bouzidi^{1,2}, David de Brauwere² and Michel Daudon²

¹Laboratoire de Biochimie, Hôpital Universitaire Tahar Sfar, Mahdia, Tunisia and ²Laboratoire de biochimie A, Hôpital Necker–Enfants Malades, APHP, Paris, France

Correspondence and offprint requests to: Michel Daudon; E-mail: michel.daudon@nck.aphp.fr

Abstract

Background. Primary hyperparathyroidism (HPT) is a common cause of urolithiasis. Only a few data are available on stone composition and morphology in HPT patients.

Methods. We compared the composition and morphology of stones from 264 HPT patients (143 males and 121 females) and 24 567 non-HPT stone formers (16 918 males and 7649 females) including a subgroup of 1356 patients