

Nephrol Dial Transplant (2006) 21: 2013–2016

doi:10.1093/ndt/gfl284

Advance Access publication 30 May 2006



Interesting Case

Extensive calcifications induced by hyperphosphataemia caused by phosphate-based enema in a patient after kidney transplantation

Jens Eckstein¹, Spasenija Savic², Thomas Eugster³, Hans Pargger⁴, Lorenz Gürke³, Martina Pechula¹, Jürg Steiger¹ and Michael Mayr¹

¹Division of Transplantation Immunology and Nephrology, ²Institute for Pathology, ³Division of Vascular and Transplantation Surgery and ⁴Division of Operative Critical Care, Department of Anesthesia, University Hospital Basel, Basel, Switzerland

Keywords: dystrophic calcification; hyperphosphataemia; kidney transplantation; phosphate-based enema; phosphate intoxication; visceral calcifications

Introduction

The use of phosphate-based enemas as a laxative is still standard practice in clinical medicine. Absorption of phosphate with consecutive hyperphosphataemia and hypocalcaemia is a serious adverse event which is especially dangerous in patients with renal insufficiency and impaired bowel movement. Despite several reports including cases of death, the seriousness of this situation appears to be underestimated in clinical practice [1,2].

We report a case of severe hyperphosphataemia after kidney transplantation induced by phosphate-containing enemas resulting in fatal calcifications.

Case report

A 64-year-old woman with end-stage renal failure due to analgesic nephropathy had been on chronic peritoneal dialysis for 18 months. Several years ago, gastrectomy, oesophagojejunostomy and splenectomy were performed because of a perforated gastric ulcer. Secondary hyperparathyroidism was treated by calcium-containing phosphate binders and calcitriol. During the course of peritoneal dialysis, intact parathyroid hormone levels were decreased from 804 pg/ml to 82 pg/ml. The calcium–phosphate molar product was never higher than 56.5 mg²/dl² (4.5 mmol²/l²).

Besides dialysis with disturbed calcium phosphate balance, hypertension and a history of smoking existed as cardiovascular risk factors. However, the patient's medical history was free from ischaemic vascular events. Dobutamine stress echocardiography revealed no cardiac ischaemia, and duplex sonography showed no stenosis of the pelvic vessels. The patient received a kidney graft from a marginal donor with a history of hypertension and a prolonged warm ischaemia time. The renal artery of the graft was arteriosclerotic. The operative procedure was uneventful and no severe or prolonged episode of hypotension occurred. However, colouration of the graft from livid to rosy was decelerated. The index biopsy revealed signs of moderate arteriolar hyalinosis and interstitial fibrosis. The induction immunosuppression consisted of basiliximab (20 mg i.v. on days 0 and 4) combined with methylprednisolone (1000, 500 and 250 mg on days 0, 1 and 2–4, respectively), ciclosporin from day 4 on (dosage adapted to serum drug levels from 250 to 350 µg/l), mycophenolate mofetil (1000 mg orally twice a day), and prednisone (125 mg/day from day 5 with tapering to 20 mg). Due to primary non-function, haemodialysis was started on day 1. Duplex ultrasound showed a normal arterial flow and an accelerated flow of the renal vein in the area of crossing the renal artery. On the same day, a phosphate-based enema was administered to stimulate bowel activity. During the following night, severe hyperphosphataemia of 17.1 mg/dl (5.55 mmol/l) developed, with a concomitant fall in serum calcium from 9.96 mg/dl to 8.63 mg/dl (2.48–2.15 mmol/l) and a calcium–phosphate molar product of 147 mg²/dl² (12 mmol²/l²). The episode of hyperphosphataemia was accompanied by hypotension (blood pressure 93/55 mmHg) and liver enzymes increased dramatically: aspartate aminotransferase 6666 U/l, alanine aminotransferase 2096 U/l and lactate dehydrogenase of 6804 U/l (Figure 1). Duplex sonography of the kidney showed the same pattern as the day before. Computed tomography of the

Correspondence and offprint requests to: Michael Mayr, MD, Division of Transplantation Immunology and Nephrology, University Hospital Basel, Petersgraben 4, 4031 Basel, Switzerland. Email: mmayr@uhbs.ch

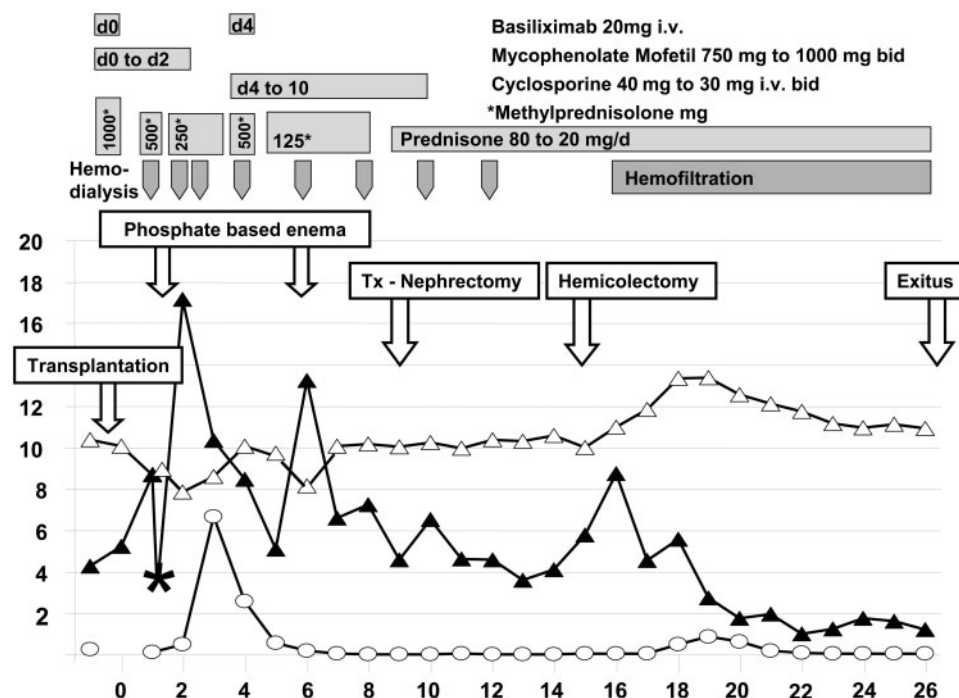


Fig. 1. Course of disease, x-axis: days after transplantation, y-axis: phosphate mg/dl (black triangle; asterisk: phosphate after first dialysis session), calcium mg/dl (open triangle), aspartate aminotransferase U/l \times 1000 (open circle). NOTE: To convert serum phosphate in milligram per decilitre to millimole per litre, multiply by 0.323; serum calcium in milligram per decilitre to millimole per litre, multiply by 0.250.

abdomen revealed extensive lesions in the liver compatible with ischaemic or drug-induced tissue damage. Further, generalized atherosclerosis, including the mesenteric vessels, was seen. Mycophenolate mofetil was stopped, as a potential causative agent of drug-induced liver failure. Immediately, an additional haemodialysis was performed to remove phosphate. After dialysis, phosphate levels decreased and remained in a range from 3.46 to 8.48 mg/dl (1.12–2.74 mmol/l). The liver enzymes returned to normal levels within 7 days. Nevertheless, the patient's condition continued to deteriorate and she became delirious. The abdomen remained distended without any signs of bowel activity. During the weekend (on day 6), unaware of the severe hyperphosphataemia on day 2, two more phosphate-containing enemas were instilled. Again, an increase of the serum phosphate to 13.25 mg/dl (4.28 mmol/l) and a decrease in serum calcium from 9.4 mg/dl to 8.0 mg/dl (2.34–1.99 mmol/l) with a calcium–phosphate molar product of $106 \text{ mg}^2/\text{dl}^2$ ($8.5 \text{ mmol}^2/\text{l}^2$) was observed. The general condition of the patient worsened and the kidney graft remained non-functioning. On day 9, explorative surgery revealed a dark blue kidney and a transplant nephrectomy was performed. Histologically, thrombosis of the renal vein and a partial thrombosis of the artery were found. The completely necrotic organ showed massive nephrocalcinosis. After graft nephrectomy, the patient's condition improved only slightly. However, on day 15 the patient suffered from feculent vomiting. Laparotomy revealed a necrotic colon and pancreas.

Hemicolecotomy, cholecystectomy and peripancreatic necrosectomy were performed. Thirteen days later, despite repeated second-look operations with debridements and broad-spectrum antibiotics, the patient developed septic shock and died of multiple organ failure.

The histology of the colon, rectum and gall bladder revealed severe calcifications of small and medium-sized arteries and veins and regions of superficial and transmural necrosis with calcifications. Intimal proliferation, endovascular fibrosis and thrombosis of the vessels were not found. In the liver, an infarct of 8 cm with parenchymal calcifications and multiple haemorrhagic infarcts (up to $4 \times 4 \times 8 \text{ cm}$) were present. The peripheral and central veins within the infarcted areas revealed subacute thromboses. The pancreas presented a pattern of subacute pancreatitis and subacute, partly organized thromboses of small peripancreatic veins. In conclusion, severe dystrophic calcifications in liver, colon, rectum, gall bladder and the kidney graft in a patient with pre-existing generalized athero- and arteriosclerosis were diagnosed. Brain, lung and skin showed no calcifications at all.

Discussion

Since the clinical trial of Vanner *et al.* [3] in 1990, sodium phosphate preparations have been widely prescribed as a safe and well-tolerated colonic cleansing agent. They are, however, not recommended for

patients with impaired renal function. In cases of renal insufficiency, the development of severe, life-threatening hyperphosphataemia with concomitant hypocalcaemia has been described. This observation is documented in several case series. Fass *et al.* [1] summarized 28 cases. The patients were between 4 months and 81 years old. All of them received a phosphate-based cathartic, most of them rectally. The administered doses varied between 65 and 690 ml (mostly Fleet Phospho-Soda containing 15.4 g elemental phosphate per 120 ml). The observed increase in serum phosphate varied between 4.3 mg/dl (1.38 mmol/l) and 67 mg/dl (21.6 mmol/l). Pre-disposing factors for hyperphosphataemia in adults were chronic constipation, ileus, excessive enema use and renal insufficiency. In five cases the outcome was poor, including brain damage, cardiac arrest, coma and death in two cases [1]. The reported mortality rate in cases of severe hyperphosphataemia due to phosphate administration (rectally and orally) is about 33% (four of 12 patients) [4]. Recently, Markowitz *et al.* [5] reported 21 cases of acute renal failure following oral sodium phosphate bowel cleansing. The most distinctive finding in all cases was abundant calcium phosphate deposits in distal tubules and collecting ducts. The mean baseline creatinine was 1.0 mg/dl [range 0.6–1.7 mg/dl (53–150 μ mol/l)]. The renal outcome was poor, all patients developed chronic renal insufficiency with a mean serum creatinine of 2.4 mg/dl [range 1.3–3.4 mg/dl (115–300 μ mol/l)] and four of them required chronic haemodialysis.

Under normal conditions, up to 20% of the phosphate in enemas is resorbed [6]. On day 1 after transplantation, our patient received Practo-Clyss[®] 120 ml containing 2.9 g disodium hydrogenphosphate (20.3 mmol) and 14.8 g sodium dihydrogenphosphate (122.8 mmol). The volume of phosphate distribution is not fixed and depends greatly on cellular and bone uptake. Therefore, only a simple calculation is needed to show that a moderate increase in phosphate absorption may be sufficient to cause severe hyperphosphataemia, especially if the renal excretion of phosphate is disturbed. In our patient, assuming an extracellular volume of 12 litre, only about 53 mmol of phosphate had to be absorbed to increase the serum phosphate from 3.3 mg/dl (1.06 mmol/l) to 17.1 mg/dl (5.55 mmol/l) as observed on day 1.

Hebert *et al.* [7] showed that the administered phosphate lowers serum calcium by physiochemical precipitation of CaHPO_4 as its solubility product is exceeded. In three of their patients, even calcium deposits could be radiologically explored in the vein in which phosphate was infused [7]. Otherwise, as shown already in 1932 by Albright *et al.* [8], phosphate administered to hypercalcaemic patients might result in soft tissue calcification. Clinically, it is very important at which site the CaHPO_4 precipitation occurs. As discussed by Floege *et al.* [9], the different pathogenetic pathways of vascular, valvular, organ and soft tissue calcifications in uraemic patients are complex. Besides passive precipitation, due to an

excessive calcium phosphate product, active cellular processes, systemic or local deficiency of inhibitory factors to prevent precipitation and the local milieu may be important factors in the different pathogenesis of calcifications [9]. Haldimann *et al.* [10] studied the effect of Practo-Clyss[®] 120 ml in two volunteers with renal insufficiency. Similar to our patient, one of them was a patient with non-functioning graft and bowel motility 2 days after renal transplantation [10]. As with our case, they saw an increase of serum phosphate with a decrease of serum calcium, strongly suggesting CaHPO_4 precipitation. However, in our patient, the incautious administration resulted in a catastrophe. The hyperphosphataemia was accompanied by hypotension and, given the pre-existing mesenteric athero- and arteriolosclerosis, led to ischaemia in visceral organs. Subsequently, phosphate overload and a high serum calcium phosphate product caused severe dystrophic calcifications. Especially, the sharp and dramatic increase in liver enzymes and the liver infarcts with calcifications may have been caused by hypoperfusion with subsequent dystrophic calcifications. The same mechanism of hypoperfusion and ischaemia may explain the extended calcifications in the pre-damaged graft of a marginal donor.

This is, to our knowledge, the first published case proven by autopsy, in which enema-induced hyperphosphataemia led to disseminated dystrophic calcifications in virtually all visceral organs. Despite two haemodialysis sessions within 12 h to eliminate the phosphate, the process of calcification could not be reversed.

To know more about the use of phosphate-based bowel preps in the post-operative period of kidney transplantation, we performed a survey in 70 centres in the Eurotransplant area and in Swisstransplant. The response rate was 50% (35 centres). In 16 centres (46%), phosphate-containing enemas are never used. In 8 centres (23%), phosphate-containing preps are not used in the immediate post-transplantation period. Seven of them restrict the use of phosphate-containing preps to a functioning graft, whereas the proposed cut-off defining a functioning graft (expressed by serum creatinine or creatinine clearance) varies widely [serum creatinine less than 300 μ mol/l to 150 μ mol/l (3.4–1.6 mg/dl); creatinine clearance more than 20–40 ml/min]. In 11 centres (31%), phosphate-based enemas are prescribed in the post-operative period, of which 10 centres (28%) use it without restriction for functioning grafts and one centre limits its use to normal serum phosphate levels. In summary, nearly one-third of the centres which replied, use phosphate-based preps without restriction to functioning graft. The following conclusions can be drawn. First, the potential seriousness of the adverse effects of phosphate-based preps may still be underestimated, especially in the early post-operative period in kidney transplantation. Second, there exists no clear creatinine cut-off which permits the safe application of phosphate-based preps. It should be noted that in the afore-mentioned study of Markowitz *et al.* [5] most of

the patients had a baseline serum creatinine within the normal range.

In conclusion, it is hazardous to administer phosphate-based enemas in patients with renal insufficiency, especially in patients with a risk of increased retention due to atonic bowel or faecal impaction. In the early post-operative period of kidney transplantation, the administration of phosphate-based enemas is contraindicated.

Acknowledgements. The authors thank Michael J. Mihatsch (Institute for Pathology) for the helpful discussion.

Conflict of interest statement. None declared.

References

1. Fass R, Do S, Hixson LJ. Fatal hyperphosphatemia following Fleet Phospho-Soda in a patient with colonic ileus. *Am J Gastroenterol* 1993; 88: 929–932
2. Korzets A, Dicker D, Chaimoff C, Zevin D. Life-threatening hyperphosphatemia and hypocalcemic tetany following the use of fleet enemas. *J Am Geriatr Soc* 1992; 40: 620–621
3. Vanner SJ, MacDonald PH, Paterson WG *et al.* A randomized prospective trial comparing oral sodium phosphate with standard polyethylene glycol-based lavage solution (Golytely) in the preparation of patients for colonoscopy. *Am J Gastroenterol* 1990; 85: 422–427
4. Fine A, Patterson J. Severe hyperphosphatemia following phosphate administration for bowel preparation in patients with renal failure: two cases and a review of the literature. *Am J Kidney Dis* 1997; 29: 103–105
5. Markowitz GS, Stokes MB, Radhakrishnan J, D'Agati VD. Acute phosphate nephropathy following oral sodium phosphate bowel purgative: an underrecognized cause of chronic renal failure. *J Am Soc Nephrol* 2005; 16: 3389–3396
6. Martindale the complete drug reference. Pharmaceutical press, London, UK, 2004.
7. Hebert LA, Lemann J, Jr, Petersen JR, Lennon EJ. Studies of the mechanism by which phosphate infusion lowers serum calcium concentration. *J Clin Invest* 1966; 45: 1886–1894
8. Albright F, Bauer W, Claflin D, Cockrill JR. Studies in parathyroid physiology. III. The effect of phosphate ingestion in clinical hyperparathyroidism. *J Clin Invest* 1932; 11: 411
9. Floege J. When man turns to stone: extraosseous calcification in uremic patients. *Kidney Int* 2004; 65: 2447–2462
10. Haldimann B, Vogt K. Hyperphosphatemia and tetany following phosphate enema. *Schweiz Med Wochenschr* 1983; 113: 1231–1233

Received for publication: 2.12.04

Accepted in revised form: 25.4.06