

The Journal of Laryngology and Otology
May 1998, Vol. **112**, pp. 469–471

Clinical Records

Multiple myeloma presenting with external ear canal mass

D. QUINODOZ, M.D.*, P. DULGUEROV, M.D.*, A.-M. KURT, M.D.†, D. RUEFENACHT, M.D.‡, R. ABELE, M.D.**
A. S. ALLAL, M.D.‡ P. MONTANDON, M.D.*

Abstract

The manifestations of multiple myeloma are protean and related to bony osteolytic lesions, and to medullar and renal insufficiency. We report a patient who presented with otalgia as the inaugural symptom of multiple myeloma. Local irradiation combined with systemic chemotherapy led to the disappearance of the temporal bone mass and the accompanying symptoms. To date, 24 months after the diagnosis, the patient is still in remission.

The literature on otological involvement in multiple myeloma is reviewed. Symptoms are non-specific and include hearing loss, tinnitus, dizziness, facial paralysis, and otalgia. The diagnosis of multiple myeloma should be considered in the presence of a temporal bone mass.

Key words: Ear; Multiple myeloma; Pain; Drug therapy; Radiotherapy

Introduction

Multiple myeloma (MM) accounts for 10 per cent of haematological malignancies and one per cent of all cancer-related deaths (Alexian and Dimopoulos, 1994; Bataille and Harsousseau, 1997). MM is a neoplastic proliferation of monoclonal plasma cells within the haematopoietic bone marrow. Symptoms are related to these osteolytic lesions (skeletal pain, pathological fractures, hypercalcaemia), to the replacement of bone marrow by the neoplastic process (immunosuppression resulting in increased bacterial infections, anaemia, bleeding), and to renal insufficiency.

The diagnosis of MM requires at least two of the following criteria (Barlogie, 1995; Selby and Gore, 1995): 1) serum or urinary monoclonal immunoglobulin which can be composed of the entire immunoglobulin protein, of complete light chains, or various fragments; 2) bone-marrow infiltration by large and immature plasma cells; 3) osteolytic lesions. Several staging systems have been described (Barlogie, 1995; Selby and Gore, 1995).

Since MM is a systemic illness, involvement of the temporal bone is possible. Nevertheless, otological symptoms in MM have rarely been described. A case is reported in which the presenting signs of MM were otological. The literature on temporal bone involvement in MM is reviewed.

Case report

A 70-year-old male, without previous medical history, consulted because of progressively worsening right earache of six months duration. He did not complain of hearing loss, tinnitus, or dizziness.

Clinical examination revealed a right external ear canal partially obstructed by a subcutaneous, smooth mass, located on the posterior bony-cartilagenous junction. The tympanic membrane was intact. Tuning fork testing was normal and symmetrical. A right peripheral facial paresis was present.

A temporal bone computed tomography (CT) scan (Figure 1a) showed an osteolytic lesion, 2.5 cm in diameter, enhanced by contrast material, and replacing the right mastoid. The mass eroded the posterior canal wall and protruded in the posterior fossa. A second osteolytic lesion was found at the level of the right occipital condyle. These lesions exhibited homogeneous enhancement with gadolinium on magnetic resonance imaging (MRI) (Figure 1b).

A biopsy of the external auditory canal mass was performed under local anaesthesia. The pathology showed a proliferation of atypical plasma cells compatible with a multiple myeloma (Figure 2) and immunohistochemical staining was positive for the Kappa light chains and negative for the Lambda light chains (not shown).

Further investigations, including a skull and skeletal X-rays, a protein electrophoresis, an immunoelectrophoresis and a bone marrow biopsy, permitted the diagnosis of IgG-Kappa multiple myeloma, without renal failure, anaemia, or hypercalcaemia. The disease was thus staged as IIIa.

The patient was treated with Alkeran and Prednisone, and local radiation therapy delivered through two lateral weighted fields for a total dose of 30 Gy (6 MeV photons; 10 fractions of 3 Gy).

Three months after this treatment, the patient was greatly improved. The otalgia and facial paralysis resolved. The external auditory canal lesion regressed completely.

From the Departments of Otolaryngology – Head and Neck Surgery*, Pathology†, Radiology‡, and Medicine**, University Canton Hospital, 24 Rue Micheli-du-Crest, 1211 Geneva 14, Switzerland.

Accepted for publication: 4 March 1998.

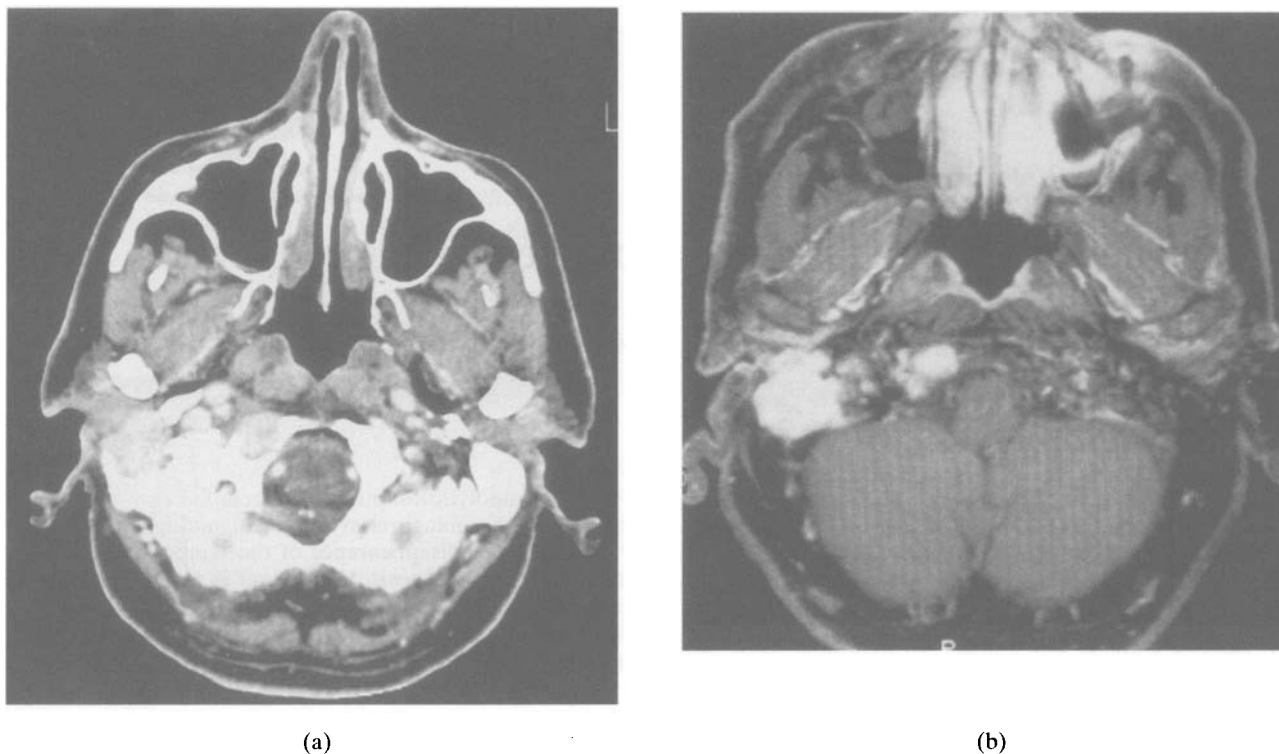


FIG. 1

Initial axial CT and MRI scans. The CT scan, after i.v. application of contrast material, is filmed with soft tissue windows (Figure 1a). The homogenous enhancing temporal bone mass presents as an osteolytic lesion of the right mastoid and sino-dural angle plate without signs of periosteal reaction or invasion of the sigmoid sinus. A second lesion with similar radiological characteristics is present at the base of skull near the foramen magnum. The T1-weighted MRI image with gadolinium-DPTA (Figure 1b) also exhibits a pattern of homogeneous enhancement after contrast application.

To date, 24 months after the diagnosis, the patient does not present any local or general complaints and has resumed his normal activities.

Discussion

A variety of tumours, either primary or secondary, can involve the temporal bone (Hyams, 1987; Abemayor *et al.*, 1988; Kemink *et al.*, 1993). Symptoms are not specific and tend to vary with the location of the disease process and the invaded anatomical structures (Schuknecht, 1993). While physical examination, audiological and vestibular investigations are warranted, they are rarely diagnostic and radiological studies such as thin section CT or MRI scans

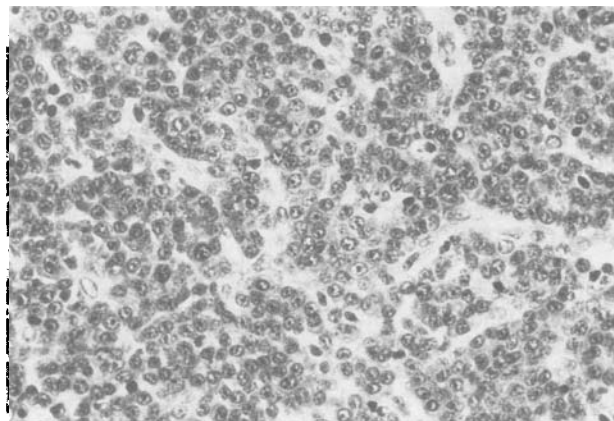


FIG. 2

The lesion is composed of a dense cellular infiltrate, mainly composed of plasma cells arranged in cords, separated by a fibro-vascular stroma. (H & E; $\times 400$).

are required to determine the involved structures and help in selecting the surgical approach for excision or biopsy (Jackler and Parker, 1992).

Involvement of the temporal bone has been reported to occur in the terminal stage of MM. However, at this stage, otological symptoms are overshadowed by the manifestations of diffuse skeletal disease (Schuknecht, 1993).

In our case, the presenting signs of MM were related to an involvement of the temporal bone. The mastoid mass resulted in otalgia and a facial palsy without any other otological or systemic symptoms.

In the literature, only a few individual case reports describe a symptomatic MM temporal bone involvement (Table I). In 1979, Lavine *et al.* presented a patient already diagnosed with MM, who complained of dizziness, hearing loss and tinnitus. Three other cases with otological symptoms in patients with diffuse signs of MM have been published (Shone, 1985; Keay, 1988; Chevalier *et al.*, 1992).

Marks and Brookes in 1985 were the first to describe a patient with left deafness, tinnitus, facial palsy, and intermittent vertigo who had an isolated mastoid lesion. Biopsy of the external auditory canal lesion led to the diagnosis of MM. Funakubo and Kikuchi (1994) describe a similar case. None of these studies included histopathological sections of the temporal bone.

Li *et al.* (1994) studied the temporal bone histopathology in eight patients who had died from advanced, disseminated MM. Among these eight patients only two had otological symptoms, while 14 out of 16 temporal bones (87 per cent) exhibited MM lesions in various locations. The structures involved were exclusively bony, with sparing of mucosa, skin and other key structures such as the facial nerve or the carotid artery.

TABLE I
CASES OF TEMPORAL BONE INVOLVEMENT IN MULTIPLE MYELOMA REPORTED IN THE LITERATURE

	Age	Sex	Hearing loss	Deafness	Tinnitus	Vertigo	Facial palsy	Otalgia	Systemic symptoms
Lavine (1979)	55	F	+		+	+		+	+
Marks and Brookes (1985)	71	M		+	+	+			
Shone (1985)	55	F					+		+
Keay (1985)	58	F	+						+
Chevalier <i>et al.</i> (1992)	62	F	+			+			+
Funakubo and Kikuchi (1994)	71	M	+		+		+		
Present case	70	M					+	+	

The temporal bone is, therefore, often involved in advanced cases of MM. The clinical expression of this involvement is, however, unusual (Table I) and only exceptionally does MM present with otological symptoms, as in our patient.

References

- Abemayor, E., Canalis, R. F., Greenberg, P., Wortham, D. G., Rowland, J. P., Sun, N. C. J. (1988) Plasma cell tumors of the head and neck. *Journal of Otolaryngology* **17**: 376–381.
- Alexian, R., Dimopoulos, M. (1994) The treatment of multiple myeloma. *New England Journal of Medicine* **330**: 484–489.
- Barlogie, B. (1995) Plasma cell myeloma. In *Williams Hematology*. 5th Edition. (Beutler, E., Lichtman, M. A., Coller, B. S., Kipps, T. J., eds.), McGraw-Hill, New York, pp 1109–1123.
- Bataille, R., Harousseau, J. L. (1997) Multiple myeloma. *New England Journal of Medicine* **336**: 1657–1664.
- Chevalier, X., Wrona, N. N., Larget-Piet, B. (1992) Vestibular syndrome in multiple myeloma: role of magnetic resonance imaging. *Clinical Rheumatology* **11**: 405–407.
- Funakubo, T., Kikuchi, A. (1994) A case of myeloma with facial palsy. *Acta Otolaryngologica (Suppl 511)*: 200–203.
- Hyams, V. F. (1987) Pathology of tumors of the ear. In *Comprehensive Management of Head and Neck Tumor*. (Thawley, S. E., Panje, W. R., eds.), W. B. Saunders, Philadelphia, pp 168–193.
- Jackler, R. K., Parker, D. A. (1992) Radiographic differential diagnosis of petrous apex lesions. *American Journal of Otolaryngology* **13**: 561–574.
- Keay, D. (1988) Total bilateral hearing loss as a complication of myeloma. *Journal of Laryngology and Otology* **102**: 357–358.
- Kemink, J. L., Graham, M. D., Gebarski, S. S. (1993) Surgery of the temporal bone neoplasms. In *Otolaryngology – Head and Neck Surgery*. 2nd Edition. (Cummings, C. W., Fredrickson, J. M., Harker, L. A., Krause, C. J., Schuller, D. E., eds.), Mosby Year Book, Inc., St Louis, pp 3353–3370.
- Lavine, R. F., Mattucci, K. F., Merton, C. W. (1979) Multiple myeloma of the temporal bone. *Ear Nose and Throat Journal* **58**: 210–213.
- Li, W., Schachern, P. A., Morizono, T., Paparella, M. M. (1994) The temporal bone in multiple myeloma. *Laryngoscope* **104**: 675–680.
- Marks, P. V., Brookes, G. B. (1985) Myelomatosis presenting as an isolated lesion in the mastoid. *Journal of Laryngology and Otology* **99**: 903–906.
- Schuknecht, H. F. (1993) *Pathology of the Ear*. 2nd Edition. Harvard University Press, Cambridge, p 498.
- Selby, P., Gore, M. (1995) Myeloma and other plasma cell malignancies. In *Oxford Textbook of Oncology*. (Peckham, M., Pinedo, H. M., Veronesi, U., eds.), Oxford University Press, Oxford, pp 1852–1878.
- Shone, G. R. (1985) Facial palsy due to myeloma of the temporal bone. *Journal of Laryngology and Otology* **99**: 907–908.

Address for correspondence:

Pavel Dulguerov, M.D.,
Department of Otolaryngology, Head and Neck Surgery,
University Canton Hospital,
24 Rue Micheli-du-Crest,
1211 Geneva 14,
Switzerland.

Fax: (4122) 372 82 40

e-mail: Pavel.Dulguerov@hcuge.ch